Epidural Lysis of Adhesions and Percutaneous Neuroplasty

Dr. M. Mokaram

Fellowship of Pain medicine

Quandary following a primary surgery

- As to whether **repeat surgery** should be attempted or another **alternative technique** should be tried.
- This is the **exact problem** that the epidural adhesiolysis procedure was designed to address
- **Failed back surgery** or **postlaminectomy syndrome** led to the development of the epidural adhesiolysis procedure.

- **Freeing up nerves and breaking down scar** formation
- Delivering site-specific **corticosteroids** and **LA**
- Reducing edema with the use of

  hyaluronidase

  hypertonic saline.

Epidural adhisionolysis

- ***Reduction in*** **pain** and **neurologic symptoms**
- **without long recovery**
- **Prevents** the need for surgical intervention (OFTEN).
- Evidence rating of strong correlating to a **1B or 1C** evidence level for post–lumbar surgery syndrome in the most recent American Society of Interventional Pain Physicians evidence-based guidelines.

Pathophysiology of epidural fibrosis (scar tissue) as a cause of low back pain with radiculopathy

- ***Sciatica*** could only be produced by

  stimulation of a **swollen, stretched, restricted** (i.e., scarred) or

  compressed nerve root

Back pain

the most common **tissue** of origin was

the outer layer of the annulus fibrosus

the **posterior longitudinal ligament**.

- Stimulation for pain generation of the **facet joint** capsule rarely generated low back pain, and facet synovium and cartilage surfaces of the facet or muscles were never **tender**

Possible etiologies of epidural fibrosis

- **Surgical trauma**
- **Annular tearing**
- **Infection**
- **Hematoma**
- **Intrathecal contrast material**

These etiologies have been well documented

- **Postoperative hematoma** →Invasion of fibrous connective tissue into as a cause of epidural fibrosis, LaRocca and Macnab [11]
- **Herniated intervertebral disks** → Periradicular fibrosis and vascular abnormalities occurring with Cooper et al [12] reported.
- **Iirritative effect of nucleus pulposus** on the dural sac, adjacent nerve roots, and nerve root sleeves independent of the influence of direct compression on these structures. McCarron et al [13}

Scar tissue IN **Epidural** Space

- **Dorsal**

  reabsorption of surgical **hematoma**

  may be involved in pain generation

Ventral

ventral defects in the disk, which *may persist despite surgical treatment* phase and continue to produce low back pain and radiculopathy past the surgical healing

- **lateral**

  lateral recesses or “sleeves,”

  lateral disk defects

  facet hypertrophy

  neuroforaminal stenosis

- **Scar tissue itself is not tender, an entrapped nerve root is.** Kuslich et al
- **Fixing it in one position** and thus increasing the **susceptibility of the nerve root to tension or compression**.
- They also concluded that no other tissues in the spine are capable of producing leg pain.

Diagnosis and radiologic diagnosis of epidural fibrosis

- provocative test called '**dural tug.**'
- To perform the test, the patient should be instructed to sit up with a straight leg, bend forward flexing the lumbar spine until their back pain starts to become evident, and the head and neck flexed rapidly forward
- During this maneuver, the dura is stretched cephalad and if adhered to structures such as the posterior longitudinal ligament, the most heavily innervated spinal canal structure, the movement of the dura will elicit back pain that is localized to the pain generator.
- A positive dural tug maneuver has been observed to resolve after percutaneous neuroplasty

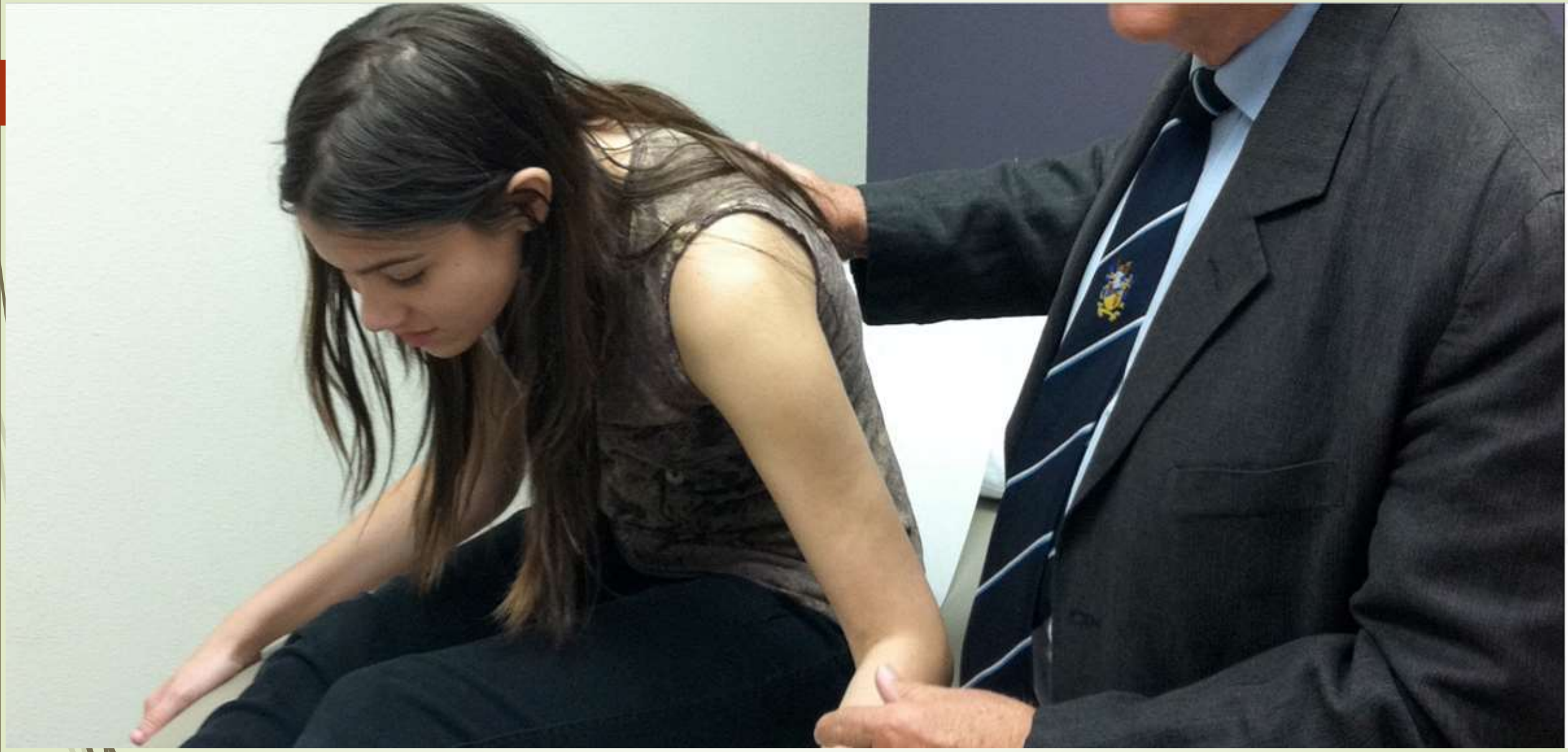

- **MRI** and **CT** are diagnostic ; sensitivity and specificity are **50% and 70%,** respectively
- **CT myelography** may also be helpful,
- although none can identify epidural fibrosis with 100% reliability.
- In contrast, **Epidurography** is a technique used with considerable success and it is believed that epidural fibrosis is best diagnosed by performing an epidurogram
- It can detect filling defects in good correlation with a patient's symptoms in real time

Indications for epidural adhesiolysis

- Although originally designed to treat radiculopathy secondary to epidural **fibrosis following surgery**, the use of epidural adhesionolysis has been expanded to treat a multitude of pain etiologies. These include the following:
- 1. FBSS
- 2. Post-laminectomy syndrome of the neck and back after surgery
- 3. Disk disruption
- 4. Metastatic carcinoma of the spine leading to compression fracture

- 5. Multilevel degenerative arthritis
- 6. Facet pain
- 7. Spinal stenosis
- 8. Pain unresponsive to spinal cord stimulation and spinal opioids
- 9. Thoracic disk related chest wall and abdominal pain (after mapping)

Absolute contraindications

- 1. Sepsis
- 2. Chronic infection
- 3. Coagulopathy
- 4. Local infection at the procedure site
- 5. Patient refusal

Relative contraindication

- **Arachnoiditis.**

  chance of loculation

  subdural or subarachnoid
- **Syrinx formation**

Risks

- bruising, bleeding, infection, reaction to medications used (i.e., hyaluronidase, local anesthetic, corticosteroids, hypertonic saline), damage to nerves or blood vessels, no or little pain relief, bowel/bladder incontinence, worsening of pain, and paralysis.
- **Urinary incontinence** should have an **urodynamic evaluation** by a urologist before the procedure to document the preexisting urodynamic etiology and pathology

Preoperative laboratory

- **CBC & U/A** are obtained to check for any undiagnosed **infections → postpone**

- **History of bleeding**, abnormalities a PT &PTT and platelet function assay or BT, are obtained to check for coagulation abnormalities

Caudal approach

- Prone position
- Together and heels apart
- Sterile preparation
- The **sacral hiatus** is identified via **palpation** just caudal to the sacral cornu or with **fluoroscopic guidance**.
- 1-inch lateral and 2 inches caudal to the sacral hiatus on the side opposite the documented radiculopathy.
- 16-gauge RX Coudé 45-degree angle and guided fluoroscopically or by palpation to the sacral hiatus

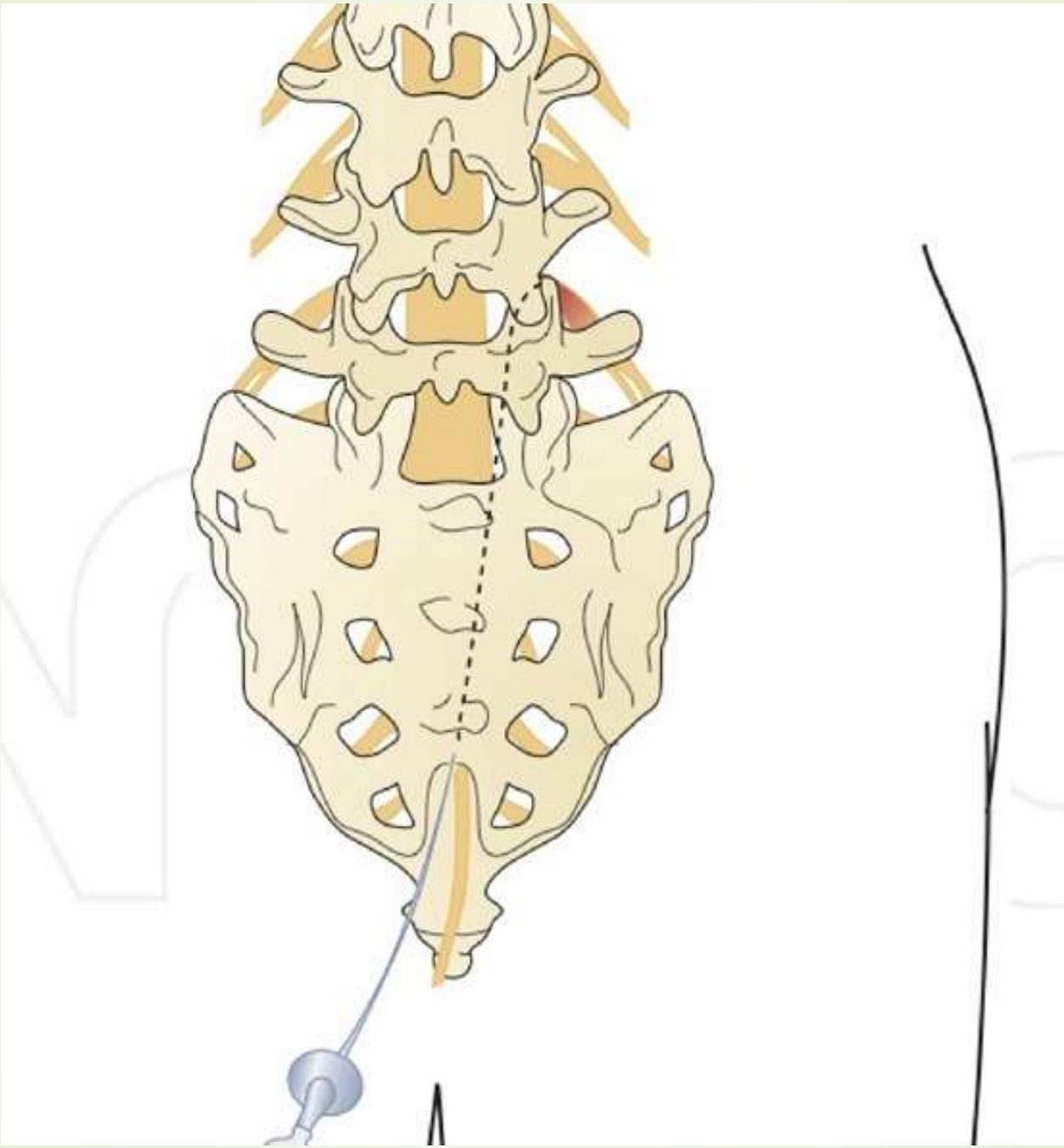

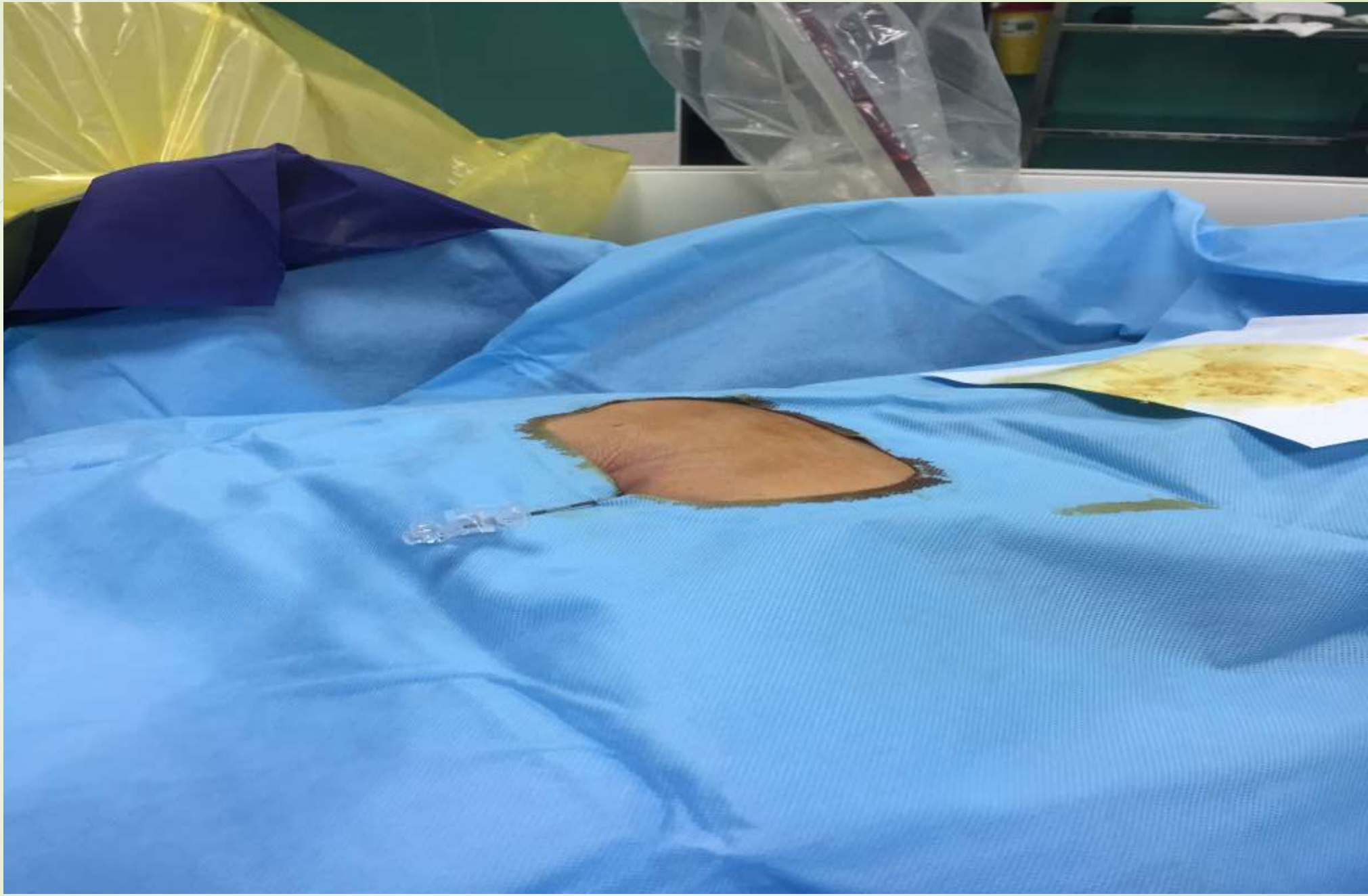

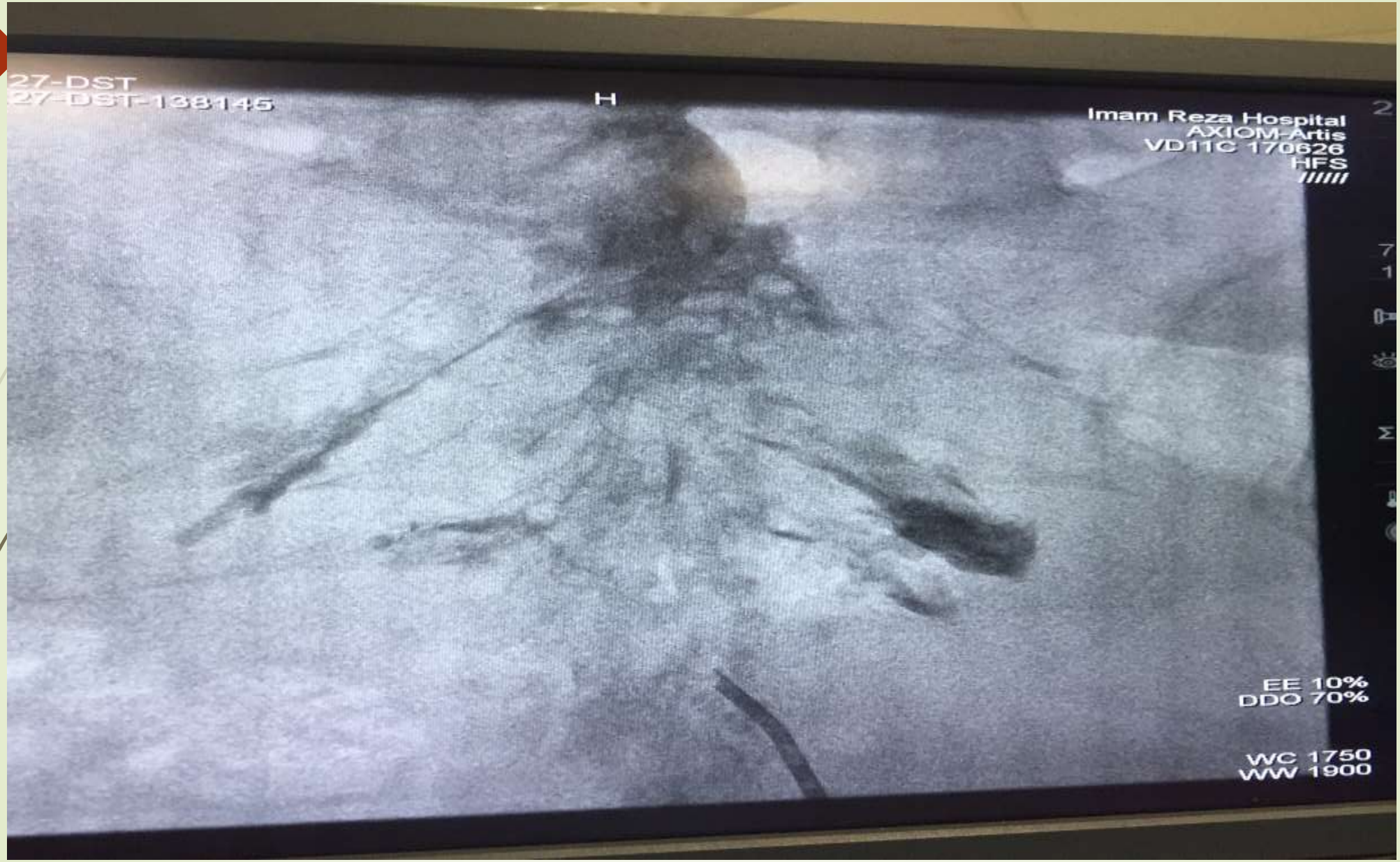
27-DST
27-DST-138145
H
Imam Reza Hospital
AXIOM-Artis
VD11C 170626
HFS
EE 10%
DDO 70%
WC 1750
WW 1900

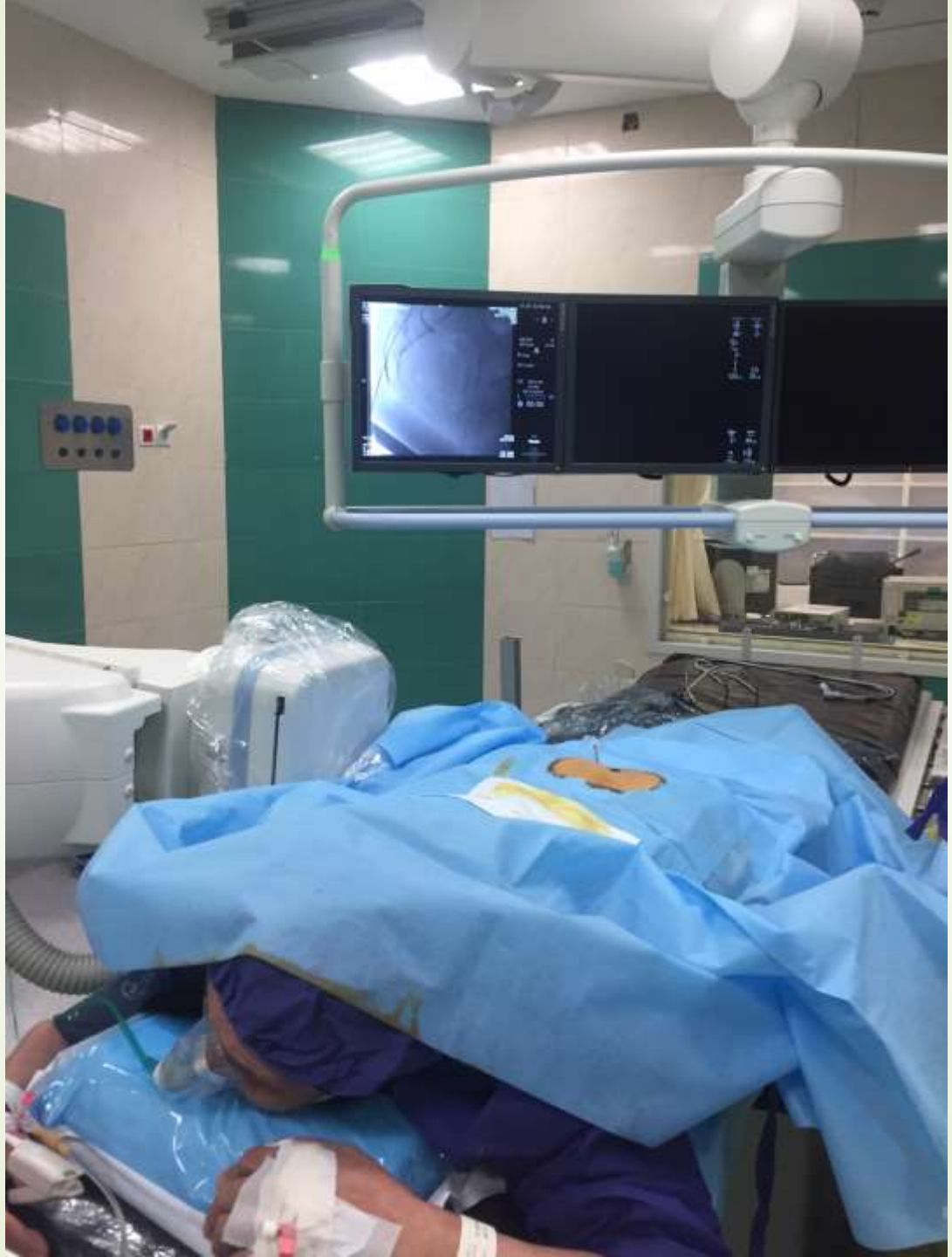

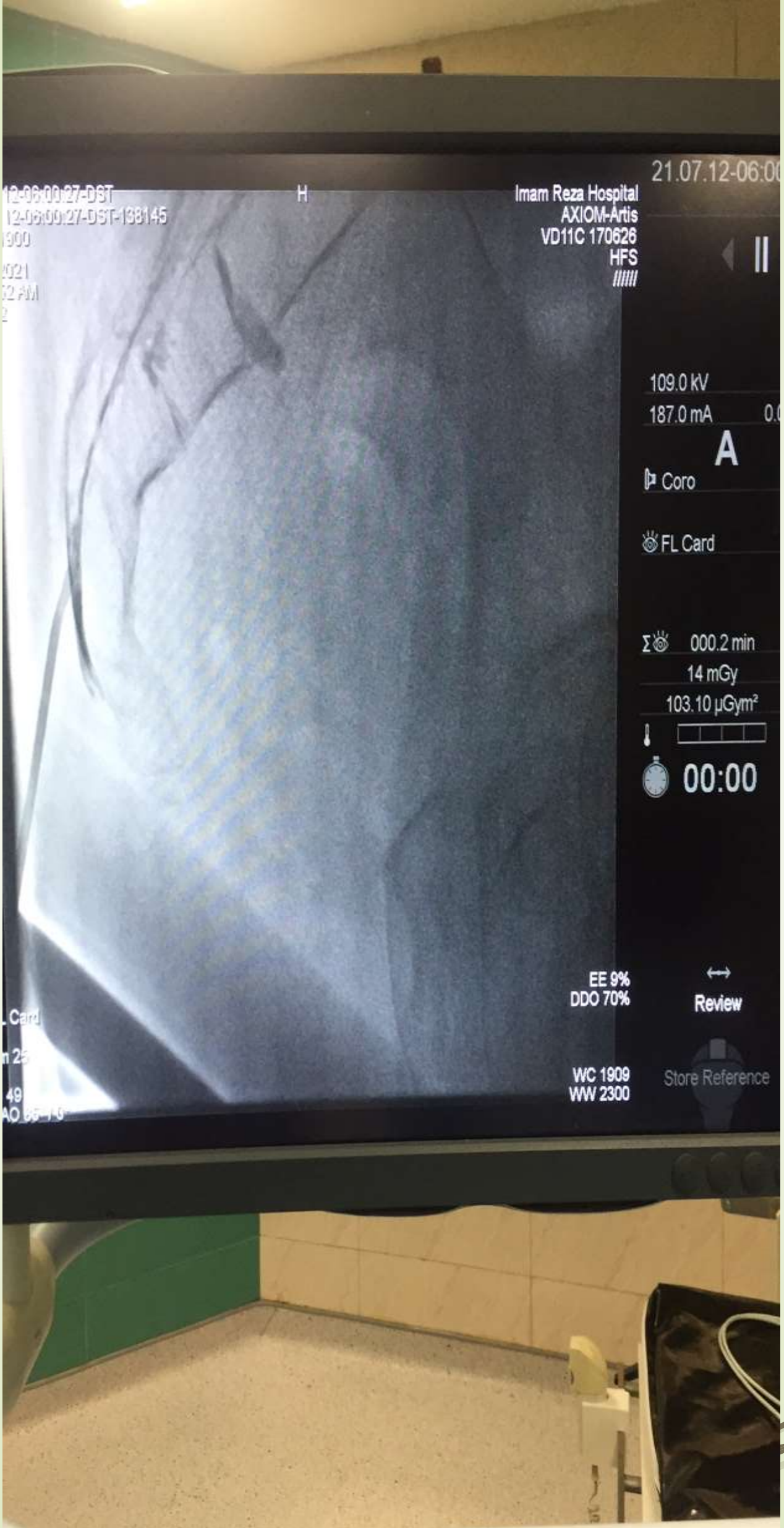
21.07.12-06:00
H
Imam Reza Hospital
AXIOM-Artis
VD11C 170626
HFS
109.0 kV
187.0 mA
A
Coro
FL Card
000.2 min
14 mGy
103.10 µGym²
00:00
EE 9%
DDO 70%
Review
WC 1909
WW 2300
Store Reference

- A normal epidurogram will have a "**Christmas tree**" pattern
- presumed scarring and **typically correspond to the patient's radicular complaints.**
- If **vascular uptake** is observed, the needle needs to be redirected.

- Turning the distal opening of the needle **ventral lateral**
- Insert a TunL Kath or TunL-XL (stiffer) catheter
- The **bend** should be 2.5 cm from the tip of the catheter and at a 30-degree angle.
- The bend will enable the catheter to be **steered** to the target level

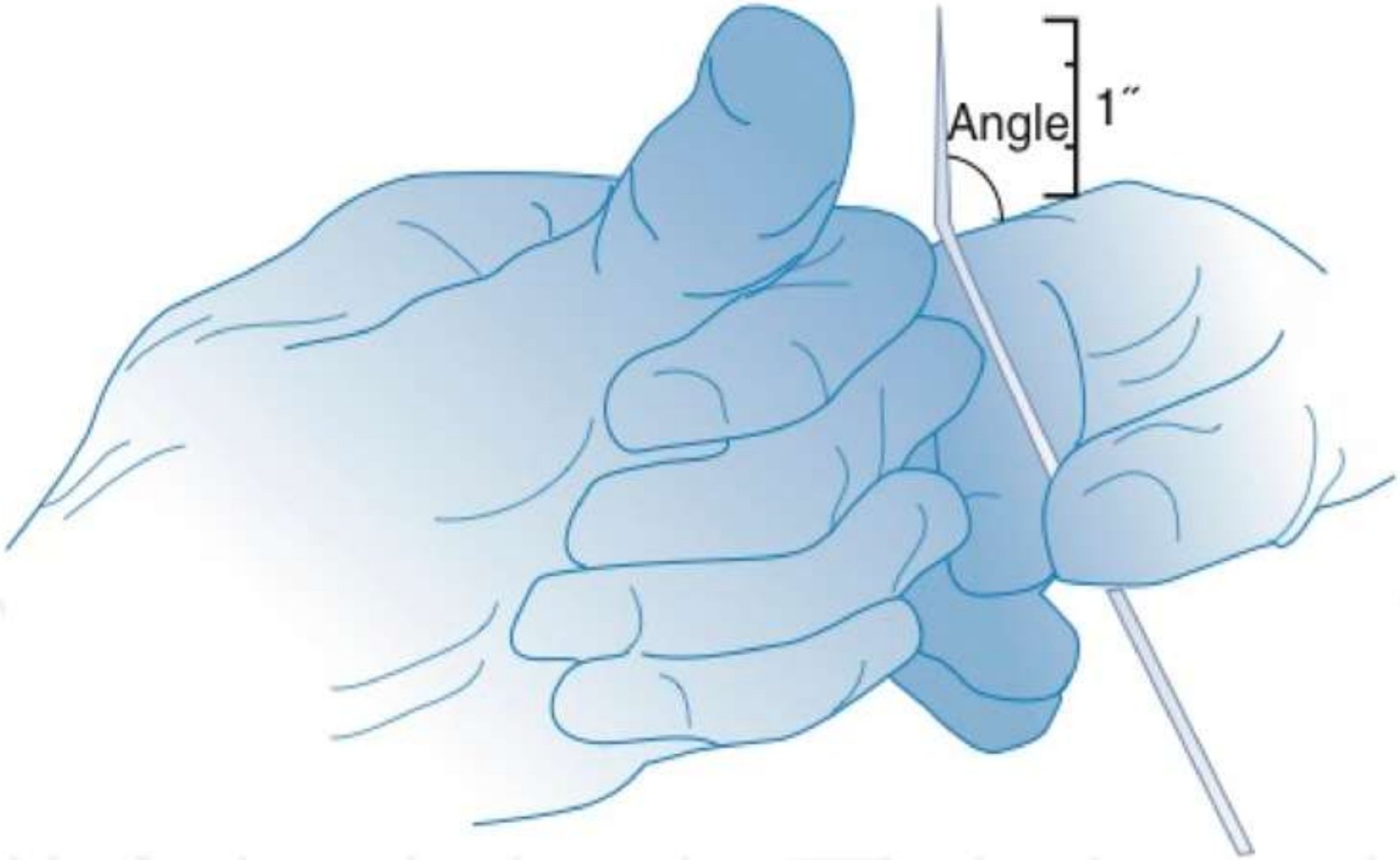
Angle
1″

- Catheter toward the **ventral-lateral epidural space** of the desired level.
- Twisting the catheter in a clockwise /counterclockwise direction.
- **Do not advance** the catheter up the **middle of the sacrum** because this makes guiding the catheter to the ventrallateral epidural space more difficult.
- Ideal location : **foramen just below the midportion of the pedicle shadow**

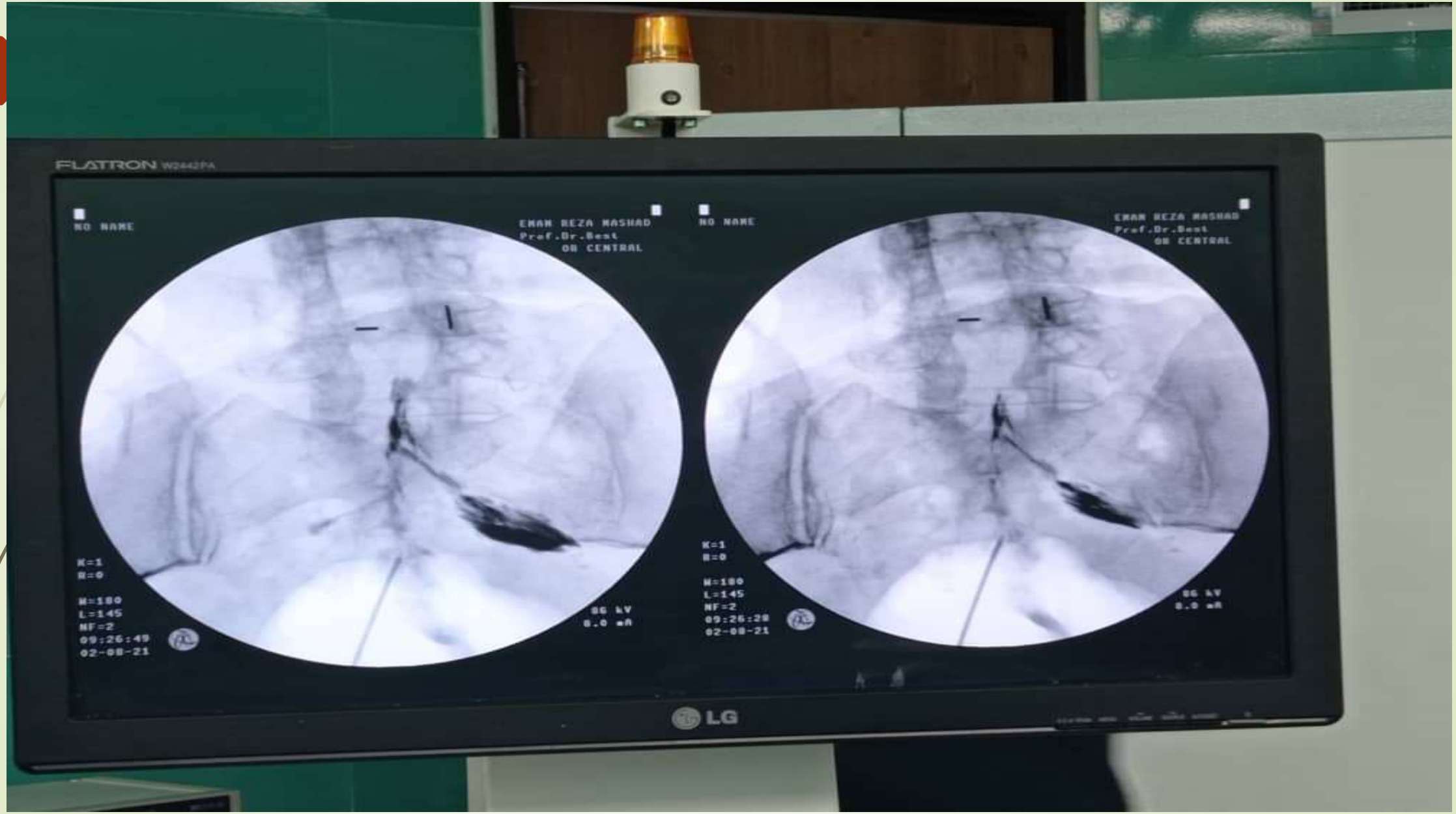
FLATRON W2442PA
NO NAME
EMAM REZA MASHAD
Pref.Dr.Best
OR CENTRAL
NO NAME
EMAM REZA MASHAD
Pref.Dr.Best
OR CENTRAL
K=1
R=0
W=180
L=145
NF=2
09:26:49
02-08-21
86 kV
8.0 mA
K=1
R=0
W=180
L=145
NF=2
09:26:28
02-08-21
86 kV
8.0 mA
LG

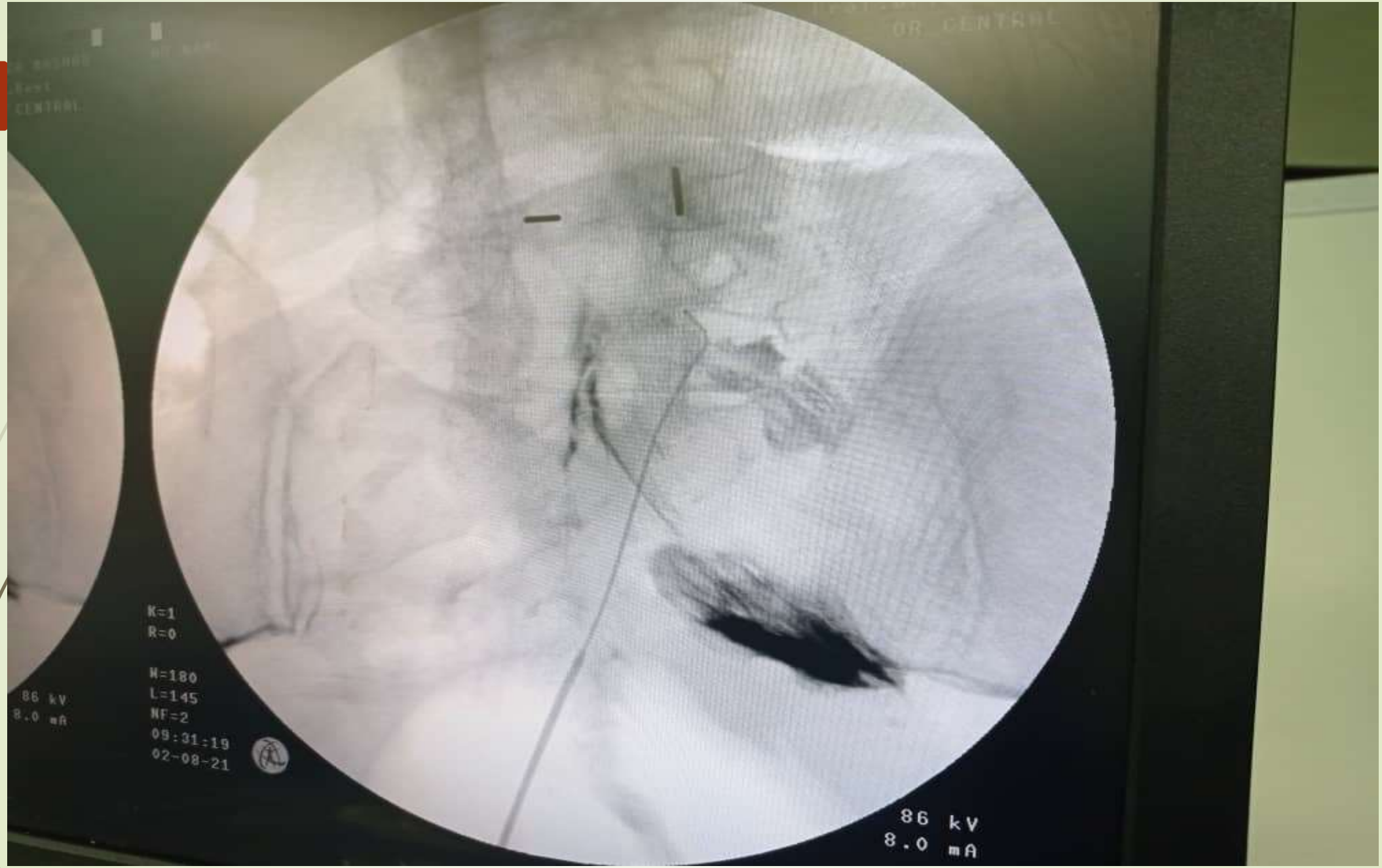
OR CENTRAL
K=1
R=0
W=180
L=145
NF=2
09:31:19
02-08-21
86 kV
8.0 mA

- Check a lateral projection to confirm that the catheter tip is in the ventral epidural space

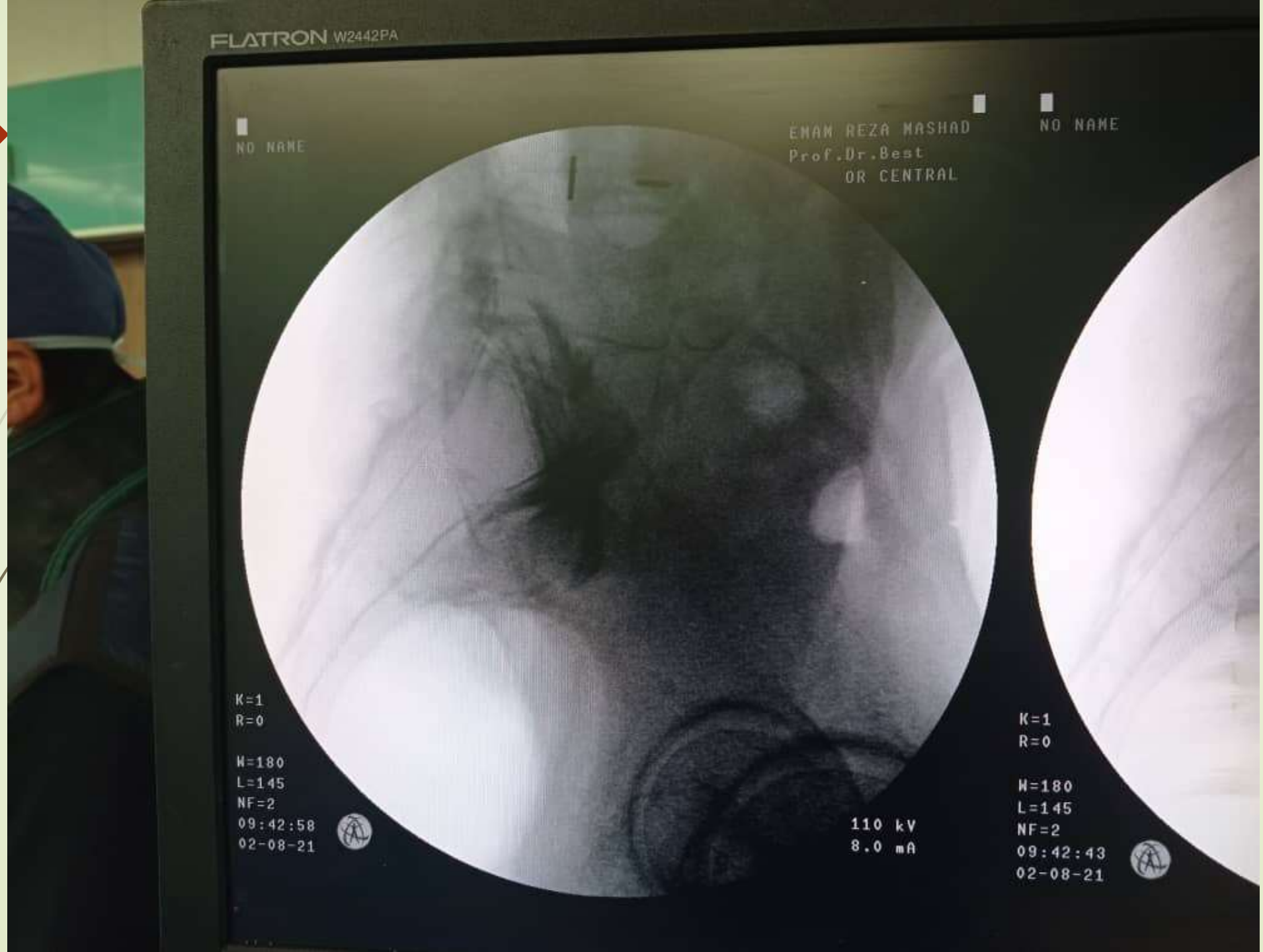
FLATRON W2442PA
NO NAME
EMAM REZA MASHAD
Prof.Dr.Best
OR CENTRAL
NO NAME
K=1
R=0
W=180
L=145
NF=2
09:42:58
02-08-21
110 kV
8.0 mA
K=1
R=0
W=180
L=145
NF=2
09:42:43
02-08-21

- Inject 2 to 3 mL of additional contrast through the catheter in an attempt to outline the "**scarred in" nerve root**

- Inject 1500 U of hyaluronidase dissolved in 10 mL of preservative-free normal saline.

- A newer development is the use of Hylenex or **human-recombinant hyaluronidase**, which carries the advantage of a reportedly increased effectiveness at the body's normal pH compared to bovinerecombinant hyaluronidase
- This injection may cause some discomfort, so a slow injection is preferable.

- Observe for “opening up”(i.e. visualization) of the “scarred in” nerve root .
- A 3 mL test dose of a 10 mL local anesthetic/steroid (LA/S) solution is then given.
- 4 mg of dexamethasone mixed with 9 mL of 0.2% ropivacaine.

- 40 to 80 mg of methylprednisolone (Depo-Medrol),
- 25 to 50 mg of triamcinolone diacetate (Aristocort),
- 40 to 80 mg of triamcinolone acetonide (Kenalog),
- 6 to 12 mg of betamethasone (Celestone Solu span).
- If, after 5 minutes, there is no evidence of intrathecal or intravascular injection of medication, inject the remaining 7 mL of the LA/S solution.

- **A 20-to 30-minute** period should elapse between the last injection of the LA/S solution and the start of the hypertonic saline (10%) infusion.
- This is necessary to ensure that a subdural injection of the LA/S solution has not occurred. A subdural block mimics a subarachnoid block but it takes longer to establish, usually 16 to 18 minutes. Evidence for subdural or subarachnoid spread is the development of motor block. If the patient develops a subarachnoid or subdural block at any point during the procedure, the catheter should be removed and the remainder of the adhesiolysis canceled.

- Remove the needle the catheter remains at the target level
- Secure the catheter to the skin
- transport the patient to the recovery area.

- 10 mL of the hypertonic saline is then infused through the catheter over 15 to 30 minutes.
- If the patient complains of discomfort, the infusion is stopped and an additional 2 to 3 mL of 0.2% ropivacaine is injected and the infusion is restarted.
- Alternatively, 50 to 75 μ g of fentanyl
- After completion of the hypertonic saline infusion, the catheter is slowly **flushed with 2 mL** of preservative-free normal saline and the catheter is capped.

- **3 injections 6- 8 hours apart within 24 hours**, usually done in an inpatient hospital setting
- 10 mL of 0.2% **ropivacaine without steroid** and infused with 10 mL of hypertonic saline (10%) using the same technique and precautions as the day 1 infusion.
- At the end of the third infusion, the **catheter is removed** and a sterile dressing applied. The patient is **discharged** home with 5 days of oral cephalexin at 500 mg twice a day or oral levofloxacin (Levaquin) at 500 mg once a day for penicillin-allergi

1st sacral foramen approach

- **L5-S1 anterolateral epidural space** is frequently **occupied** with epidural adhesions which are associated with pain and a lack of contrast filling on epidurography.
- Lysis of adhesions via the caudal approach may be difficult in patients with epidural adhesions at this location and the S1 foraminal approach may be used to achieve lysis and fluid foraminotomy at this level

- A unique **triangular space** has been identified by **Teske** et al., measuring 0.9-1.1 mL on each side.1
- The boundaries are **medial to the L5** nerve root, **lateral to the S1** nerve root and the **base** : **disc of L5- S1**.
- This space is large enough to accept the average loose disc fragment/ leaky disc material

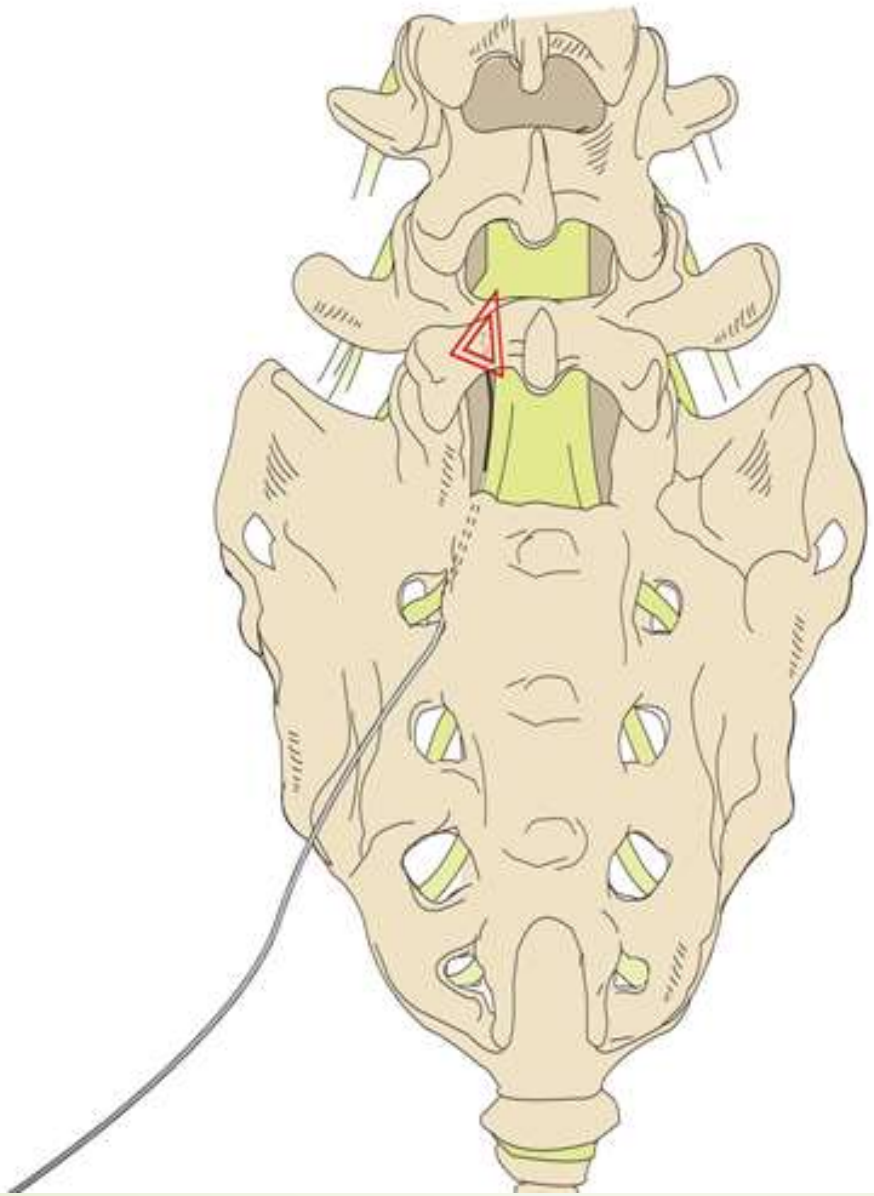

- Due to the **curvature of the sacrum** and the formation of dense scarring, regular epidural catheters and scopes have not been able to enter this scarred epidural area.
- **Matsumoto** et al., realized that entering from the posterior aspect of the S1 neural foramin with an **18 gauge RX-2™ Coudé®** Needle and then rotating it, the curved tip allows for ventral epidural projection of a

  21 G VERSA-KATH®.

- Matsumoto reported 36 cases with adhesive S-1 radiculopathy. After the procedure, the patients were followed up for 12 months. A marked decrease in VAS and improvement in ADL

L5-S1 Scarring clinically

- **Ipsilateral back pain** (due to the dura and posterior longitudinal ligament adhering together),
- **L5 radiculopathy**, numbness and dysesthesia in the lateral calf to the lateral ankle and foot,
- **weakness on dorsal flexion of the foot**. In advanced cases, foot drop may be evident

- Opening of the scarring triangle with the recommended volumes can reverse these clinical symptoms.
- An **S2 component** will present as radiculopathy along the **posterior aspect of the thigh and calf**.
- **Stretch-induced ischemia** of the involved nerve roots is likely the cause of **foot drop** and can be reversed following the scarring triangle neuroplasty

Alignment of Neural Foramina Using C-Arm

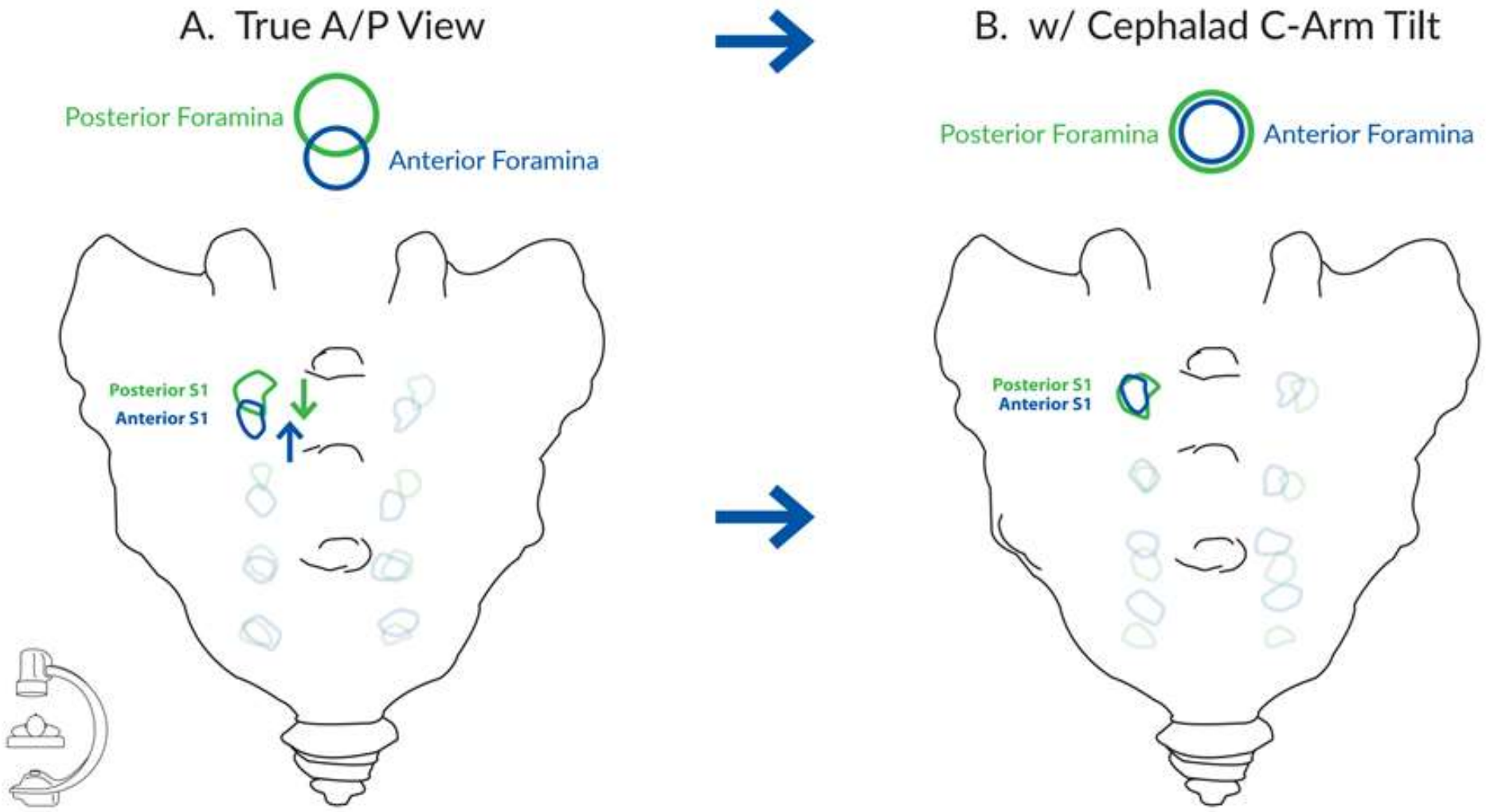

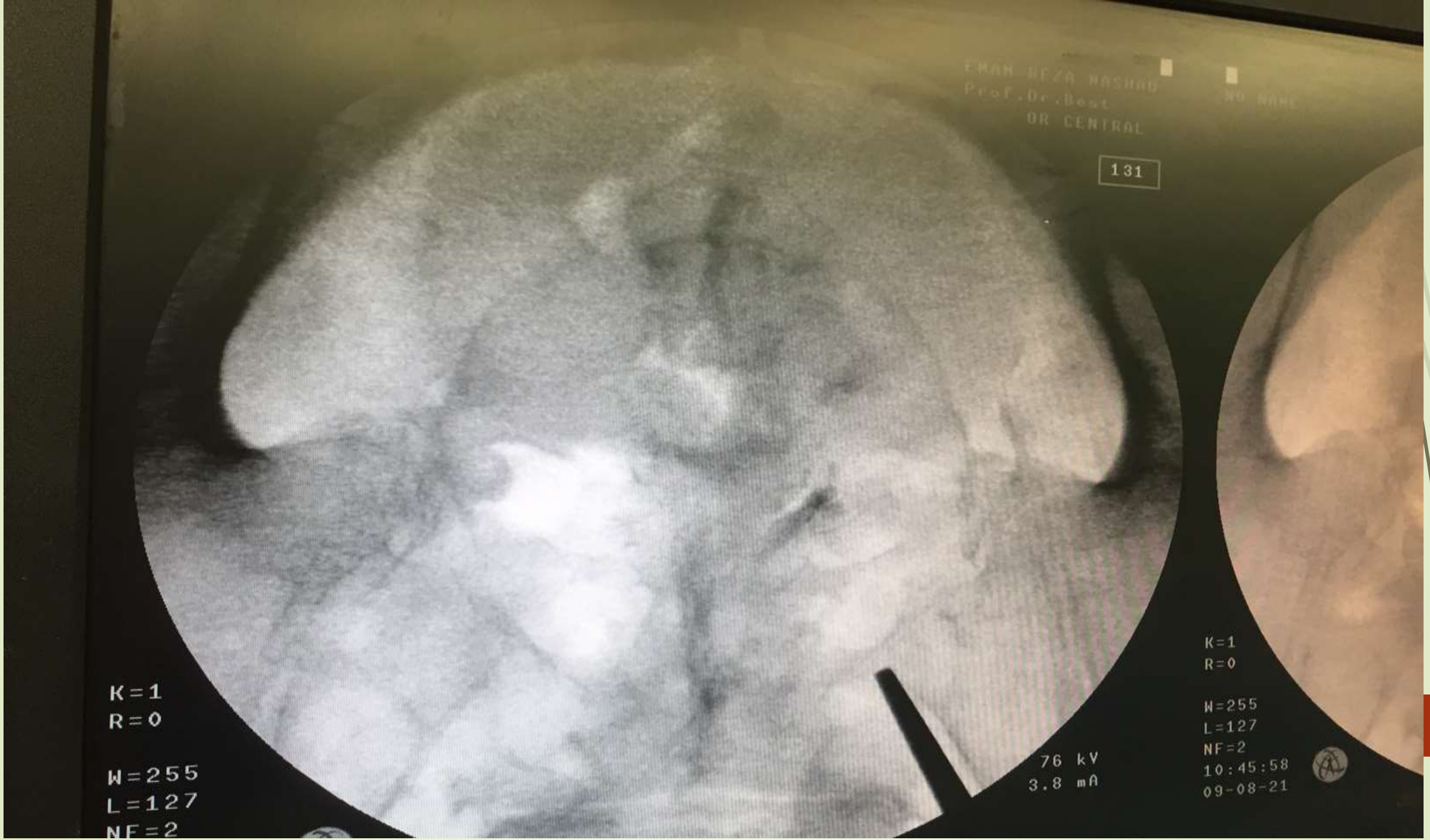
EMAN BEZA MASHAD
Prof.Dr.Best
OR CENTRAL
NO NAME
131
K=1
R=0
W=255
L=127
NF=2
76 kV
3.8 mA
K=1
R=0
W=255
L=127
NF=2
10:45:58
09-08-21

- The needle **entry point** is from the **S2** aiming towards the medial side of S1.
- **Curve** the needle **down** →contact bone between the S1 and S2 .
- Continue to advance until a penetrative "**pop**" is felt, indicating **foraminal entry**.

RX Coudé® Needle Entry Site and Placement

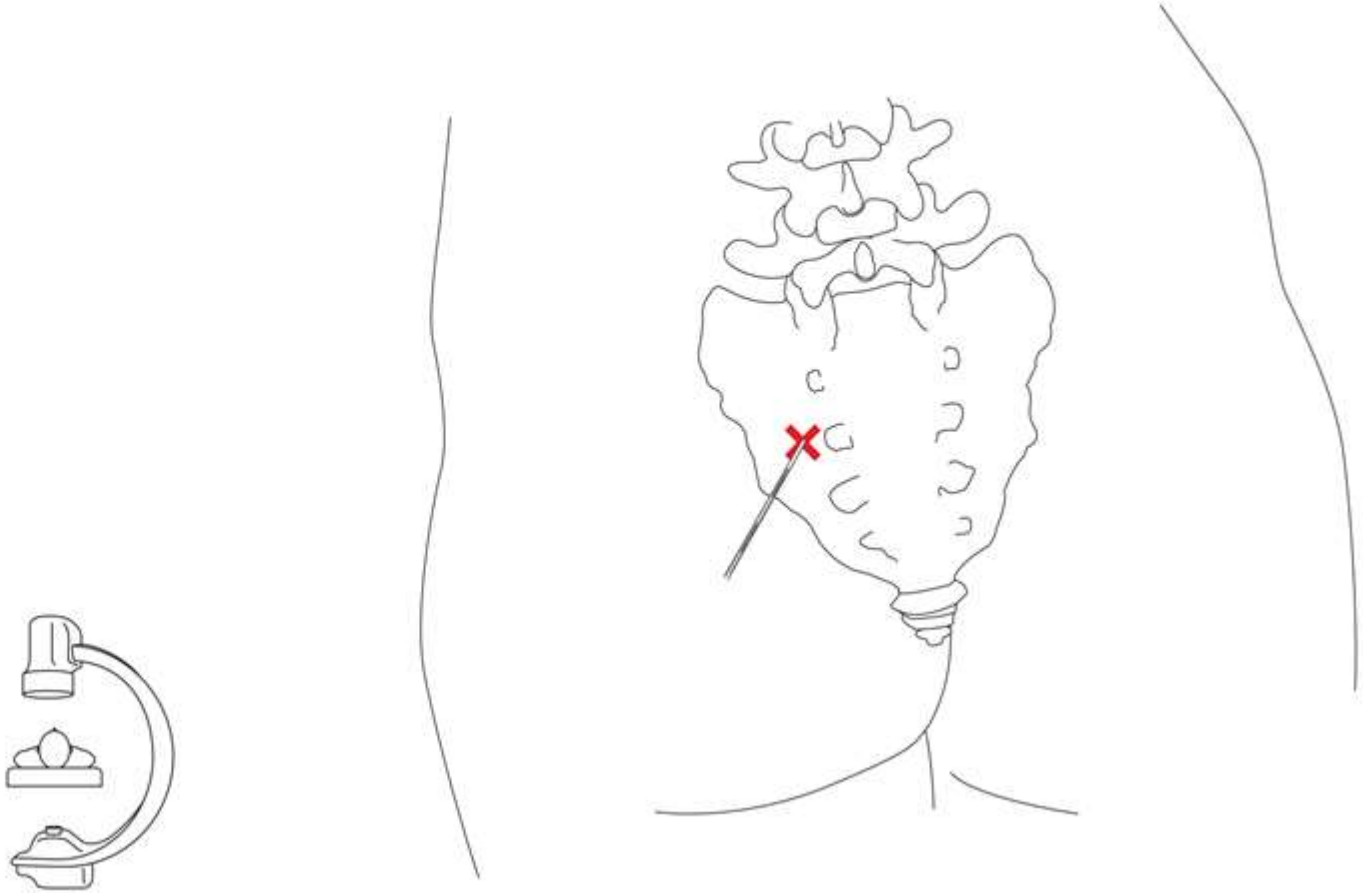

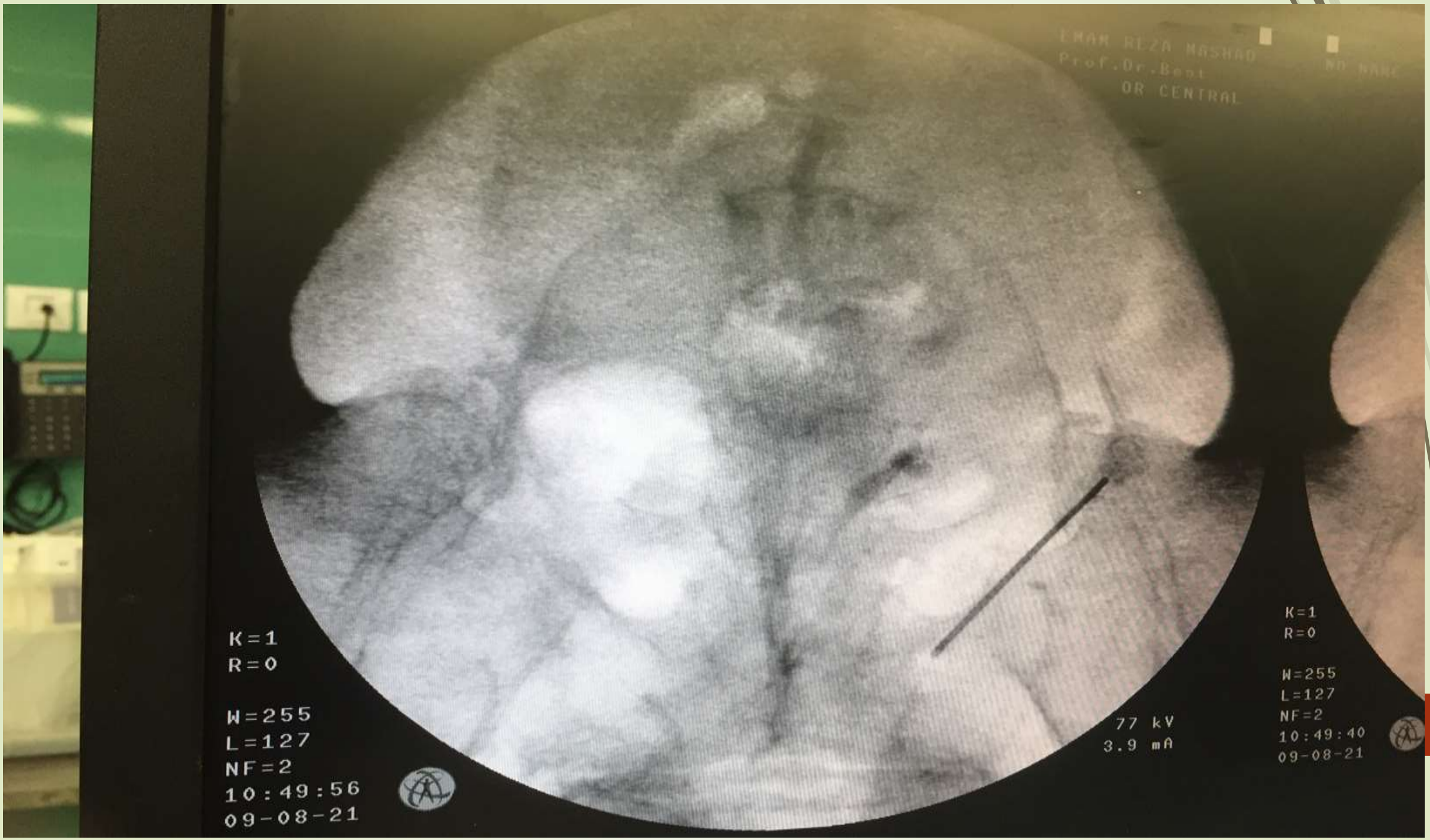
OR CENTRAL
K=1
R=0
W=255
L=127
NF=2
10:49:56
09-08-21
77 kV
3.9 mA
K=1
R=0
W=255
L=127
NF=2
10:49:40
09-08-21


18G
16G
15G
14G

18G
16G
15G
14G

- **Atraumatic, blunt stylet**→ lateral fluoroscopic visualization→ rotate the needle tip **dorsally and medial**.
- Advance the styletted VERSA-KATH® into the sacral canal under fluoroscopic visualization
- The catheter needs to **cross the L5-S1 disc space** and advance into the fibrotic tissue (scar) near the **top of the L5 neural foramen**.
- The catheter should not advance medial or lateral inside the imaginary triangle between L5 and S1

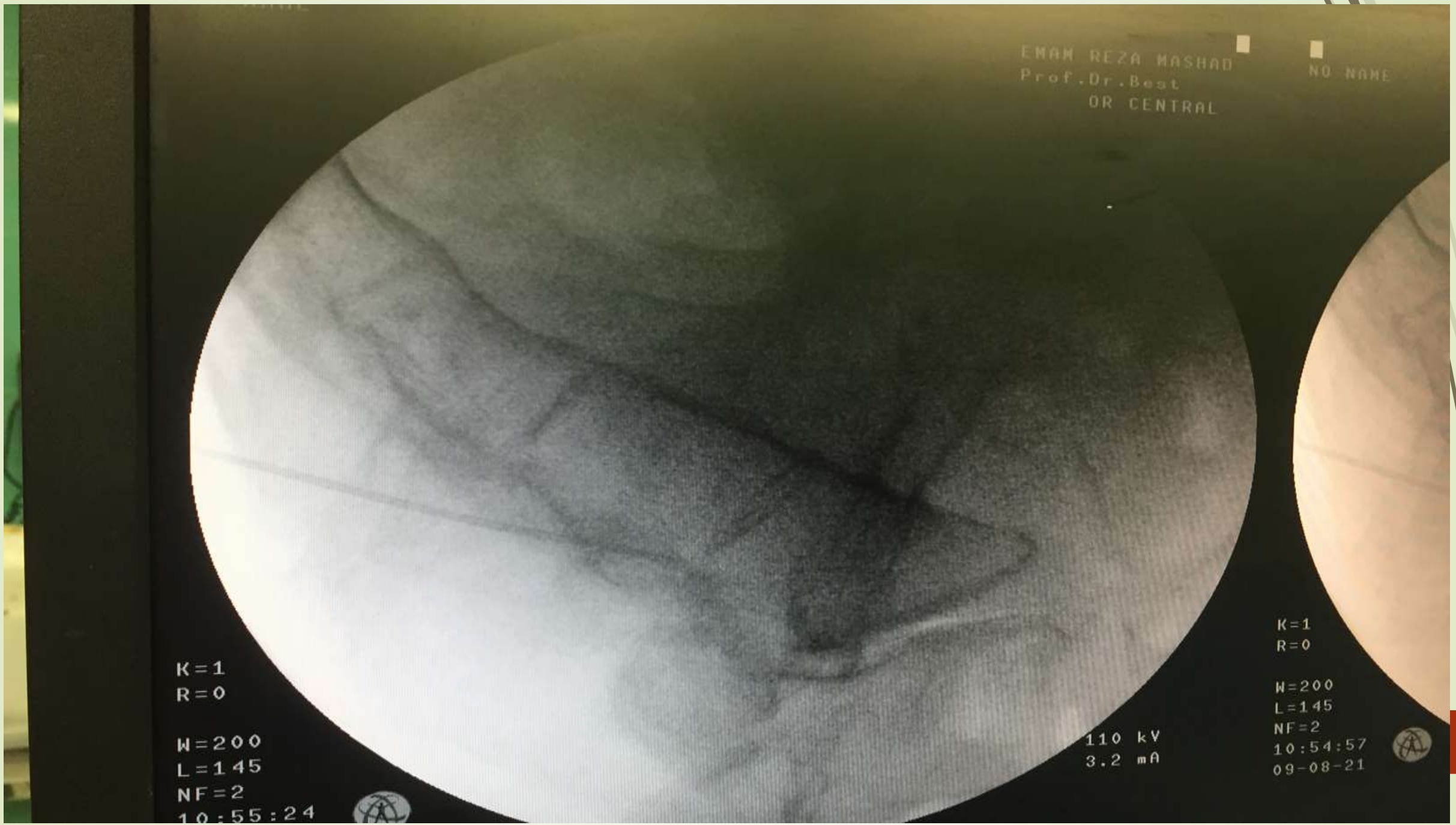
EMAM REZA MASHAD
Prof.Dr.Best
OR CENTRAL
NO NAME
K=1
R=0
W=200
L=145
NF=2
10:55:24
110 kV
3.2 mA
K=1
R=0
W=200
L=145
NF=2
10:54:57
09-08-21

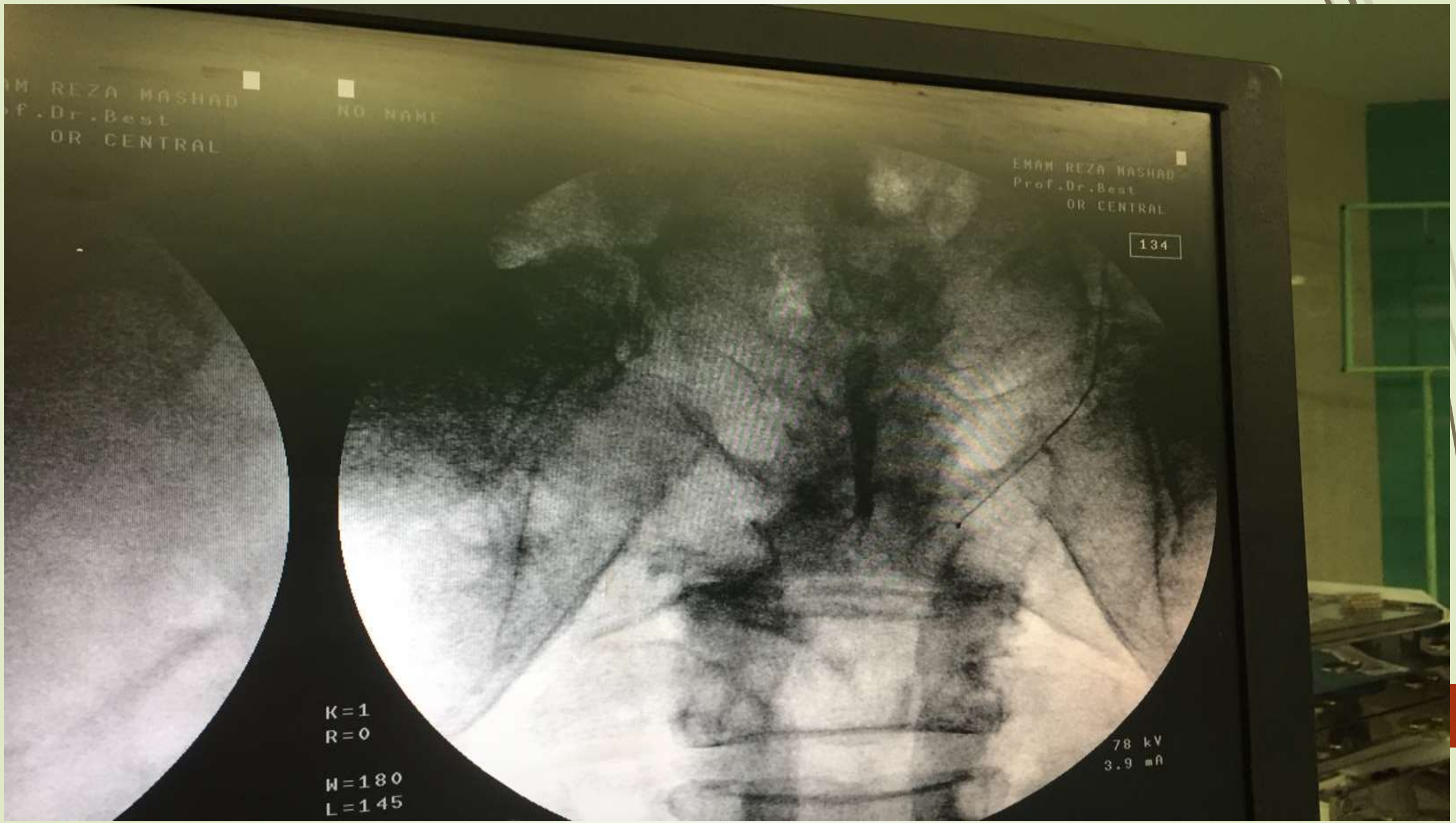
M REZA MASHAD
f.Dr.Best
OR CENTRAL
NO NAME
EMAM REZA MASHAD
Prof.Dr.Best
OR CENTRAL
134
K=1
R=0
W=180
L=145
78 kV
3.9 mA

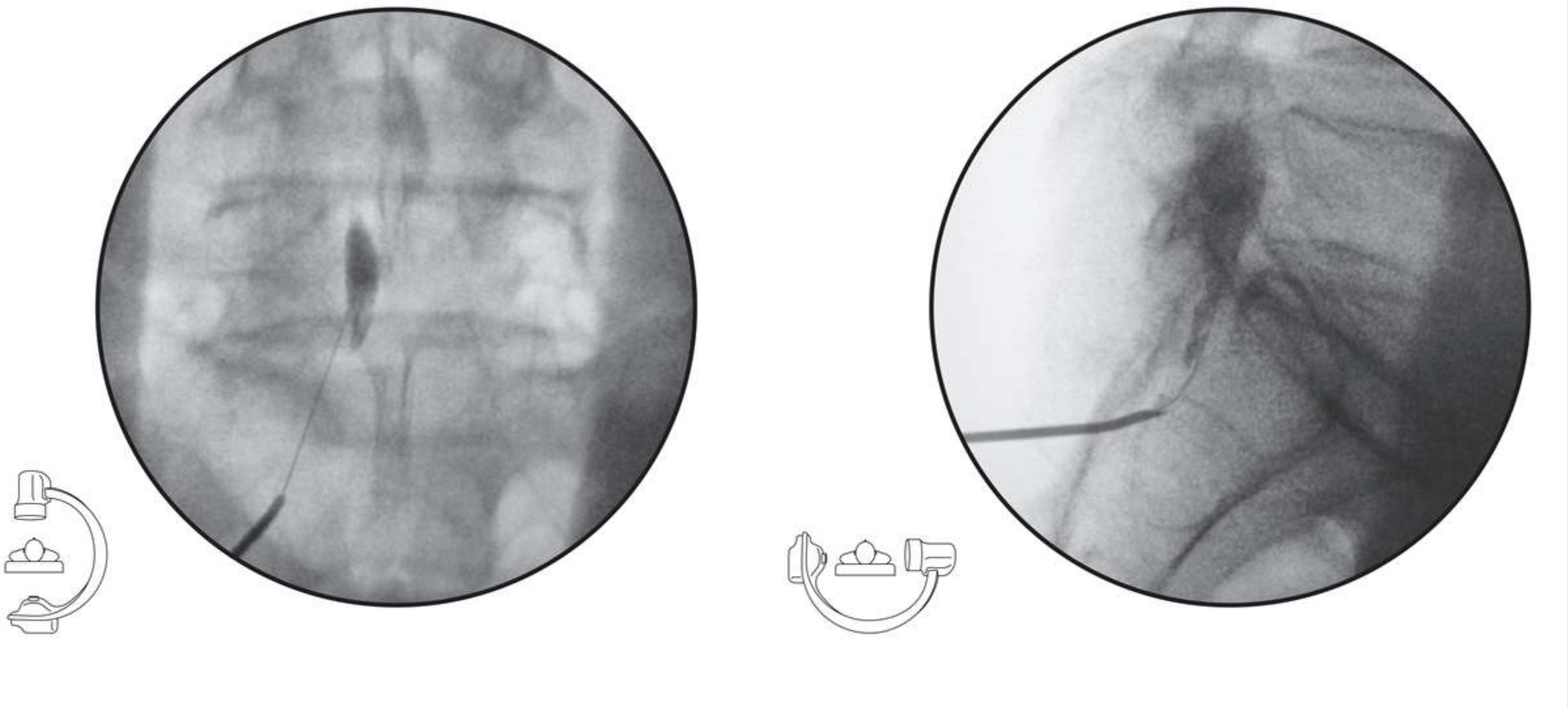

FLATTRON W2442PA
W=200
L=110
WF=2
11:50:25
03-05-21
94 kV
3.6 mA
W=200
L=110
WF=2
11:49:32
03-05-21
94 kV
3.6 mA
LG

- **1-inject 5-10 cc of OMNIPAQUE™ 240** to open up the ventral epidural space, slowly crossing over, and spread from L4 down to S2 bilaterally.
- 2- **10 cc** of preservativefree saline and **150 units of Hylenex®**; this will disperse the contrast.
- Carefully observe for a potential spread into the subdural and subarachnoid spaces, **especially in failed** surgery cases where the **possibility of a dural tear may** exist.

- 3.**10 cc of 0.2% ropivacaine and 40 mg triamcinolone**. Ask the patient to move their feet and to report any pain at any time other than during injection. **Subdural injectate** accumulation in the scarred area may produce **bilateral pain** and have **atypical appearance**. **If subdural loculation** occurs, it can be **aspirated** with an interlaminar needle placement.
- 4. **20-30 minutes** and make sure any evidence of motor block.
- 5. Infuse **10% NaCl** over a 15-minute period. Then flush with local anesthetic

Cervical Adhesionolysis

- Paramedian approach
- The most common l**T1-2 and C7-T1**. Entry at these levels allows for a sufficient length of the catheter to remain in the epidural space
- If the target is the lower cervical nerve roots, a more caudal interspace should be selected.
- **left lateral decubitus position**, but use a **prone** approach in larger patients.

- The skin entry **one and a half levels below** the target interlaminar space, **toward the midpoint** of the chosen interlaminar spac **pointing medial**.
- Usually **at 2 to 3 cm** check the **depth** : **lateral image**.
- Junction of the **base of the spinous process with its lamina**. This junction creates a distinct radiopaque "**straight line.**"
- Once the needle is close to the epidural space, obtain an AP fluoroscopic image

- Using **loss-of-resistance technique**, advance the needle into the epidural space
- the tip of the RX-Coudé needle, **pointed caudally**. Once the tip is in the epidural space→ second interlocking stylet →**rotate the tip cephalad**, and inject 1 to 2 mL of contrast to confirm entry

- Inject an additional small volume as needed to complete the **epidurogram.**
- If there is no free flow of injected contrast, pressure may build up in the lateral epidural space.
- **Characteristic fluid spread** by the path of **least resistance** can be recognized as perivenous counter spread (PVCS). Presence of PVCS means pressure builds up in the lateral epidural space that is unable to spread laterally to decompress

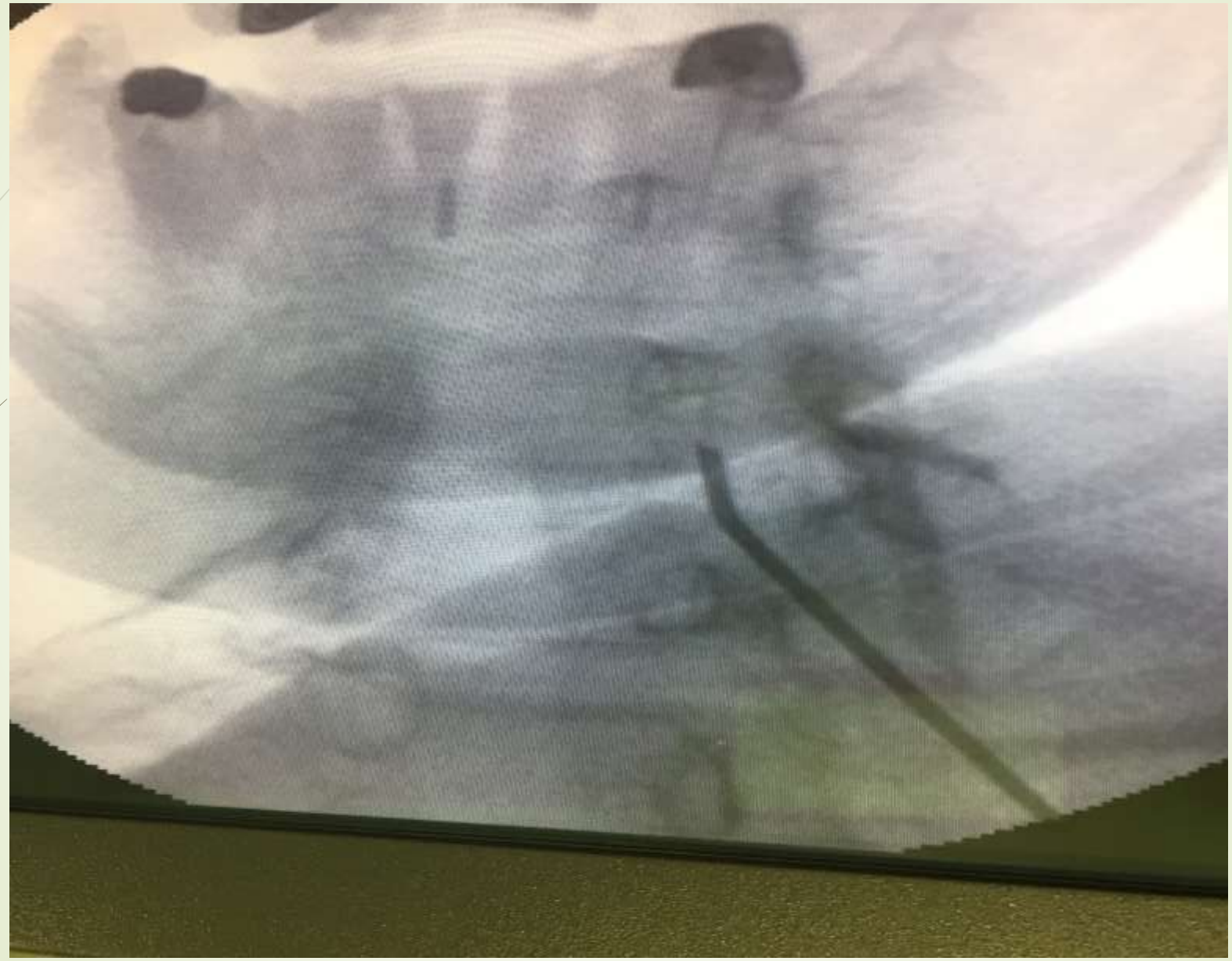

- **Loculation of contrast** in a small area must be avoided as this can significantly increase the pressure in the epidural space
- Pressure may build up and lead **to ischemic spinal cord injury**.
- **Flexion and rotation of the head and neck** can open up lateral runoff and release the pressure through the enlarged neural foramina

- Place a **bend** on the catheter
- The **opening of the needle** should be directed toward the **target** side
- Slowly advance the **catheter** to the lateral gutter and direct it **cephalad.**
- **Redirect the catheter** as needed and once the target level has been reached, turn the tip of the catheter toward the **foramen**

- **0.5 to 1** mL of **contrast** to visualize the target nerve root.
- Make sure there is **runoff** of contrast **out of the foramen**
- Slowly instill **150 U of Hylenex** dissolved in 5 mL of preservative-free normal saline.
- Follow this with **1 to 2 mL of additional contrast** and observe for "**opening up" of the "scarred in" nerve root**.

- Give **a 2 mL test dose** of a 6 mL solution of LA/ S. Our combination is 5 mL of 0.2% ropivicaine and 4 mg of dexamethasone. If after **5 minutes** there is no evidence of **intrathecal or intravascular** spread, inject the remaining 4 mL.

- Once **20 minutes** have start an infusion of **5 mL** of **hypertonic saline** over 30 minutes.

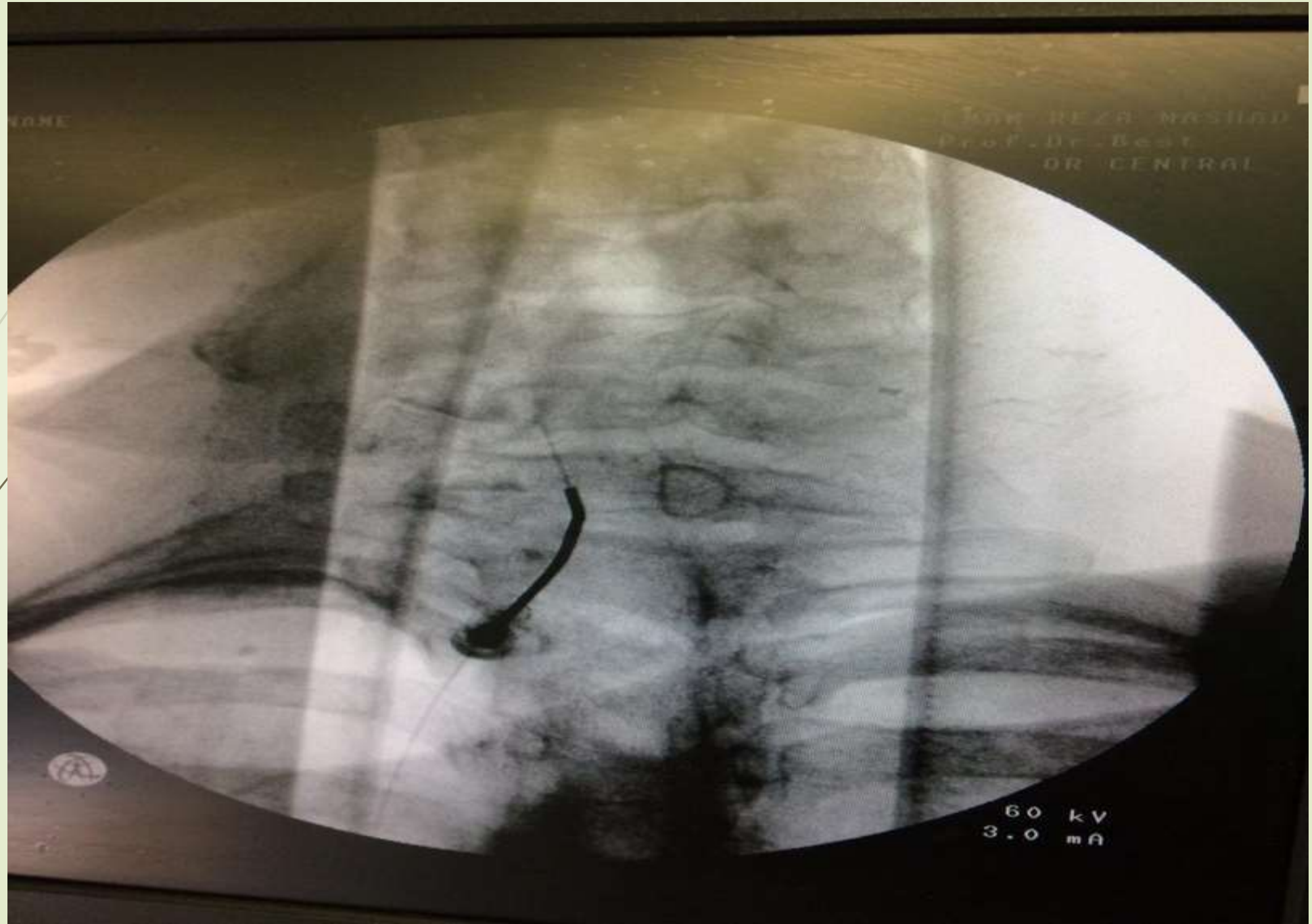
NAME
Prof.Dr.Best
OR CENTRAL
60 kV
3.0 mA

	Contrast	Hyaluronidase and Normal Saline	Local Anesthetic and Steriod	10% Hypertonic Saline Infusion
Caudal	10 mL	10 mL	10 mL	10 mL
Caudal and transforaminal	5 mL in each catheter	5 mL in each catheter	5 mL in each catheter	8 mL in caudal catheter and 4 mL in transforaminal catheter
Thoracic	8 mL	8 mL	8 mL	8 mL
Cervical	5 mL	6 mL	6 mL	5 mL

Table 1. Typical Infusion Volumes for Epidural Adhesiolysis

Thoracic

- Identical to that for the cervical region.

- The major difference for thoracic lysis compared to the caudal and cervical techniques is the **volumes** of the various injectates.
- Volumes of 8 mL are used for the contrast, Hylenex, LA/S, and hypertonic saline

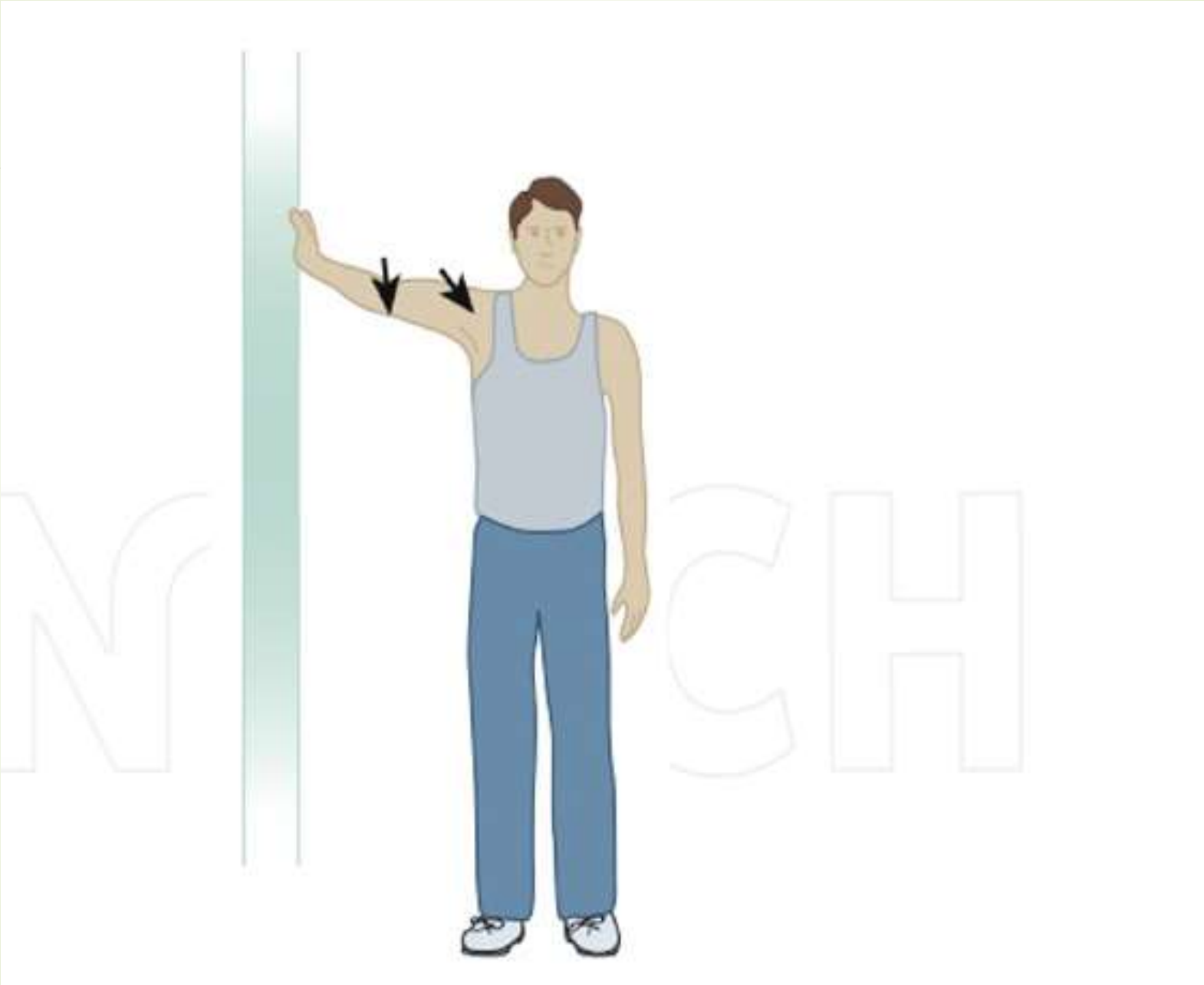

Figure 38. Neural flossing exercises, part 3: Finally, rotate chin toward opposite shoulder as is comfortable. Hold this final position for approximately 20 to 30 seconds.

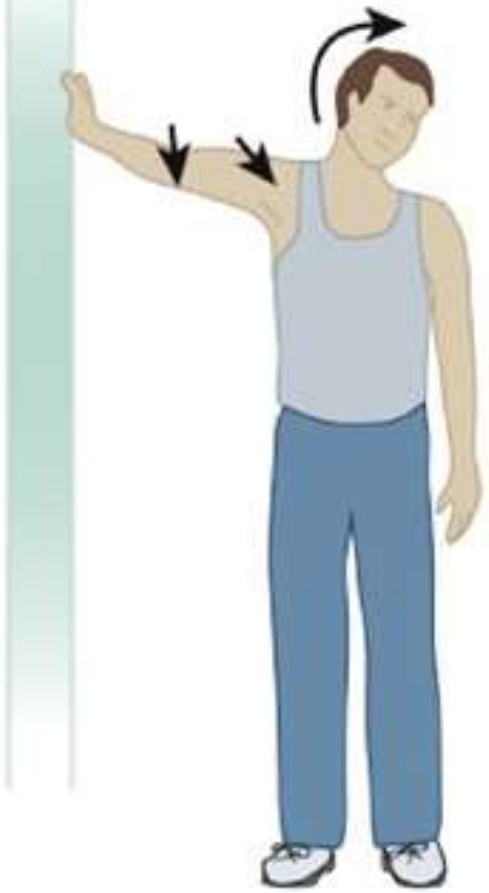

Figure 37. Neural flossing exercises, part 2: Next, slowly tilt head in opposite direction from outstretched arm to achieve gentle tension.

Figure 39. Neural flossing exercises, part 4: Lay down supine on an exercise mat without a pillow. Slowly bring both knees close to the chest with bent legs and hold this position for 20 seconds. Release and assume a neutral position.

Figure 40. Neural flossing exercises, part 5: Again in supine position, raise both legs to 90 degrees, with knees straight while laying flat on a firm surface. Hold for 20 seconds. Assume a neutral position and rest briefly.

Figure 41. Neural flossing exercises, part 6: Bring both legs to a 90-degree angle while lying supine. Slowly spread legs in a V shape, as much as is comfortable, and hold for 20 seconds.

Complications

- Bleeding
- Infection
- Headache
- Damage to nerves or blood vessels
- Catheter shearing
- Bowel/bladder dysfunction, paralysis
- Spinal cord compression from loculation of the injected fluids or hematoma
- Subdural or subarachnoid injection of local anesthetic or hypertonic saline
- Reactions to the medications used