Keep Calm
&
Labour without Pain

Dr. Maryam Rahimi

Gynecologist & Obstetrician

IUMS Assistant professor

The experience of labour is complex and subjective.

factors affect a woman's perception of labour making each experience unique. However as a consistent finding, labour pain is ranked high on the pain rating scale when compared to other painful life experiences[1].

The memory of this pain however is short lived and of parturients who experienced severe pain in labour, 90% found the experience satisfactory three months later.

This short term memory may be related to the positive outcome that often occurs at the end of labour.

- The pattern of labour pain differs between nulliparous and multiparous women and it is well documented that pain scores are higher in the nulliparous compared to the multiparous woman especially if there has been no antenatal education.
- Consistent findings also indicate that nulliparous women on average experience greater sensory pain during early labour compared to multiparous women[3] who seem to experience more intense pain during the pelvic phase of labour as a result of sudden stimulation of nociceptors surrounding the vaginal vault, vulva and perineum[4] and rapid descent of the foetus[5,6].
- Labour pain as well as being unpleasant for the mother, can have deleterious effects on the foetus

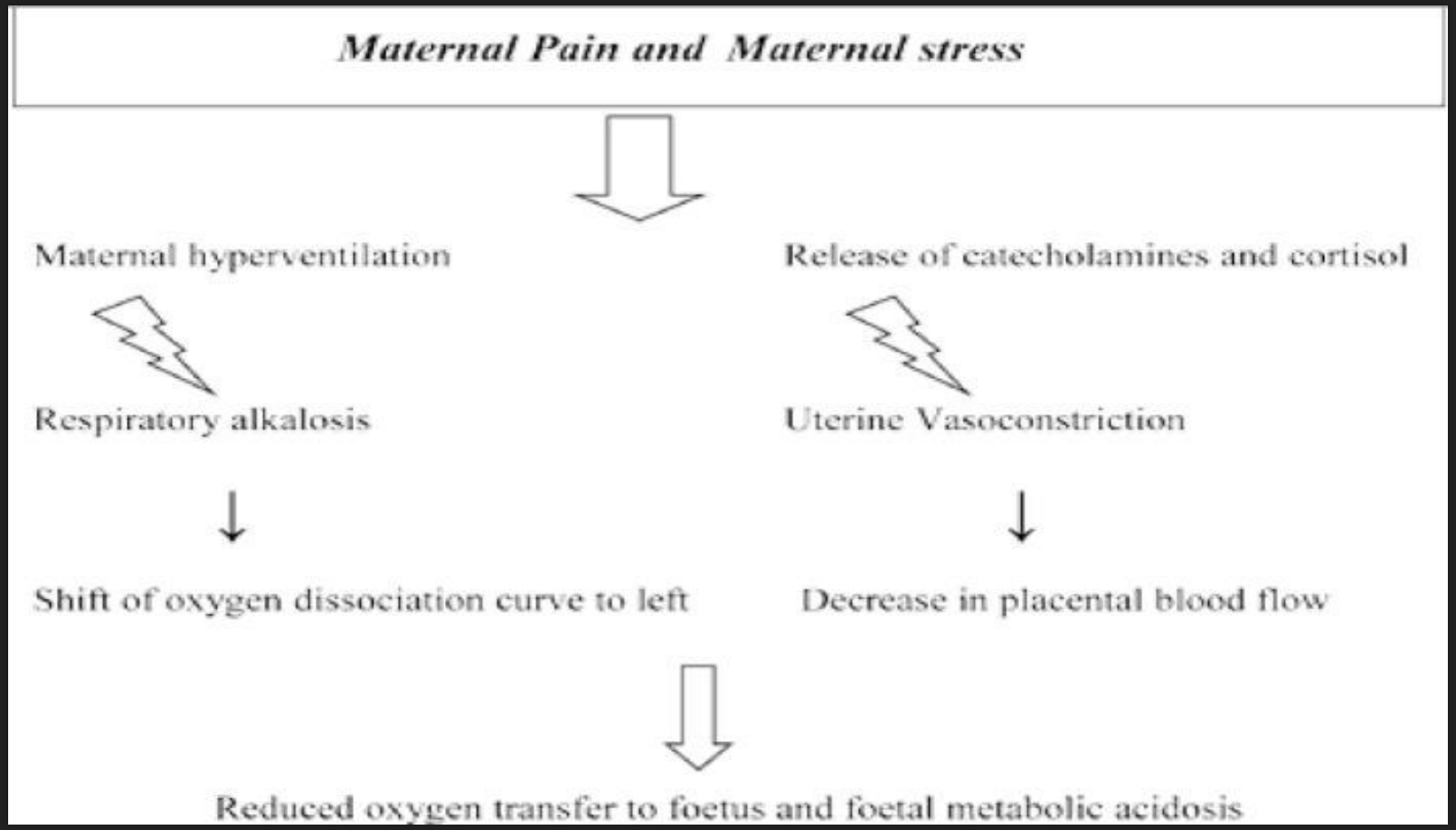
Maternal Pain and Maternal stress
Maternal hyperventilation
Release of catecholamines and cortisol
Respiratory alkalosis
Uterine Vasoconstriction
Shift of oxygen dissociation curve to left
Decrease in placental blood flow
Reduced oxygen transfer to foetus and foetal metabolic acidosis

STAGES OF LABOUR:

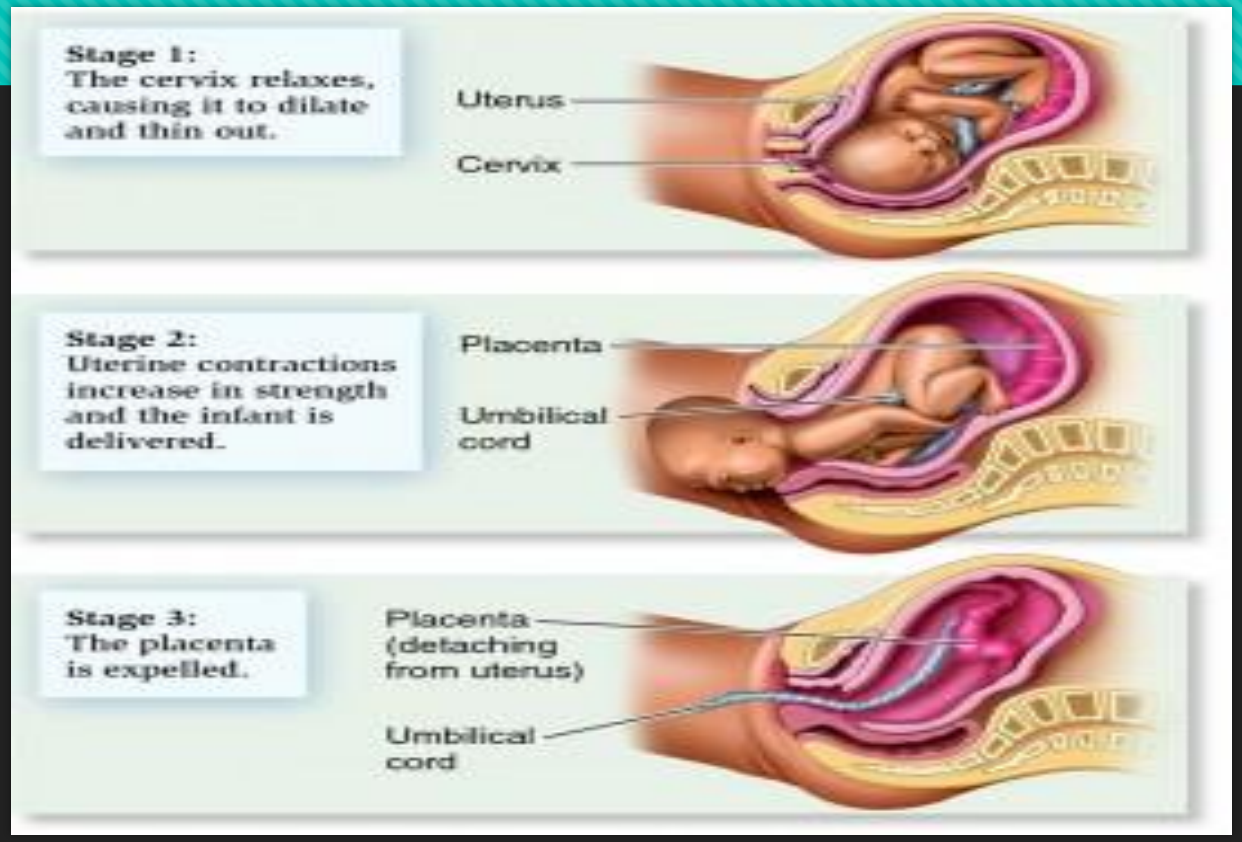

First Stage of Labor

The first stage of labor begins when labor starts and ends with full cervical dilation to 10 centimeters. Although precisely determining when labor starts may be inexact, labor is generally defined as beginning when contractions become strong and regularly spaced at approximately 3 to 5 minutes apart

Women may experience painful contractions throughout pregnancy that do not lead to cervical dilation or effacement, referred to as false labor.

The first stage of labor is further subdivides into two phases, defined by the degree of cervical dilation. The latent phase is commonly defined as the 0 to 6 cm, while the active phase commences from 6 cm to full cervical dilation. The presenting fetal part also begins the process of engagement into the pelvis during the first stage.

- Cervical effacement refers to the cervical length in the anterior-posterior plane. When the cervix is completely thinned out, and no length is left, this is referred to as 100 percent effacemen.

- The first stage of labor contains a latent phase and an active phase. During the latent phase, the cervix dilates slowly to approximately 6 centimeters. The latent phase is generally considerably longer and less predictable with regard to the rate of cervical change than is observed in the active phase.
- A normal latent phase can last up to 20 hours and 14 hours in nulliparous and multiparous women, respectively, without being considered prolonged.
- Sedation can increase the duration of the latent phase of labor.
- The cervix changes more rapidly and predictably in the active phase until it reaches 10 centimeters and cervical dilation and effacement are complete. Active labor with more rapid cervical dilation generally starts around 6 centimeters of dilation. During the active phase, the cervix typically dilates at a rate of 1.2 to 1.5 centimeters per hour. Multiparas, or women with a history of prior vaginal delivery, tend to demonstrate more rapid cervical dilation.

- The absence of cervical change for greater than 4 hours in the presence of adequate contractions or six hours with inadequate contractions is considered the arrest of labor and may warrant clinical intervention.[7]

- The second stage of labor commences with complete cervical dilation to 10 centimeters and ends with the delivery of the neonate.
- After cervical dilation is complete, the fetus descends into the vaginal canal with or without maternal pushing efforts. The fetus passes through the birth canal via 7 movements known as the cardinal movements. These include engagement, descent, flexion, internal rotation, extension, external rotation, and expulsion.

- In women who have delivered vaginally previously, whose bodies have acclimated to delivering a fetus, the second stage may only require a brief trial, whereas a longer duration may be required for a nulliparous female. In parturients without neuraxial anesthesia, the second stage of labor typically lasts less than three hours in nulliparous women and less than two hours in multiparous women.
- In women who receive neuraxial anesthesia, the second stage of labor typically lasts less than four hours in nulliparous women and less than three hours in multiparous women.
-

2PHASES OF STAGE 1

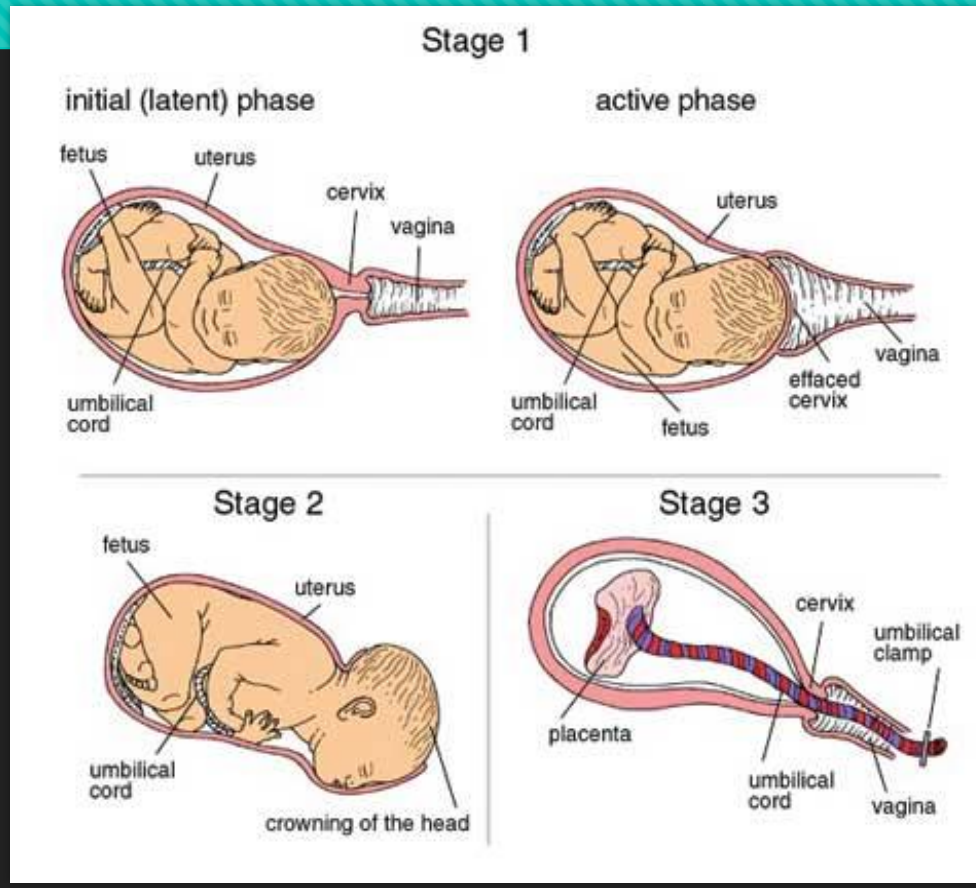

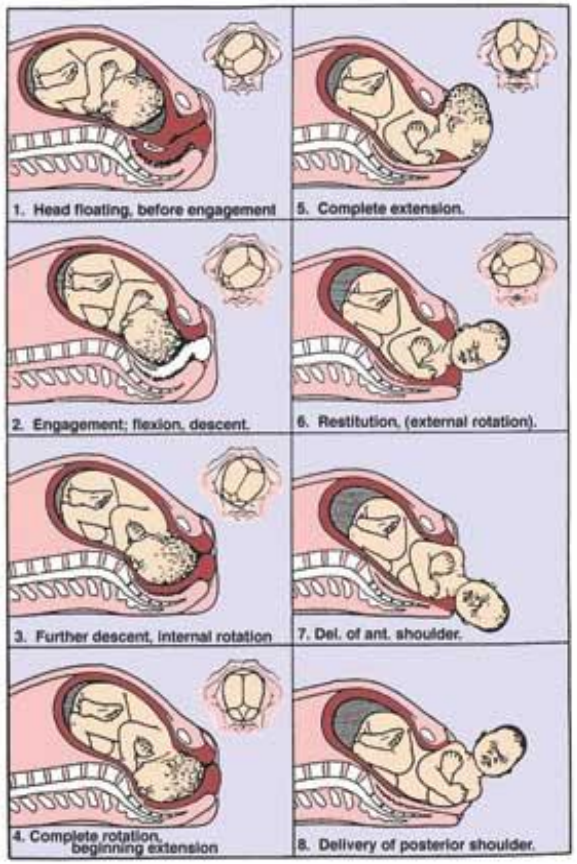

Third Stage of Labor

- The third stage of labor commences when the fetus is delivered and concludes with the delivery of the placenta.
- Separation of the placenta from the uterine interface is hallmarked by three cardinal signs, including a gush of blood at the vagina, lengthening of the umbilical cord, and a globular shaped uterine fundus on palpation.
- Spontaneous expulsion of the placenta typically takes between 5 to 30 minutes.
- A delivery time of greater than 30 minutes is associated with a higher risk of postpartum hemorrhage and may be an indication for manual removal or other intervention.
- Management of the third stage of labor involves placing traction on the umbilical cord with simultaneous fundal pressure to effect faster placental delivery.

Mechanisms of Labour Pain

- Labour is the active process of delivering a foetus and is characterised by regular, painful uterine contractions which increase in frequency and intensity.
- The pain of labour has two components:

- **visceral and somatic**, and its anatomy is well documented.
- The **cervix** has a central role in both the first and second stage of labour.

Visceral pain

Visceral labour pain occurs during the **early first stage and the second stage of childbirth**.

With each uterine contraction, pressure is transmitted to the cervix causing stretching and distension and activating excitatory nocioceptive afferents. These afferents innervate the endocervix and lower segment from T10 – L1.

Well documented physiological knowledge provides the basis for explaining the two components of labour pain

- **Visceral pain**
- Visceral pain is transmitted by small unmyelinated 'C' fibres which travel with sympathetic fibres and pass through the uterine, cervical and hypogastric nerve plexuses into the main sympathetic chain. The pain fibres from the sympathetic chain enter the white rami communicantes associated with T10 to L1 spinal nerves and pass via their posterior nerve roots to synapse in the dorsal horn of the spinal cord. Some fibres cross over at the level of the dorsal horn with extensive rostral and caudal extension resulting in poorly localised pain. Chemical mediators involved include bradykinin, leukotrienes, prostaglandins, serotonin, substance P and lactic acid.

- The pain of early labour is referred to T10-T12 dermatomes such that pain is felt in the lower abdomen, sacrum and back. This pain is dull in character and is not always sensitive to opioid drugs; the response to opioids depends on the route of administration.

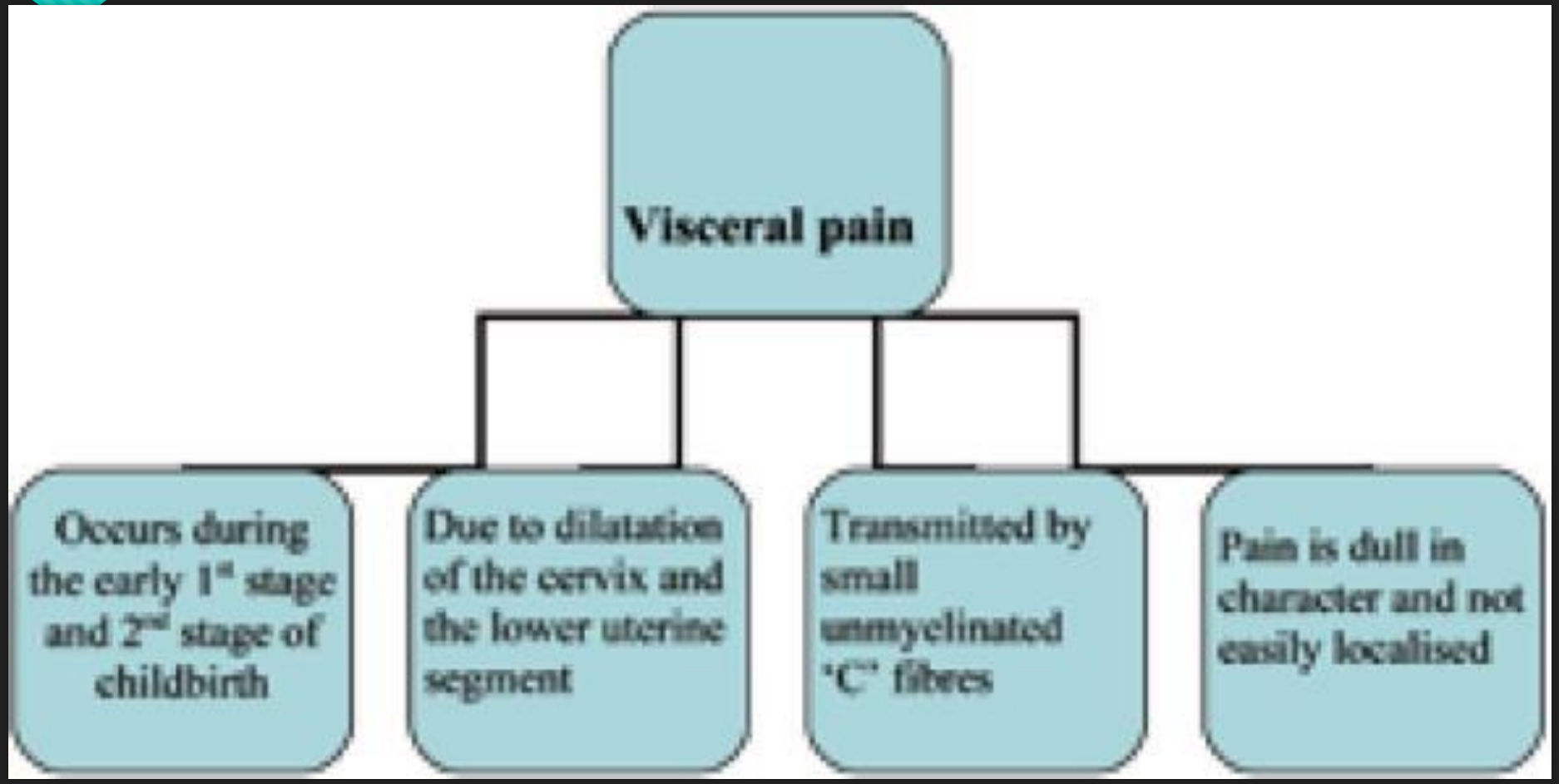
Visceral pain
Occurs during the early 1st stage and 2nd stage of childbirth
Due to dilatation of the cervix and the lower uterine segment
Transmitted by small unmyelinated 'C' fibres
Pain is dull in character and not easily localised

SOMATIC PAIN

Somatic pain is transmitted by fine, myelinated rapidly transmitting 'A delta' fibres. Transmission occurs via the pudendal nerves and perineal branches of the posterior cutaneous nerve of the thigh to S2 - S4 nerve roots. Somatic fibres from the cutaneous branches of the ilioinguinal and genitofemoral nerves also carry afferent fibres to L1 and L2.

- Somatic pain occurs closer to delivery, is sharp in character and easily localised to the vagina, rectum and perineum. It radiates to the adjacent dermatomes T10 and L1 and compared to visceral pain, is more resistant to opioid drugs.
- All resulting nerve impulses (visceral and somatic) pass to dorsal horn cells where they are processed and transmitted to the brain via the spino-thalamic tract. Transmission to the hypothalamic and limbic systems accounts for the emotional and autonomic responses associated with pain

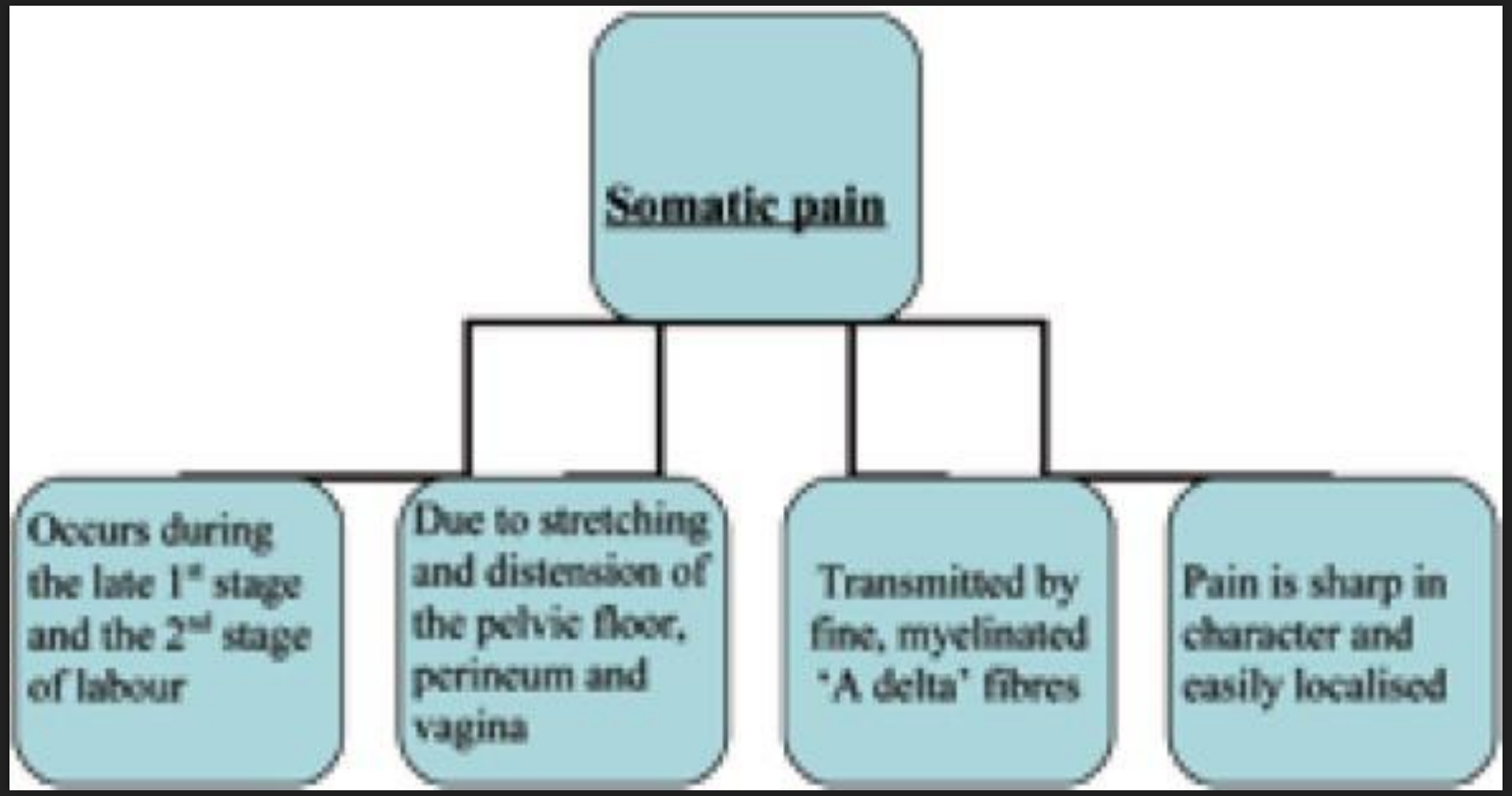
Somatic pain
Occurs during the late 1st stage and the 2nd stage of labour
Due to stretching and distension of the pelvic floor, perineum and vagina
Transmitted by fine, myelinated 'A delta' fibres
Pain is sharp in character and easily localised

SOMATIC PAIN

This occurs in addition to the visceral pain described above, in the **late first stage of labour** and also in the **second stage**

It arises due to afferents that innervate the vaginal surface of the cervix, perineum and vagina and occurs as a result of stretching, distension, ischaemia and injury (tearing or iatrogenic) of the pelvic floor, perineum and vagina. It manifests during descent of the foetus and during this active stage, the uterus contracts more intensely in a rhythmic and regular manner.

- **The intensity of labour pain increases with greater cervical dilatation and correlates well with the intensity, duration and frequency of uterine contractions.**

Obstetric Pain Pathway

- First Stage
  - Pain from lower uterine and cervix changes
  - Visceral Afferent Nerve fibers
  - T10-L1 Segments
- Second Stage
  - Pain from distension of pelvic floor, vagina, and perineum
  - Somatic Nerve fibers
  - S2-S4 Segments