BASICS OF ULTRASOUND IMAGING FOR NERVE BLOCKS

SR.ENTEZARY. MD,
Anesthesiologist, Pain Fellowship
Department of Anesthesiology & Pain Medicine
IUMS
ISRAPM

- Ultrasound wave frequency > 20 KHz and medical ultrasound commonly is in the 2.5-15 MHz range.

- An ultrasound wave is generated when an electric field is applied to an array of piezoelectric crystals located on the transducer surface.

- Ultrasound waves are generated in pulses (intermittent trains of pressure waves) and each pulse commonly consists of 2 or 3 sound cycles of the same frequency.

- The pulse length (PL) is the distance traveled per pulse.

- The transducer waits to receive the returning wave (i.e. echo) after each pulsed wave.

- The conversion of sound to electrical energy is called the piezoelectric effect (Pierre Currie 1880).

- The image can be displayed in a number of modes:
- 1) Amplitude (A) mode
- 2) Brightness (B) mode
- 3) Motion (M) mode
- Among the 3 modes, the B mode is most commonly used for ultrasound guided regional anesthesia.

Ultrasound Machine

- **There are 5 basic components:**
- **Pulser** - applies high amplitude voltage to energize the crystals
- **Transducer** - converts electrical energy to mechanical (ultrasound) energy and vice versa
- **Receiver** - detects and amplifies weak signals
- **Display** - displays ultrasound signals in a variety of modes
- **Memory** - stores video display

Advantages of Ultrasound

- Reveals the nerve location.
- Real-time image during needling.
- Images the LA spread.
- Improves the quality, the onset time, success rate compared to NS techniques.??
- Reduces the number of needle attempts.
- Differentiates extravascular from intravascular injection.
- Differentiates extraneural from intraneural injection.

Limitations of Peripheral Nerve Stimulation Techniques

- PNS guidance is useful only when a motor response is elicited.
- NS provides objective but indirect evidence of nerve location.
- Evidence of proper needle placement (i.e. motor response) disappears after injection of 1-2 mL of LA
- Motor response achieved at >0.5 mA does not guarantee a successful or complete block.
- PNS does not prevent intravascular, intraneural or pleural puncture.

Tissue Echogenicity

When an echo returns to the transducer, its amplitude is represented by the degree of brightness (i.e. echogenicity) of a dot on the display. Combination of all the dots forms the final image.

HYPERECHOIC TISSUE

Strong specular reflections give rise to bright dots **(hyperechoic)** e.g., diaphragm, gallstone, bone, pericardium.

HYPOECHOIC TISSUE

- Weaker diffuse reflections produce grey dots **(hypoechoic)** e.g., solid organs.

- Also deep structures appear **hypoechoic** because attenuation limits beam transmission to reach the structures, resulting in a weak returning echo.

ANECHOIC TISSUE

No reflection produces dark dots **(anechoic)** e.g., fluid and blood filled structures because the beam passes easily through these structures without significant reflection

TISSUE	ULTRASOUND IMAGE FOR REGIONAL ANESTHESIA
Veins	*anechoic (compressible)*
Arteries	*anechoic (pulsatile)*
Fat	*hypoechoic with irregular hyperechoic lines*
Muscles	*heterogeneous (mixture of hyperechoic lines within a hypoechoic tissue background)*
Tendons	*predominantly hyperechoic*
Bone	*++ hyperechoic lines with a hypoechoic shadow*
Nerves	*hyperechoic / hypoechoic*

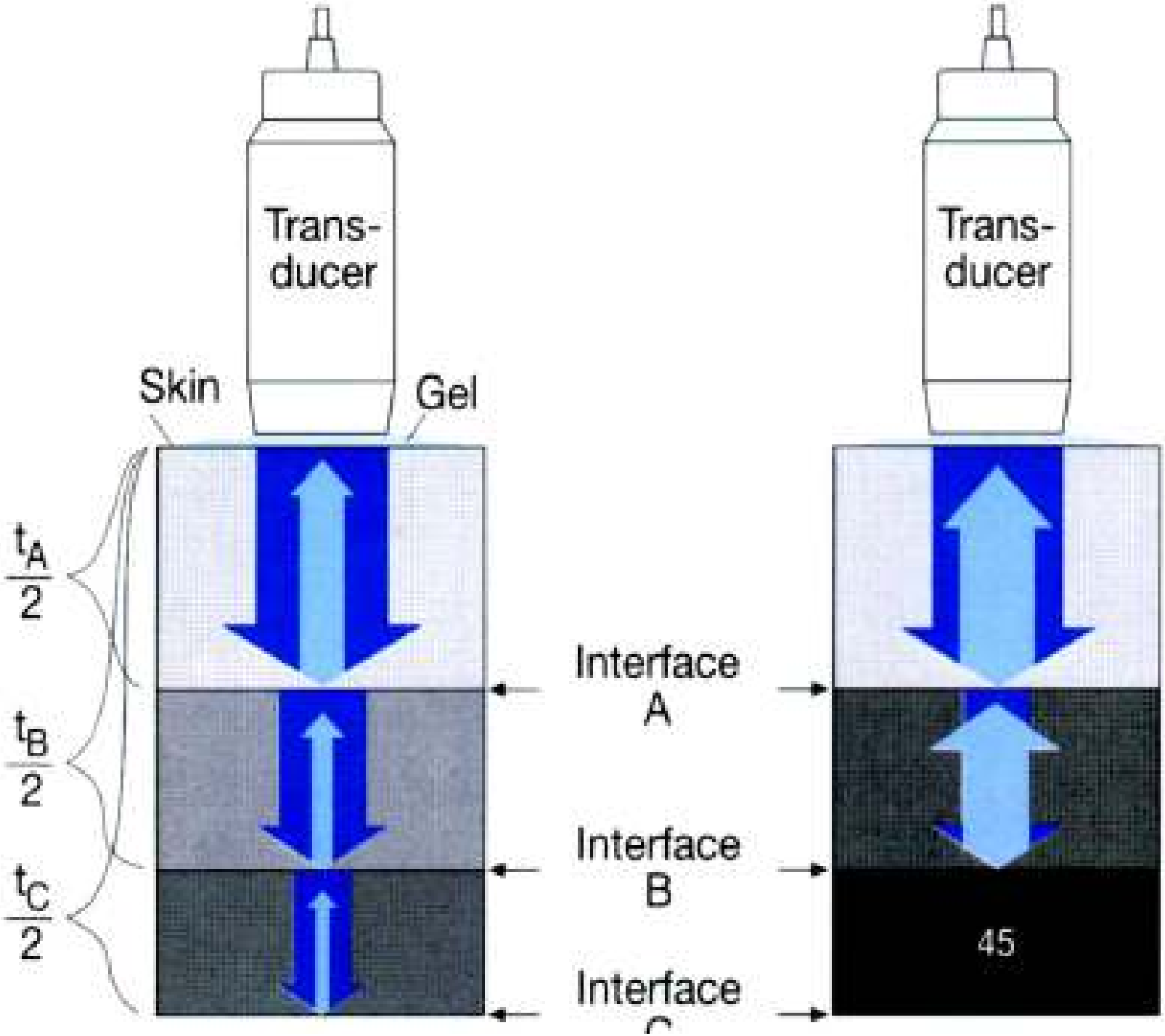
Trans-
ducer
Skin
Gel
$\frac{t_A}{2}$
$\frac{t_B}{2}$
$\frac{t_C}{2}$
Interface
A
Interface
B
Interface
C
Trans-
ducer
45

ANISOTROPY

- Anisotropy refers to a change in echogenicity of tissues (e.g., tendon and nerve) as a result of transducer angle.

- A hyperechoic nerve structure can appear hypoechoic when the angle of incidence is changed from 90 degrees to 45 degrees

Image Resolution

- Resolution is the ability of the ultrasound machine to distinguish two structures (reflectors or scatterers) that are close together as separate.

- Spatial resolution is influenced by **axial** and **lateral** resolution, both of which are closely related to ultrasound frequency.

Axial Resolution

- **Axial resolution** refers to the ability to distinguish two structures that lie along the axis (i.e. parallel) of the ultrasound beam as separate and distinct.
- Axial resolution is determined by the **pulse length**. A high frequency wave with a short pulse length will yield better axial resolution than a low frequency wave.

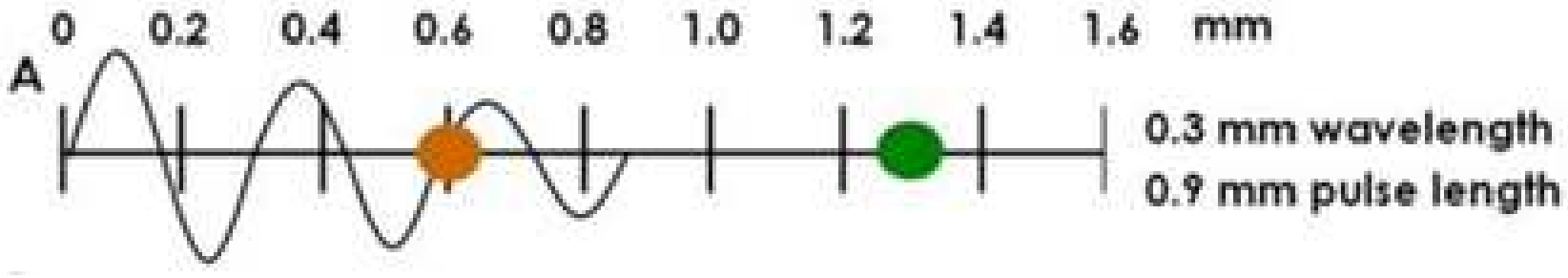

a 5 MHz transducer generates ultrasound waves that travel 0.3 mm per cycle (wavelength = 0.3 mm = speed of sound / frequency = 1,540 m/sec divided by 5 x 106 cycles/sec). The pulse length is the distance traveled by one echo (3 cycles in this case). As seen in figure A, a 5 MHz transducer (wavelength = 0.3 mm and pulse length = 0.9 mm; 3 cycles), the axial resolution is sufficient to distinguish the 2 target objects as separate because the incident wave hits target # 1 (brown) before hitting target # 2 (green).

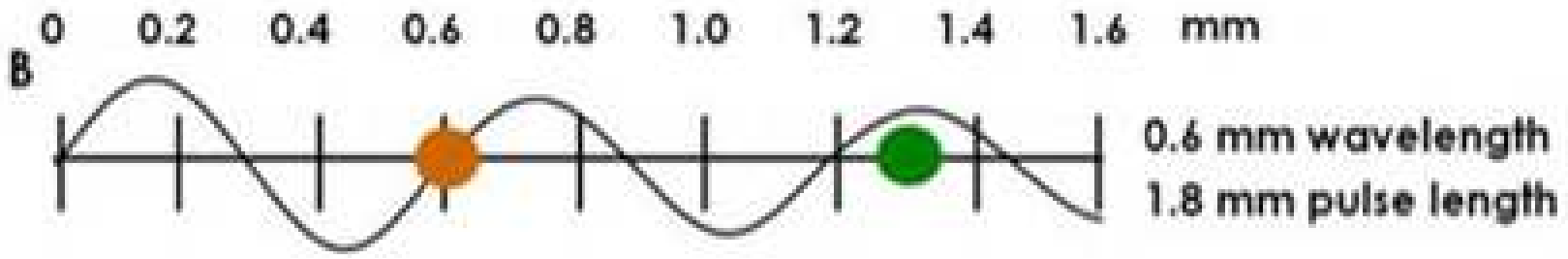

with a 2.5 MHz transducer (wavelength = 0.6 mm and pulse length = 1.8 mm; 3 cycles), the axial resolution is no longer adequate. Because both target # 1(brown) and target # 2 (green) are hit by the same wave, both target objects are seen as one.

LATERAL RESOLUTION

- **Lateral resolution** refers to resolution of objects lying side by side. Lateral resolution is directly related to the transducer **beam width**, which in turn is inversely related to the ultrasound frequency. A high frequency transducer emits a wave with a short wavelength and a small beam width. Lateral resolution is poor when the 2 structures lying side by side are located within the same beam width.

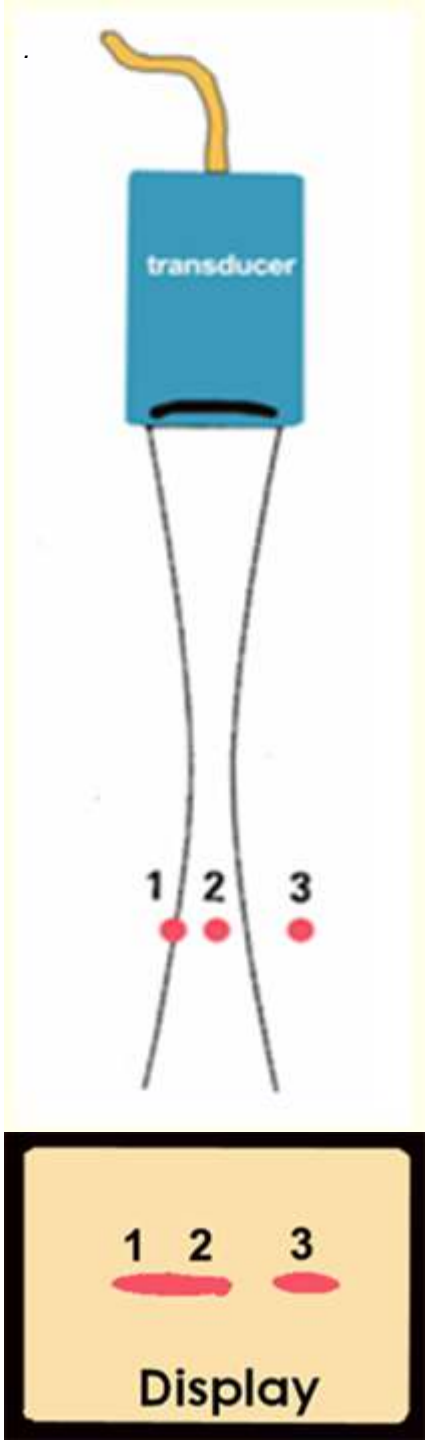

The beam width can be further reduced by adjusting the **focal zone** (FZ). Lateral resolution is the best at the FZ, where the beam is narrowest. It is therefore clinically useful to focus the target structure within the focal zone to yield the best possible lateral resolution. The beam is known to diverge (increased beam width) as it propagates deep into the far field.

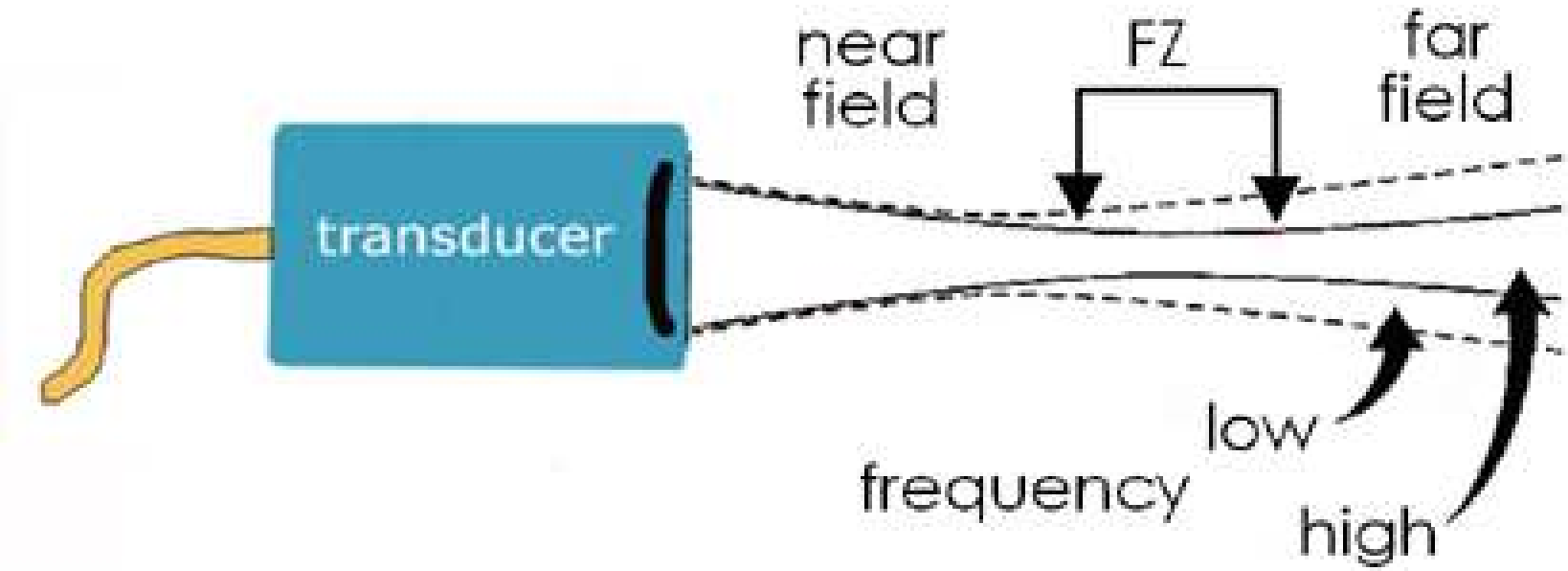

A high frequency beam has a narrower beam width.

COLOR DOPPLER

- Color Doppler is an instrument to characterize blood flow. The Doppler effect occurs when there is a moving source (flow of RBCs) and a stationary listener (ultrasound transducer).
- If the source (RBC) is moving **towards** the receiver (transducer), the perceived frequency is **HIGHER** (display in **RED**) and when the source is moving **away** from the receiver, the perceived frequency is **LOWER** than the actual (display in **BLUE**).

COLOR DOPPLER

- It is important to note that Color Doppler detection of flow and flow direction is worst when the transducer is perpendicular (90 degrees) to the vessel and best when the transducer is parallel (0 degrees) to the blood flow.

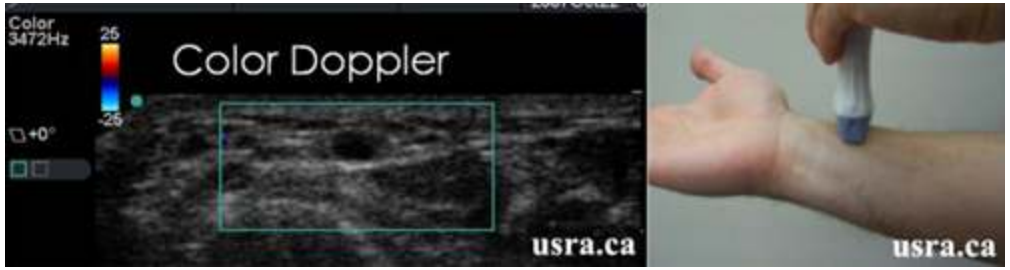

Transducer perpendicular to radial artery (no flow is detected)

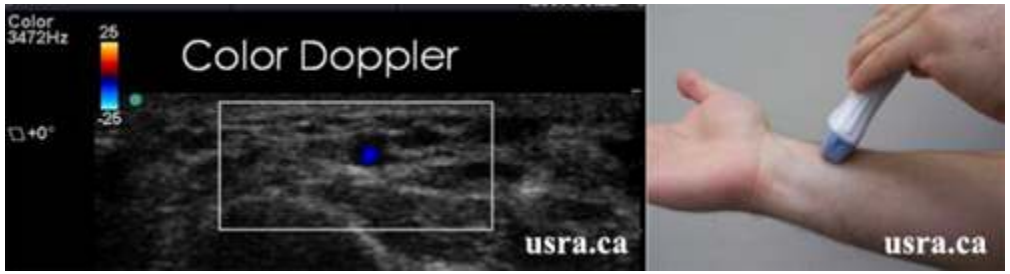

Transducer aiming away from artery (flow in BLUE)

Transducer aiming towards artery (flow in RED)

For ultrasound guided regional anesthesia, **Color Power Doppler** (CPD) is useful for differentiating vascular from non vascular structures. CPD is more sensitive than Color Doppler in flow detection but does not indicate flow direction.

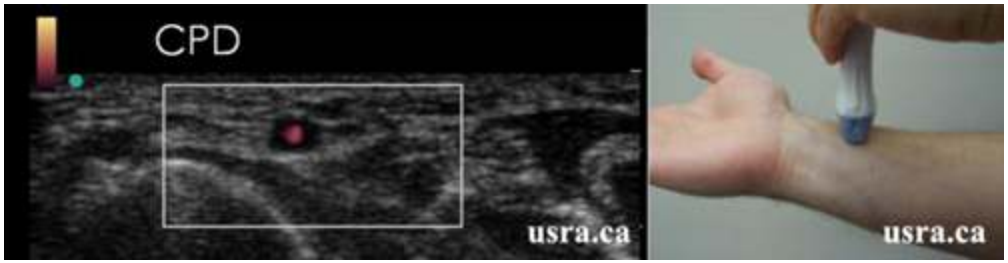

Transducer perpendicular to radial artery (weak flow is detected)

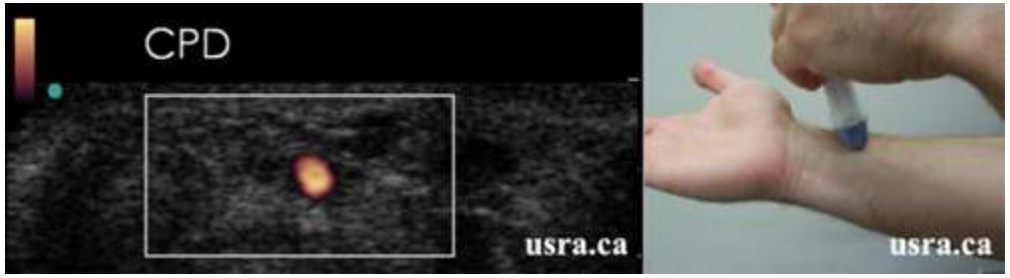

Transducer aiming towards or away from artery (strong flow is detected)

Image Artifacts

- Imaging artifacts are display distortions or errors that may adversely affect image interpretation or acquisition.

- Local heterogeneities in soft tissue can cause artifactual bending of the block needle on ultrasound scans, known as the bayonet artifact

- Bayonet artifacts are commonly observed during the lateral in-plane approach to popliteal block because more adipose tissue is present over the nerves near the posterior midline of the leg (adipose tissue has a slower speed of sound than the adjacent muscle)

Bayonet artifact is observed during popliteal block of the sciatic nerve

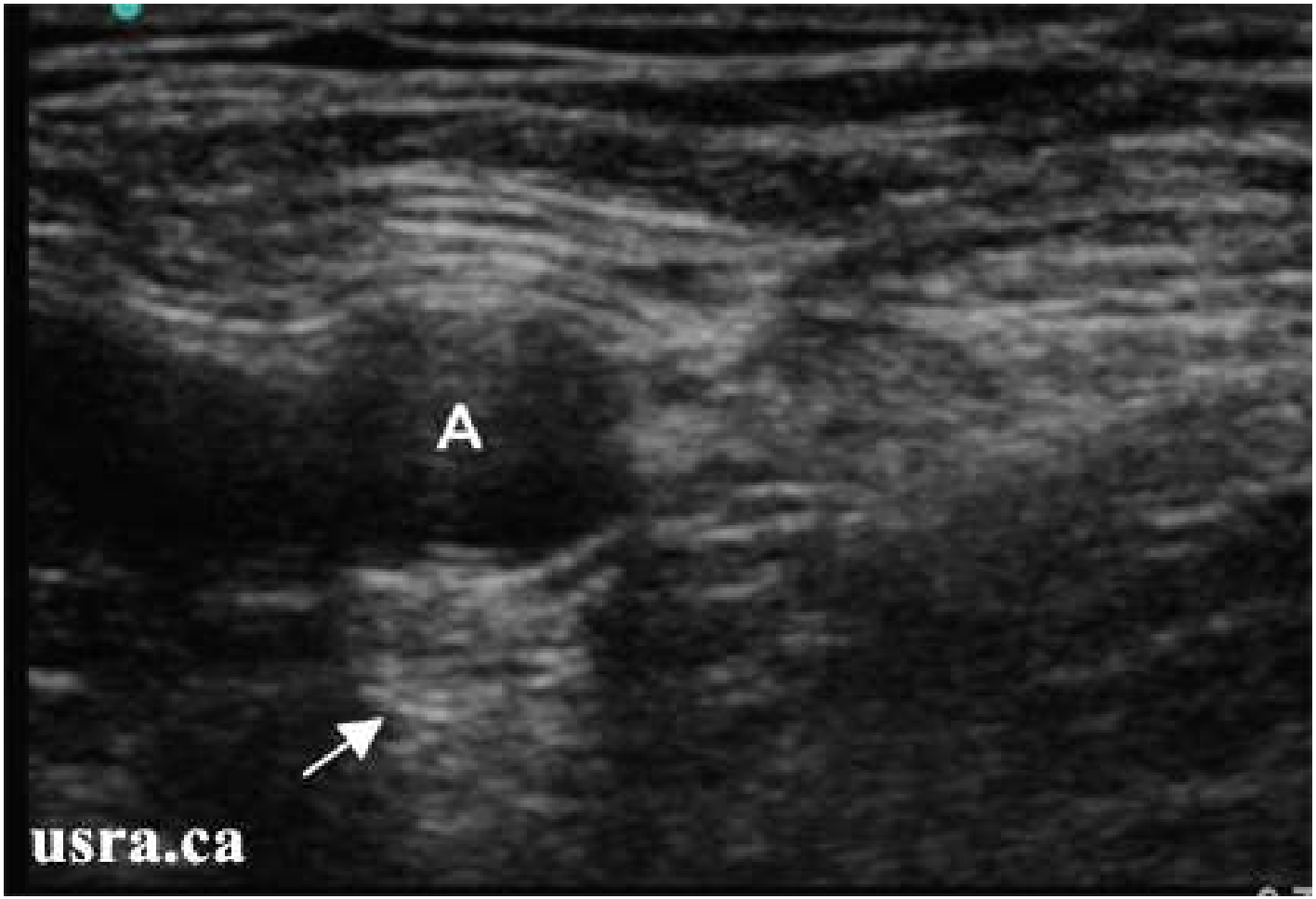

An **acoustic enhancement artifact** (hyperechoic region, arrow) deep to a fluid filled structure (e.g., a vessel, **A** = artery) is the result of beam penetration through an area of low attenuation coefficient to an area of higher attenuation coefficient.

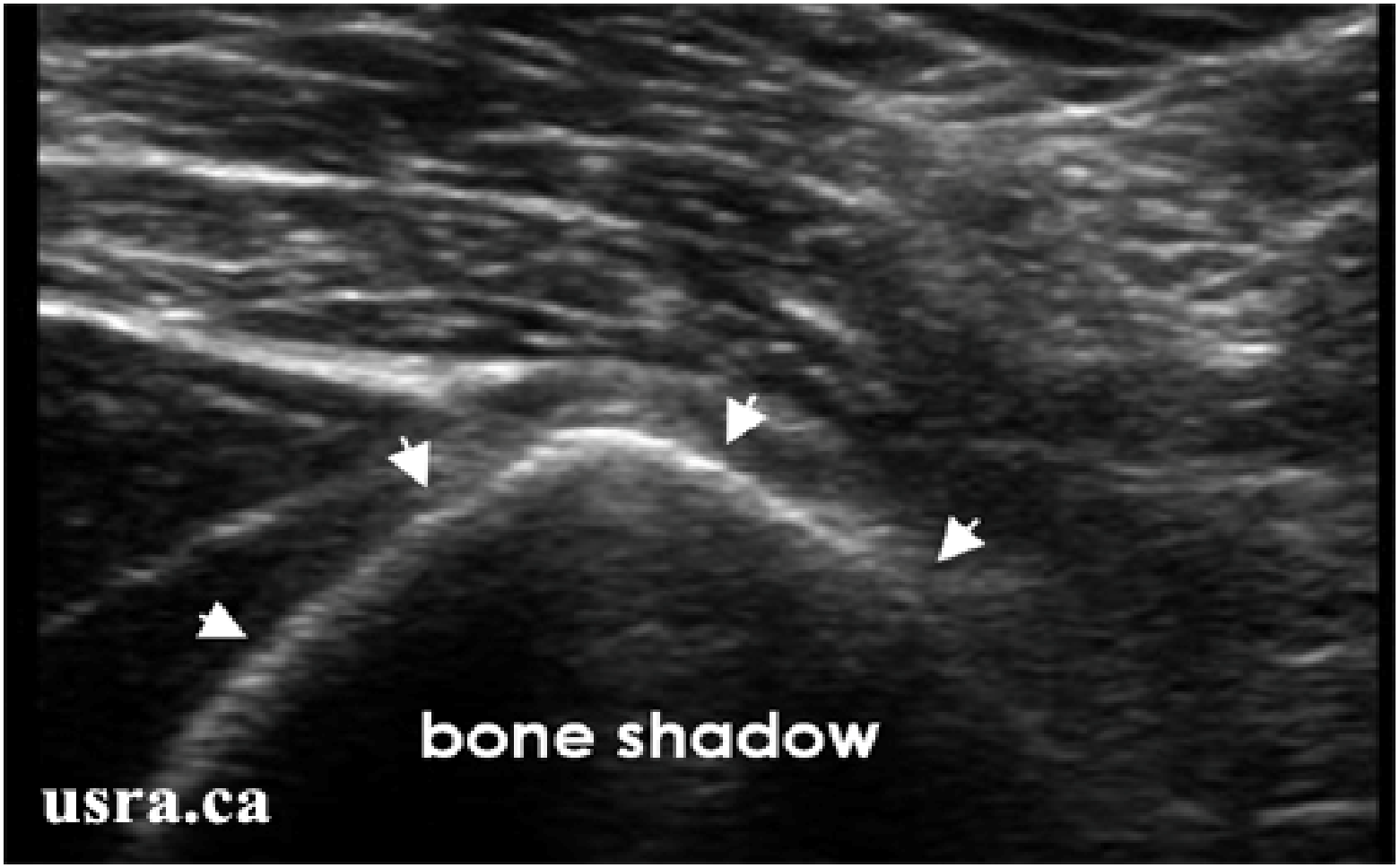

An **acoustic shadow artifact** (**hypoechoic region** = bone shadow) deep to a hyperechoic bone outline (arrows) is the result of beam attenuation when the beam encounters bone with a high attenuation coefficient. Ultrasound beam penetration is severely impeded.

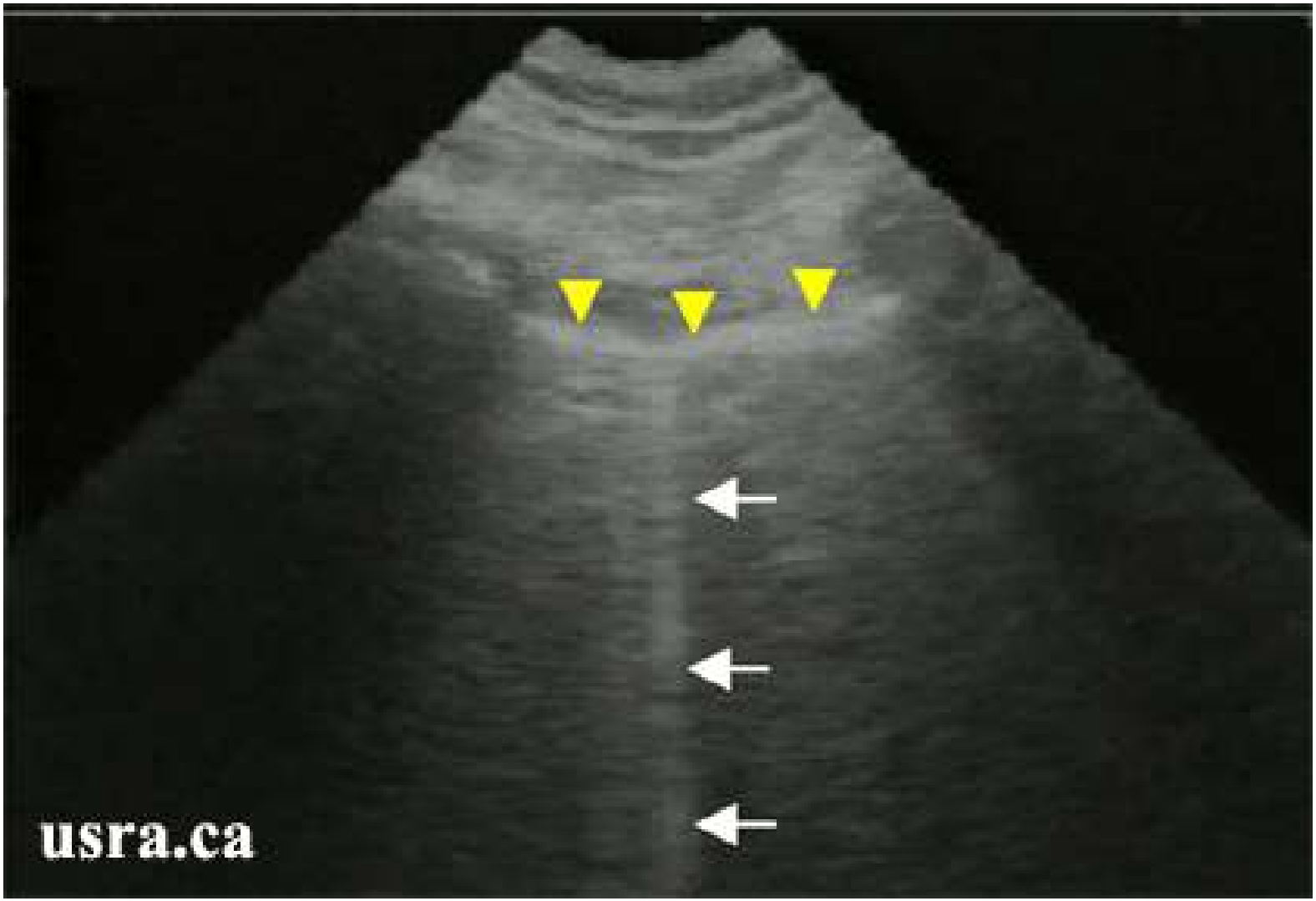

Tissue **reverberation artifacts** are generated by strong specular reflectors e.g., the pleura (yellow arrowheads). Air artifact in the lung results in “comet tail” acoustic signals (arrows) going from the hyperechoic pleural line into the lung parenchyma.

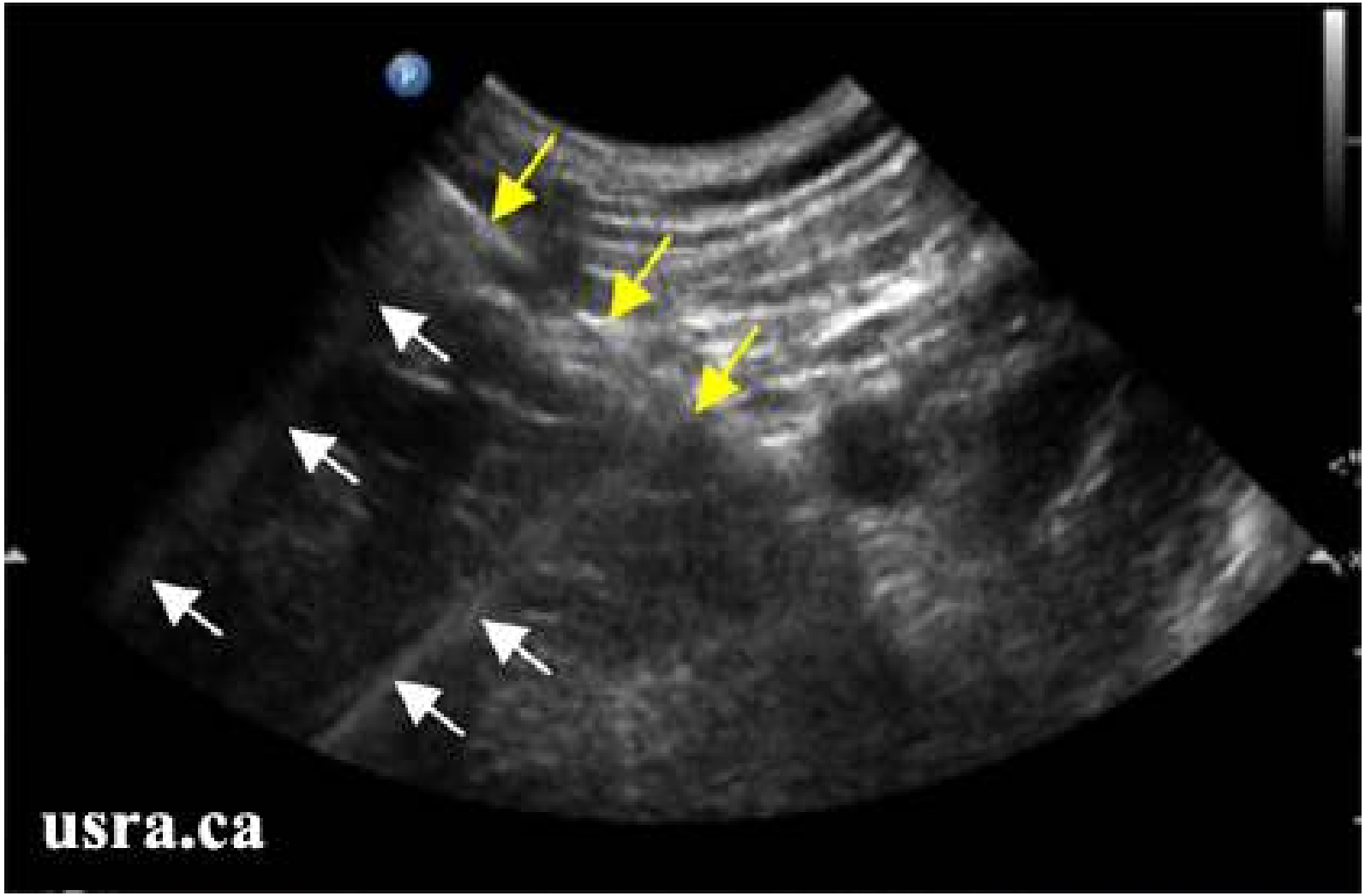

Reverberation artifacts (white arrows) can be seen during needle (yellow arrows) advancement in the infraclavicular region using a curved transducer.

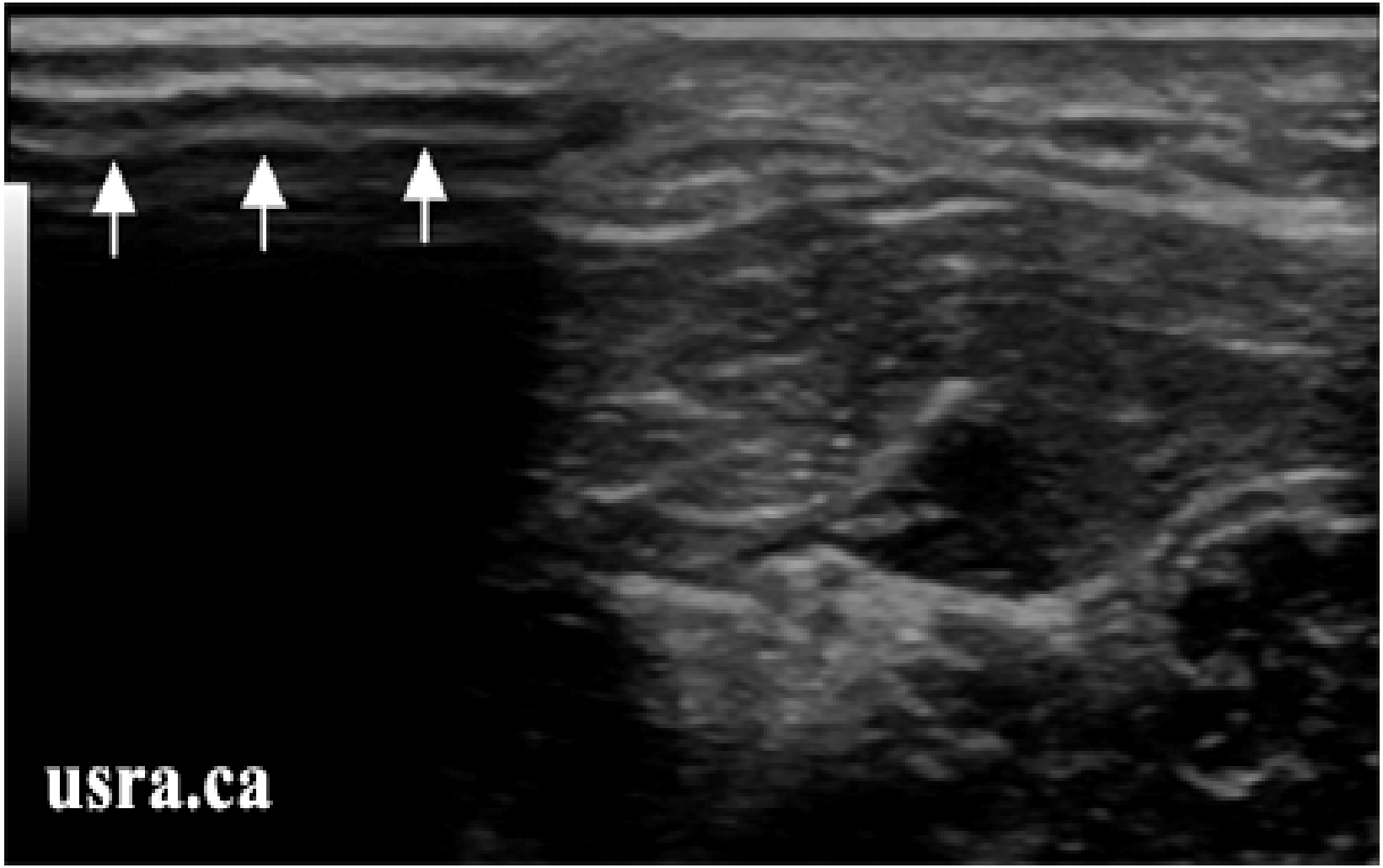

The **air artifact** (arrows) at the transducer skin interface is due to a lack of conductive gel and poor transducer to skin contact. This results in a large dropout artifact.

Transducer Selection

- The transducer frequencies used for peripheral nerve blocks range from 3-15 MHz.

Examples of Transducers

10-5 MHz
38-mm
linear array

10-5 MHz
25-mm
linear array

7-4 MHz
11-mm
curved array

5-2 MHz
60-mm
curved array

Superficial Structures

- For superficial structures (e.g. nerves in the interscalene, supraclavicular and axillary regions), it is ideal to use high frequency transducers greater than or equal to 7 MHz.

- Transducers in the range of 10-15 MHz are preferred but depth of penetration is often limited to 2-3 cm below the skin surface.

Deeper Structures

- For visualization of deeper structures (e.g. in the infraclavicular and popliteal regions), it may be necessary to use a lower frequency transducer (less than or equal to 7 MHz) because it offers ultrasound penetration of 4-5 cm or more below the skin surface.

Linear Vs Curved Transducers

- Linear transducers less than 5 cm wide are available for high frequency transducers. Smaller footprints are useful for detailed scanning where the patient's anatomy prohibits the use of bulkier transducers (e.g., the supraclavicular region.
- Curved transducers are best suited for scanning whenever a wide field of view is required.

Remember that

high frequency = high spatial resolution but limited depth of penetration

low frequency = greater depth of penetration but lower spatial resolution

Frequency and Image Resolution

It is best to select the highest frequency transducer possible for the required depth of penetration.

A higher frequency transducer (10-12 MHz) provides the best image resolution for superficial structures.

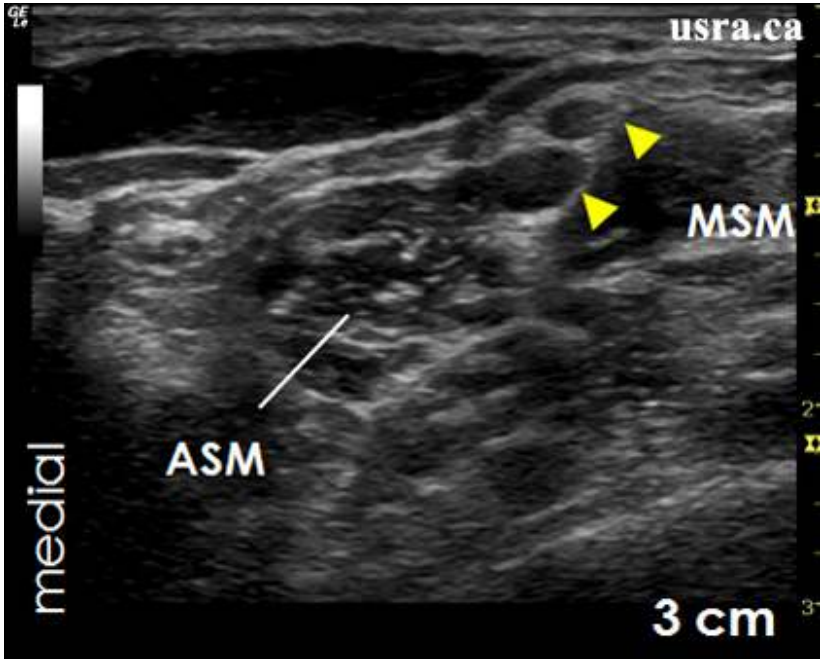

The Brachial Plexus in the Interscalene Groove (1-2 cm from the skin surface)

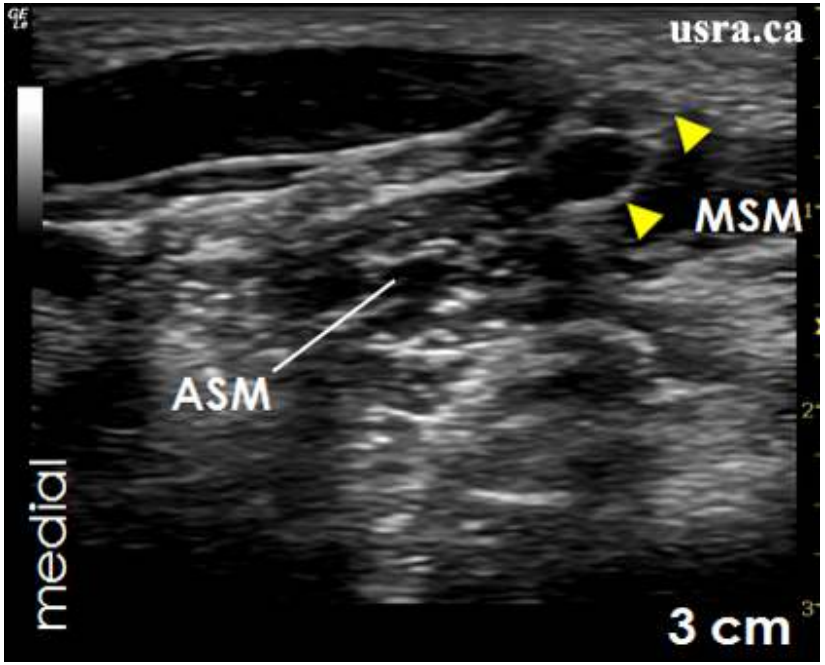

Note that the texture of the anterior scalene muscle(ASM)and middle scalene muscle (MSM) is less clearly defined with the 8 MHz transducer
compared to the 12 MHz transducer. **Arrowheads** = nerve roots

Lower Frequency Transducer

- A lower frequency transducer (< 7 MHz) is required to image deep structures.

- Higher frequency transducers (10-12 MHz) have a limited depth of penetration (< 3-4 cm deep).

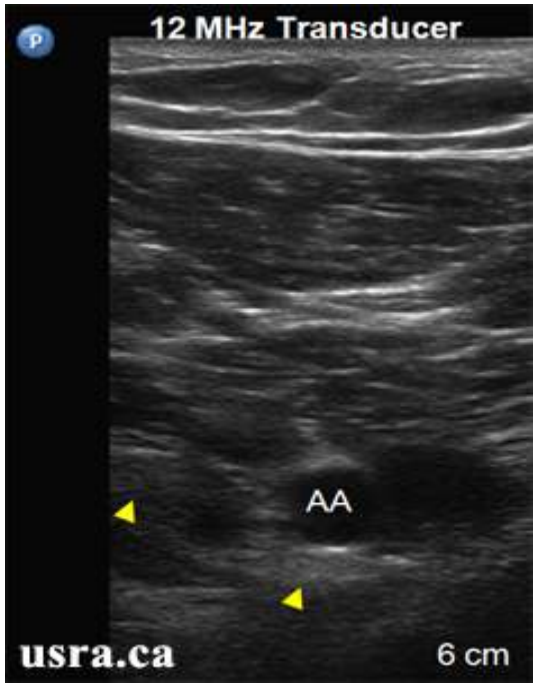

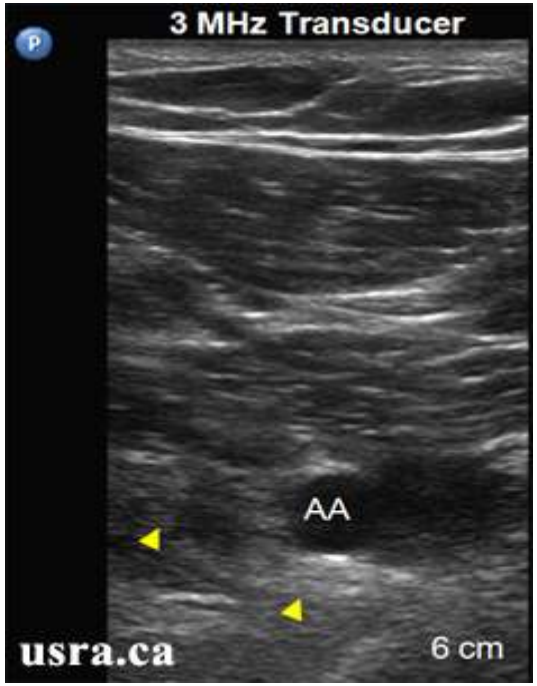

The Brachial Plexus in the Infraclavicular Region (5-6 cm from the skin surface)

The sonograms are captured with a linear 3-12 MHz transducer. The anatomical structures at 5-6 cm deep are not clearly visualized when the transducer is set at 12 MHz. The structures (**AA** = axillary artery; **Arrowheads** = nerves) appear brighter and more clearly defined with the 3 MHz setting. The focus for both images is set at 5-6 cm de

Curvature and Field of View

- The curved transducer provides a wider field of view.

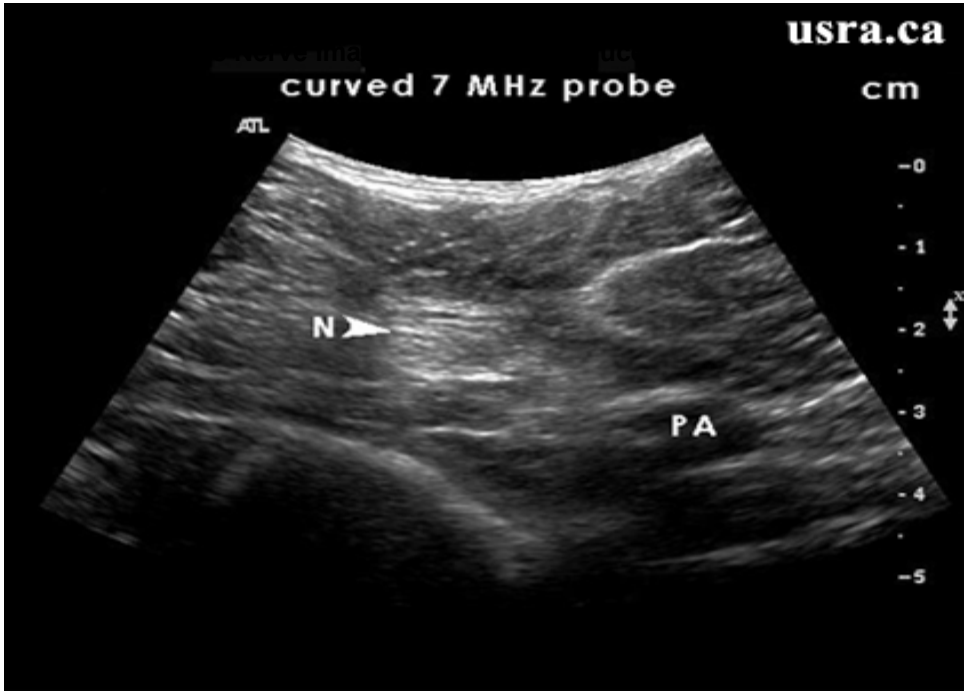

Curved transducer
N = sciatic nerve

PA = popliteal artery

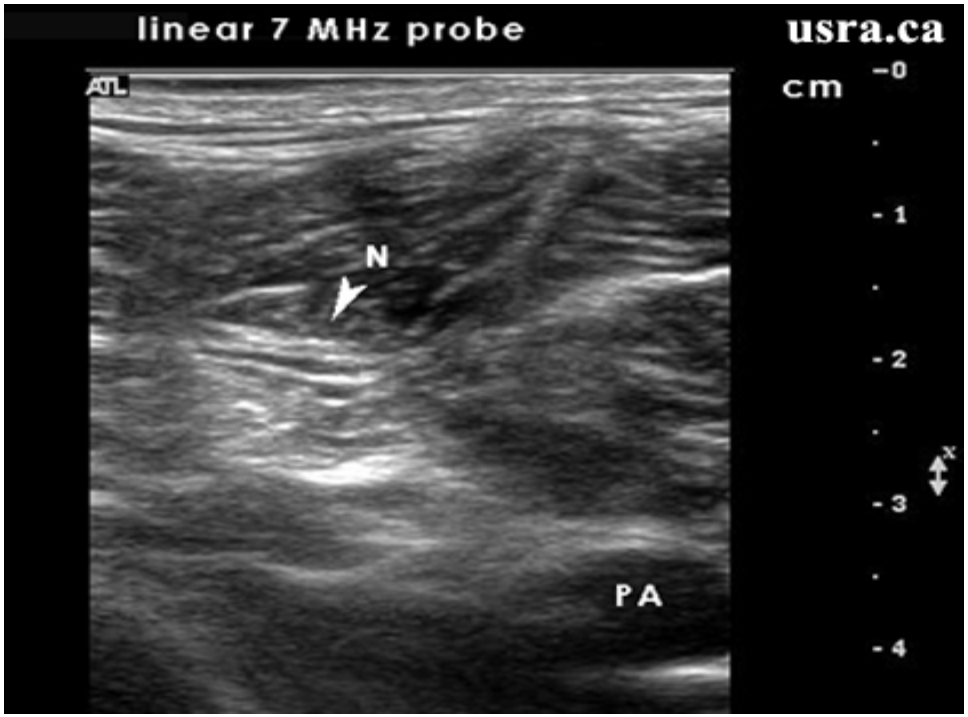

Linear transducer
N = sciatic nerve

PA = popliteal artery

Needle Selection

- Large bore needles (e.g., 17 G) are more readily visualized and easier to direct under ultrasound.
- They are preferred for deep blocks e.g., an infraclavicular block when the angle of needle insertion is steep (> 45 degrees).

Smaller Bore needles

- Smaller bore needles (e.g., 22 G) are more difficult to visualize, but easily visualized for more superficial blocks e.g., the axillary block, when the angle of needle insertion is shallow.

Optimizing Image Quality

Visualization of nerves with ultrasound depends on the operator's ability to properly:

- locate the nerve
- handle the transducer
- maximize the ultrasound machine capability (e.g., the choice of **transducer frequency**, **proper adjustment of depth**, **focus** and **gain** and the use of **compound imaging**)

The Impact of DEPTH Setting on Image Quality

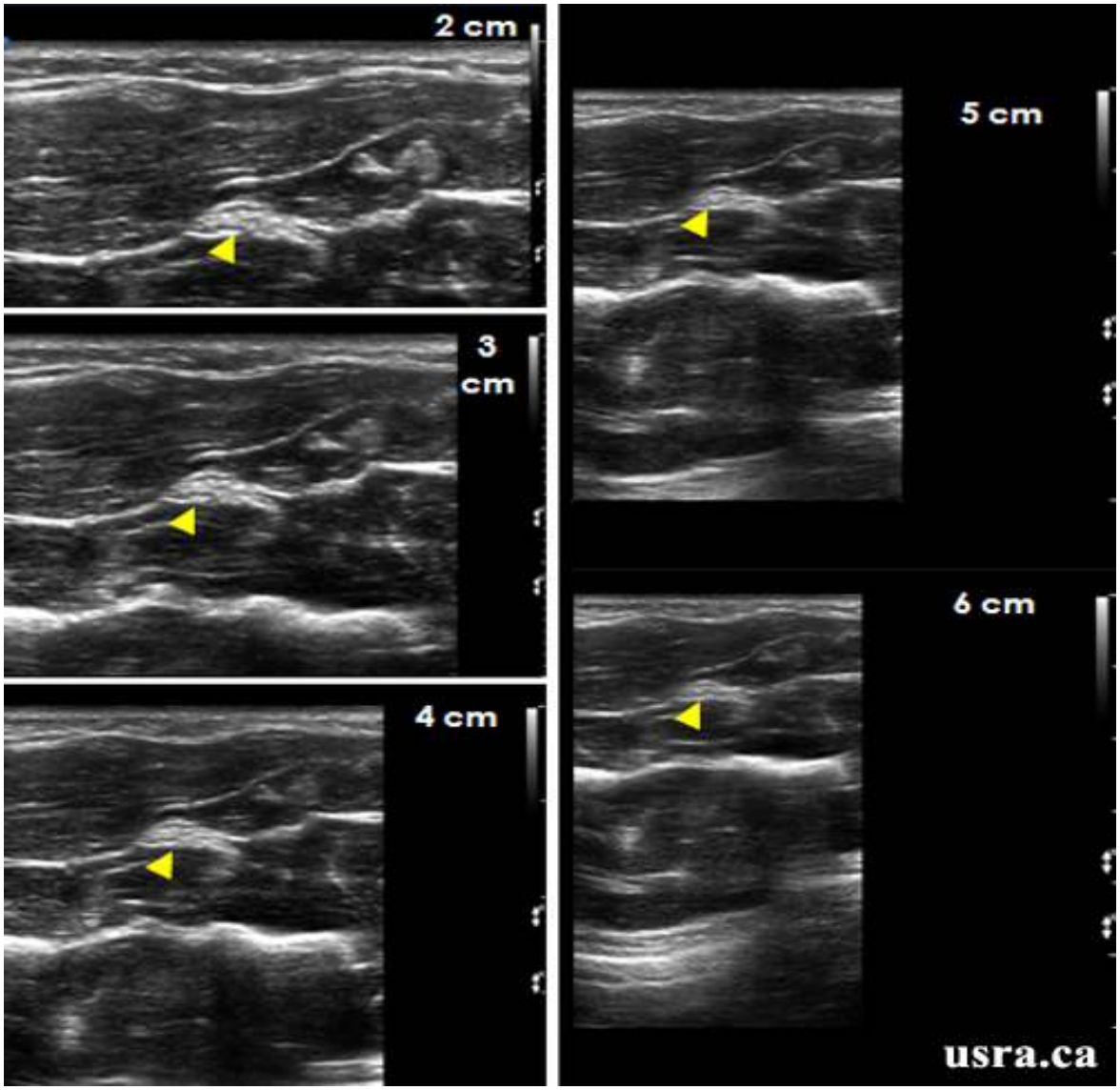

The image of the median nerve in the forearm gets smaller and smaller as the depth is increased from 2-6 cm..

GAIN

- To compensate for attenuation, it is possible to amplify the signal intensity of the returning echo. The degree of receiver amplification is called the **gain**.

- Preferably, the time gain compensation (TGC) is adjusted to selectively amplify the weaker signals returning from deeper structures.

The Impact of GAIN Setting on Image Quality

- The GAIN function compensates for attenuation (amplitude) as sound travels deep into the body.
- The intensity of the returning signals can be amplified by the receiver upon arrival.
- Gain can be adjusted for the near field, far field or the entire field (overall gain).
- Excessive increase in GAIN will add “noise” to the image.

Different Gain Settings

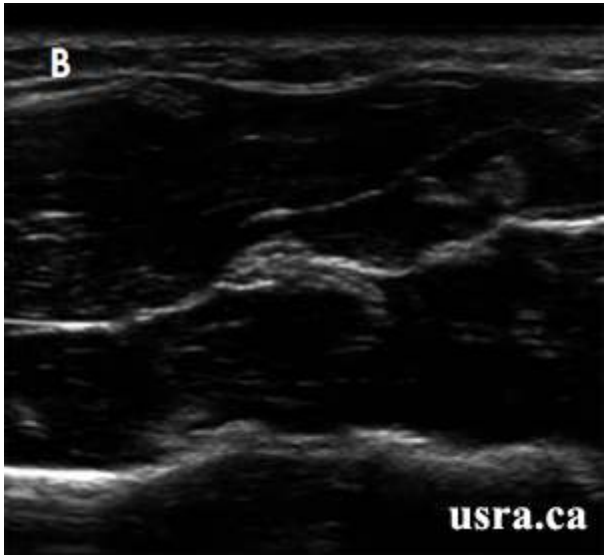

Figure A shows a **proper gain** settings.

Figure B shows **under gain** thus the overall image is very dark. The muscle layers are not well visualized.

Figure C shows **excessive gain** thus the overal image is very bright.

Impact of FOCUS Setting on Image Quality

- Image quality and beam focus is best at the focal zone.
- Most modern electronically steered transducers provide electronic focusing adjustable for depth.
- It is important to place the FOCUS at or slightly below the level of the target structure of interest.

inappropriate focus setting at a superficial level (< 2 cm) resulting in a dark image.
The target structures (**AA** = axillary vessels and **Arrowheads** = cords) are 5-6 cm deep to the skin.

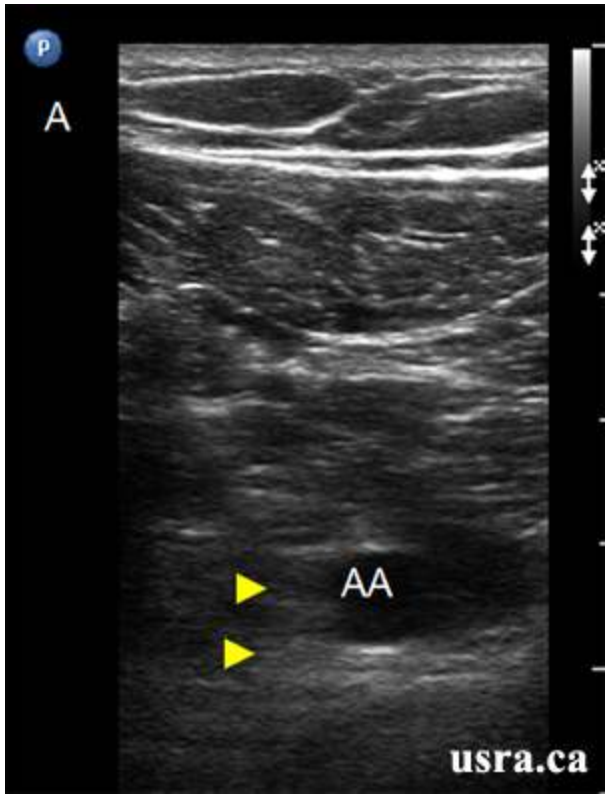

appropriate focus setting at 5-6 cm.
The target structures (**AA** = axillary vessels and **Arrowheads** = cords) are
5-6 cm deep to the skin.

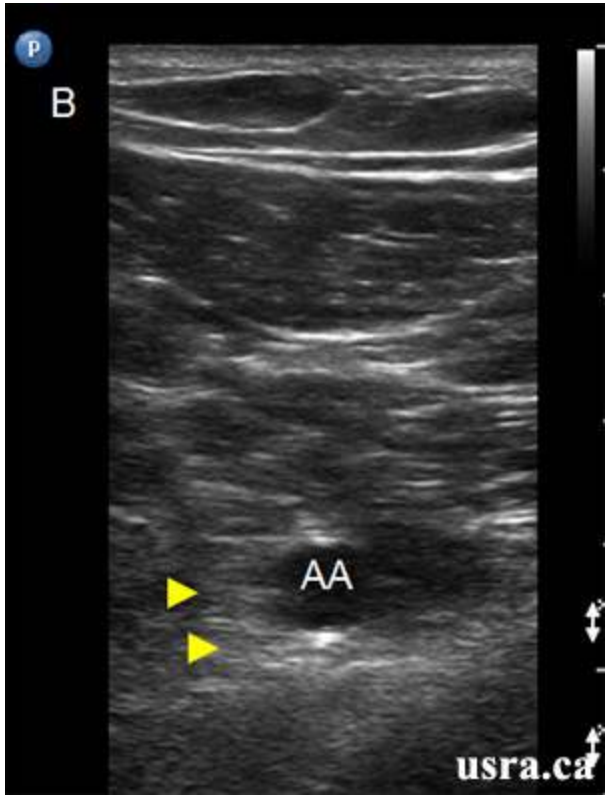

The Impact of COMPOUND IMAGING on Image Quality

- COMPOUND IMAGING is a broad bandwidth technology that combines multiple coplanar images captured from different beam angles and from multiple ultrasound frequency spectra to form a single image in real time.

- Spatial compounding reduces speckle artifacts and improves contrast resolution.

No Compound Imaging

Compound Imaging

Median Nerve in the Forearm (12 MHz Transducer, 3 cm Depth)

Compound Imaging

No Compound Imaging

Supraclavicular Region (10 MHz Transducer, 3 cm Depth)

Cross Beam (Compound Imaging)

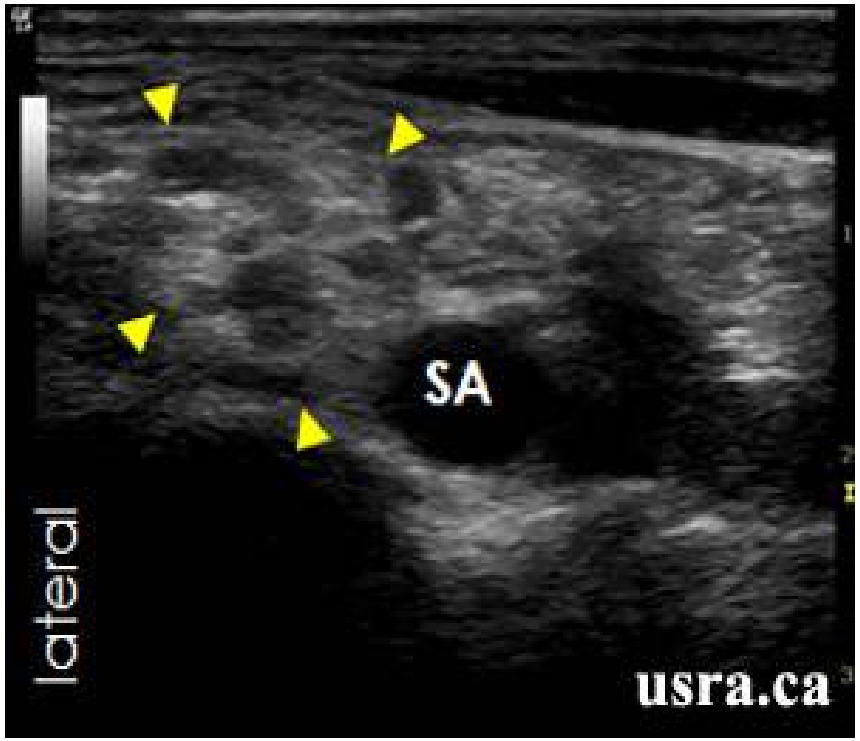

No Cross Beam (No Compound Imaging)

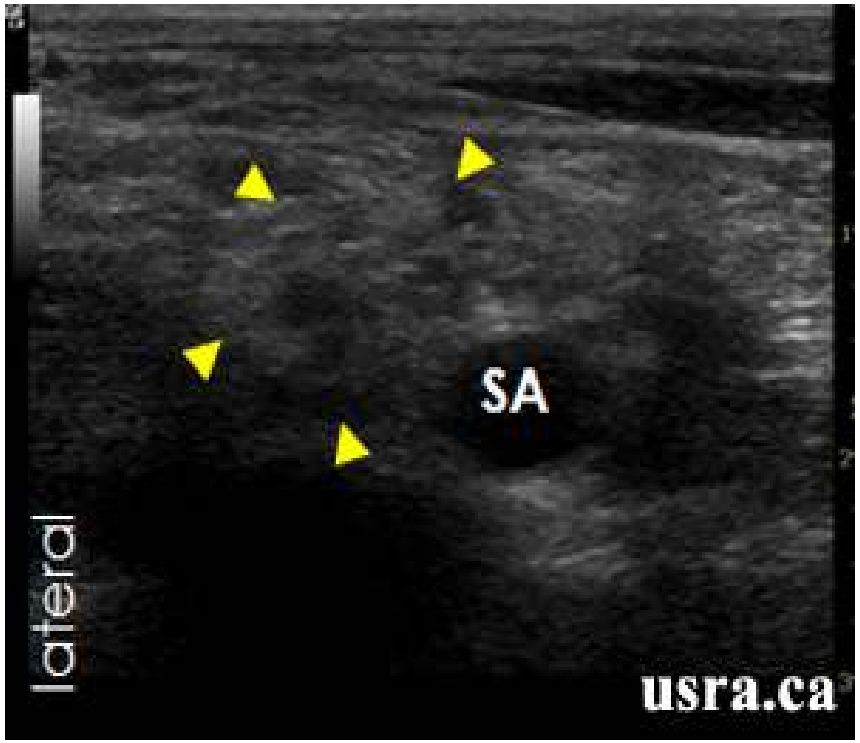

Nerve Localization

- Take advantage of a real time anatomical examination every time a transducer is placed on the skin surface of a patient.
- Perform a complete and systematic anatomical survey in the region. This is similar to reading a chest x-ray.
- Nerves may not be readily visible at the first glance but vessels, muscles and bones are easily identifiable under ultrasound. These structures will define the target nerve location.
- It is important to visualize structures that should not be entered or trespassed (e.g., the first rib and pleura in the supraclavicular region).

Needling Technique

There are 2 common needle insertion approaches and 2 types of needle to transducer alignment.

IN PLANE (IP) Needle Approach

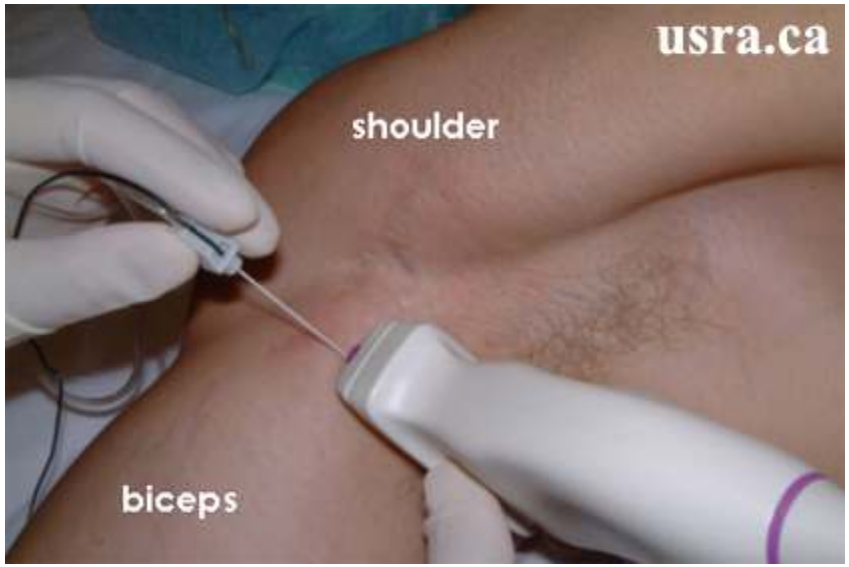

The needle is placed inline with and parallel to the transducer (ultrasound beam). Both the needle shaft and tip are visualized.
Axillary block is used as an example.

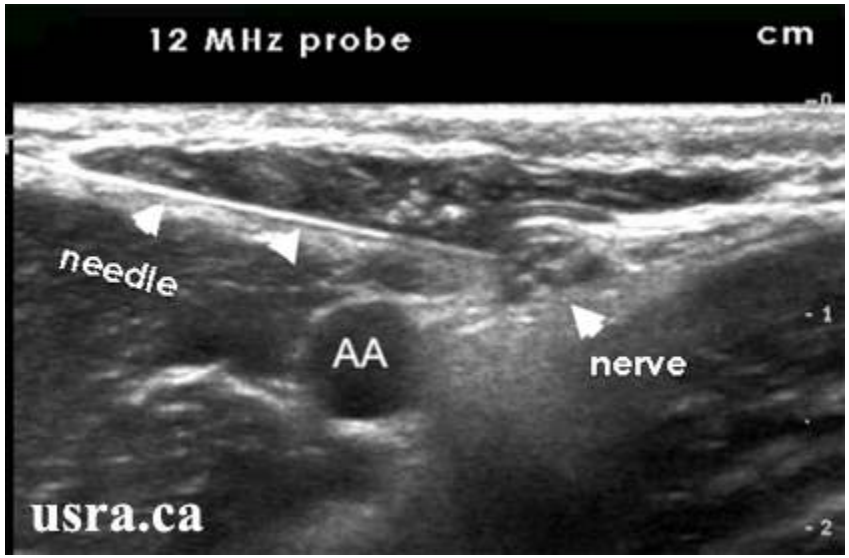

Needle to nerve contact can be followed in real time. The full length of the needle shaft and tip can be visualized.
The needle tip is seen in contact with the nerve (honeycomb structure)

OUT OF PLANE (OOP) Needle Approach

The needle is placed perpendicular to the transducer. The needle shaft and tip are visualized as a hyperechoic dot on ultrasound.
The femoral nerve block is used as an example.

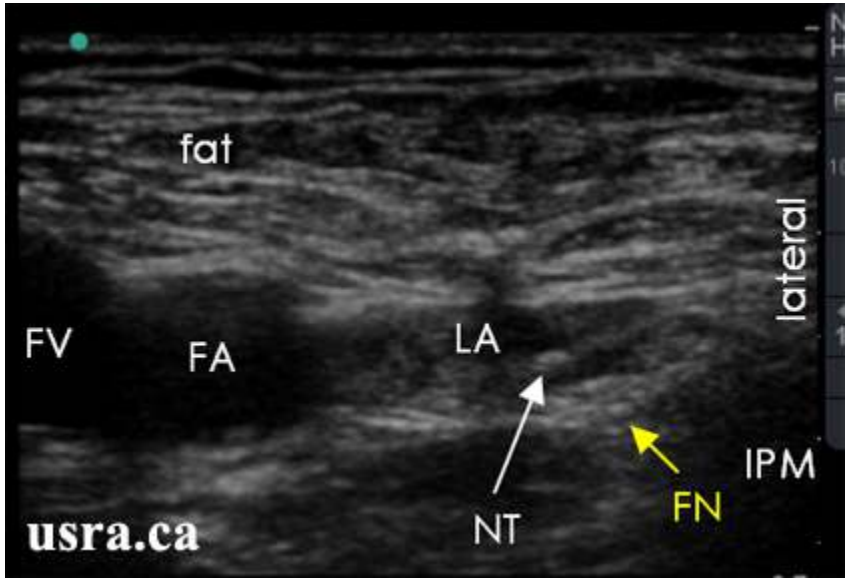

In this case, needle, nerve and tissue movements are observed. The needle tip (NT) may be difficult to locate accurately without the use of echogenic tip needles.