
بسم الله الرحمن الرحيم

BASICS OF ULTRASOUND IMAGING FOR NERVE BLOCKS(2)

M.REZVANI. MD,
Anesthesiologist, Pain Fellowship
Department of Anesthesiology & Pain Medicine
MUI
ISRAPM

Ergonomic arrangement of anaesthetist, patient and ultrasound machine

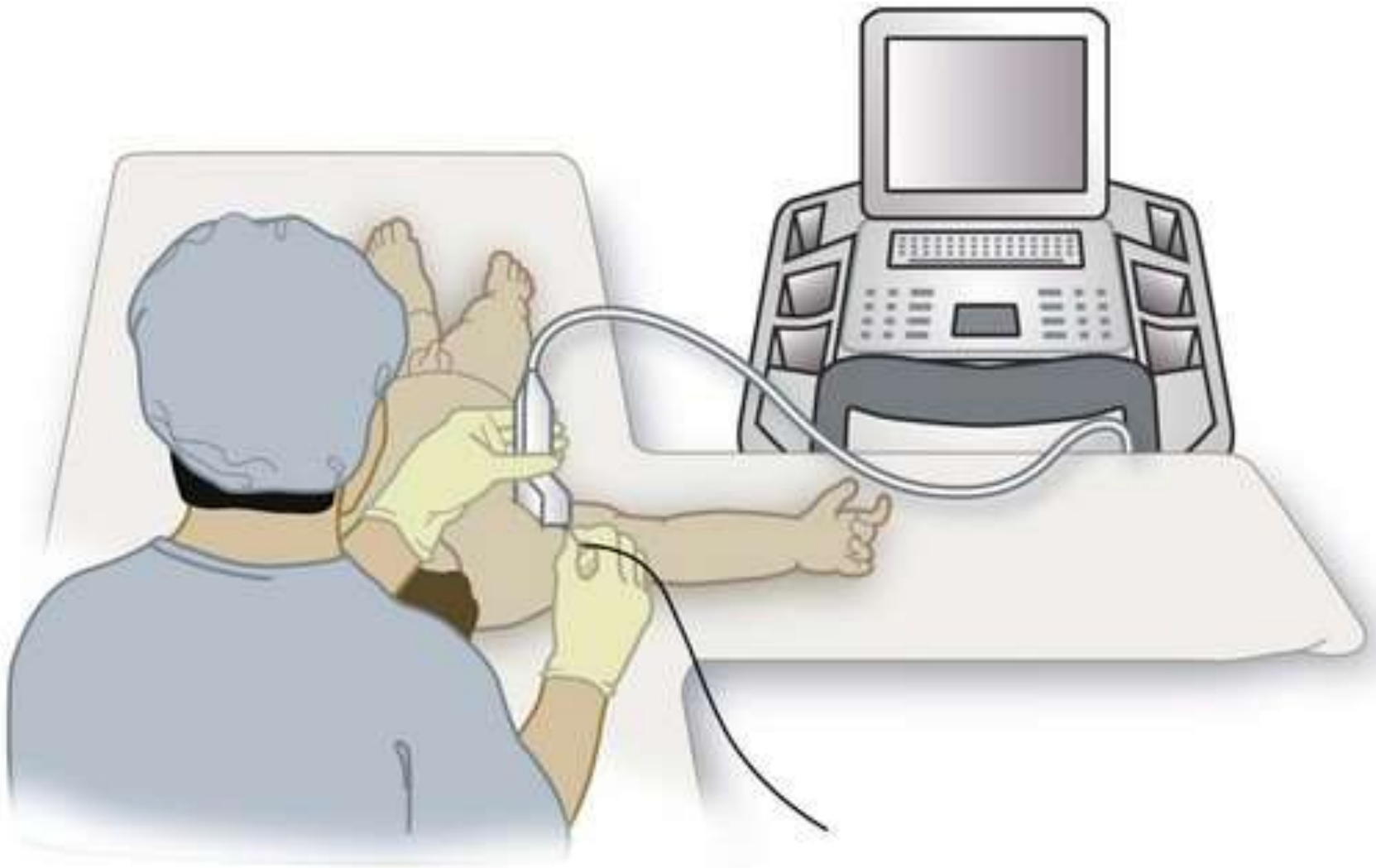


B|BRAUN | PHILIPS

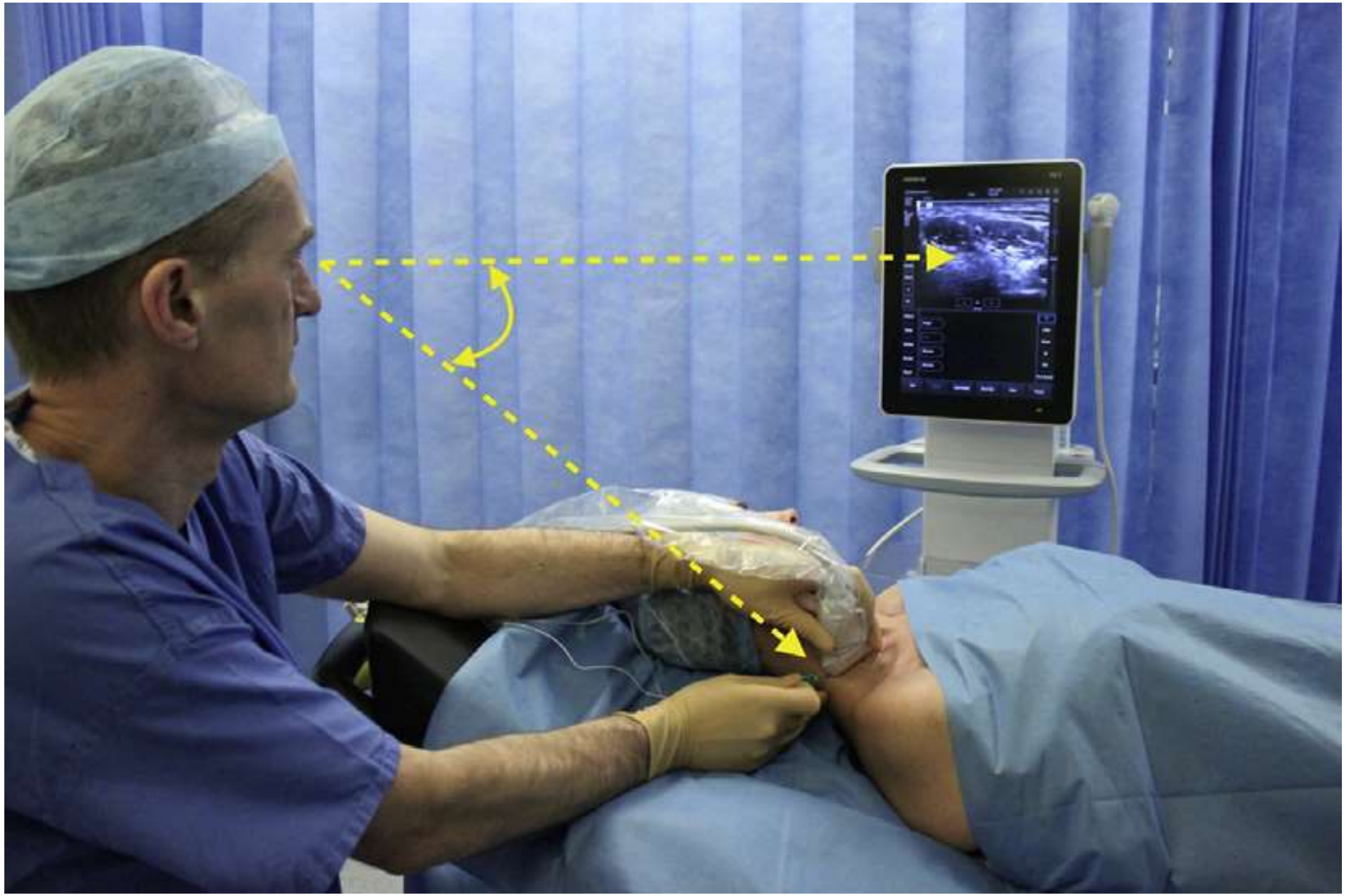

- Ambient lighting has a large effect on visual discrimination; therefore dim lighting without glare is especially useful for imaging low-contrast targets such as peripheral nerves

Ultrasound imaging allows direct visualization of peripheral nerves, the block needle tip, and local anesthetic distribution

- Peripheral nerves can be directly detected with high resolution ultrasound imaging

- The fascicular echotexture is the most distinguishing feature of nerves (honeycomb architecture)

More central nerves, such as the cervical ventral rami, have fewer fascicles and can appear monofascicular on ultrasound scans

Ultrasound frequencies of 10 MHz or higher are required to distinguish tendons from nerves based on echotexture alone

Successful injection for peripheral nerve block has typical characteristics:

Injections should distribute 1-around the nerve, 2-travel along the nerve path and branches, and 3-separate the nerve from common anatomic structures such as adjacent arteries that are wrapped together in common fascia and connective tissue

Scanning


ML6-15

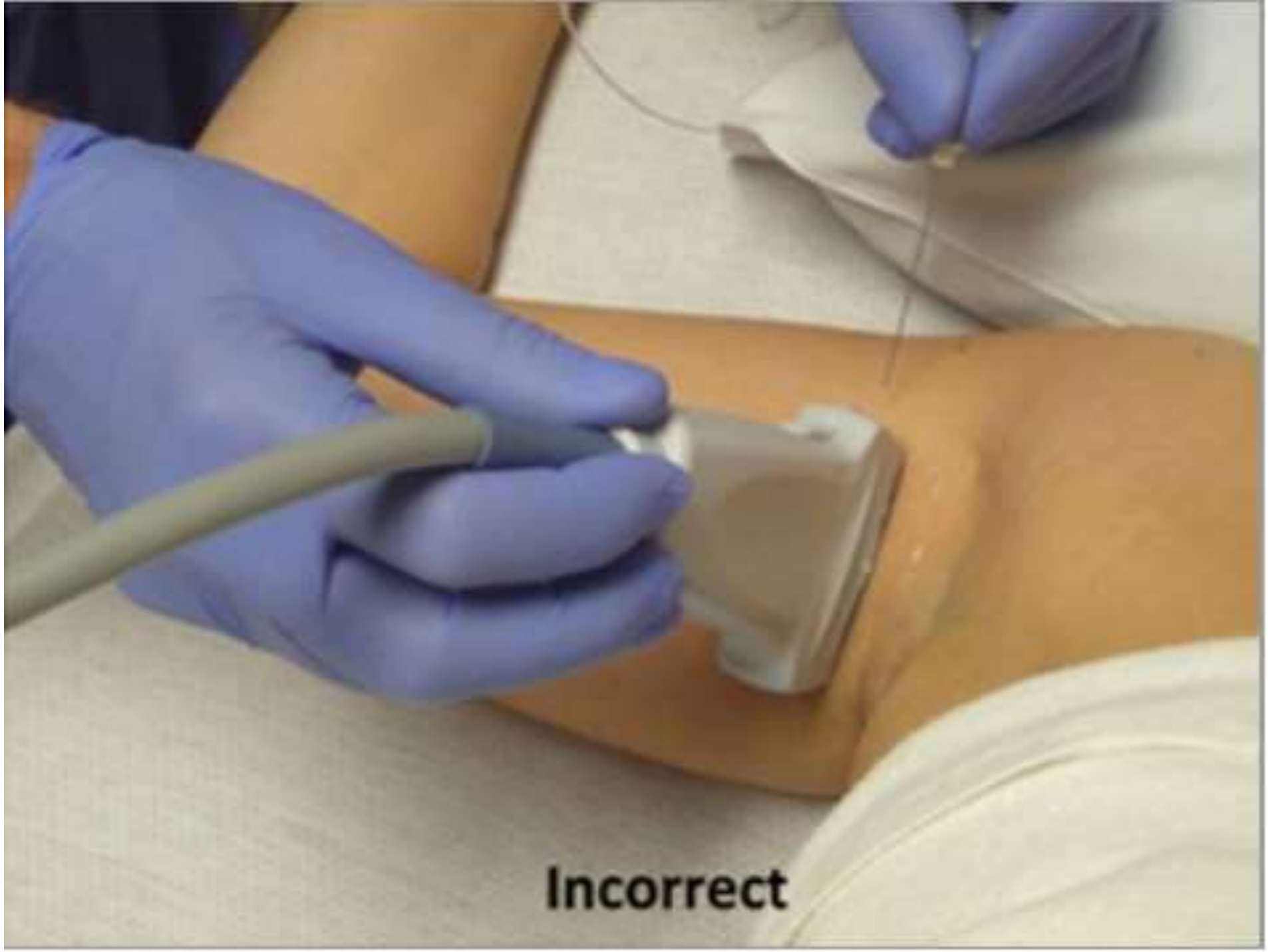
Incorrect

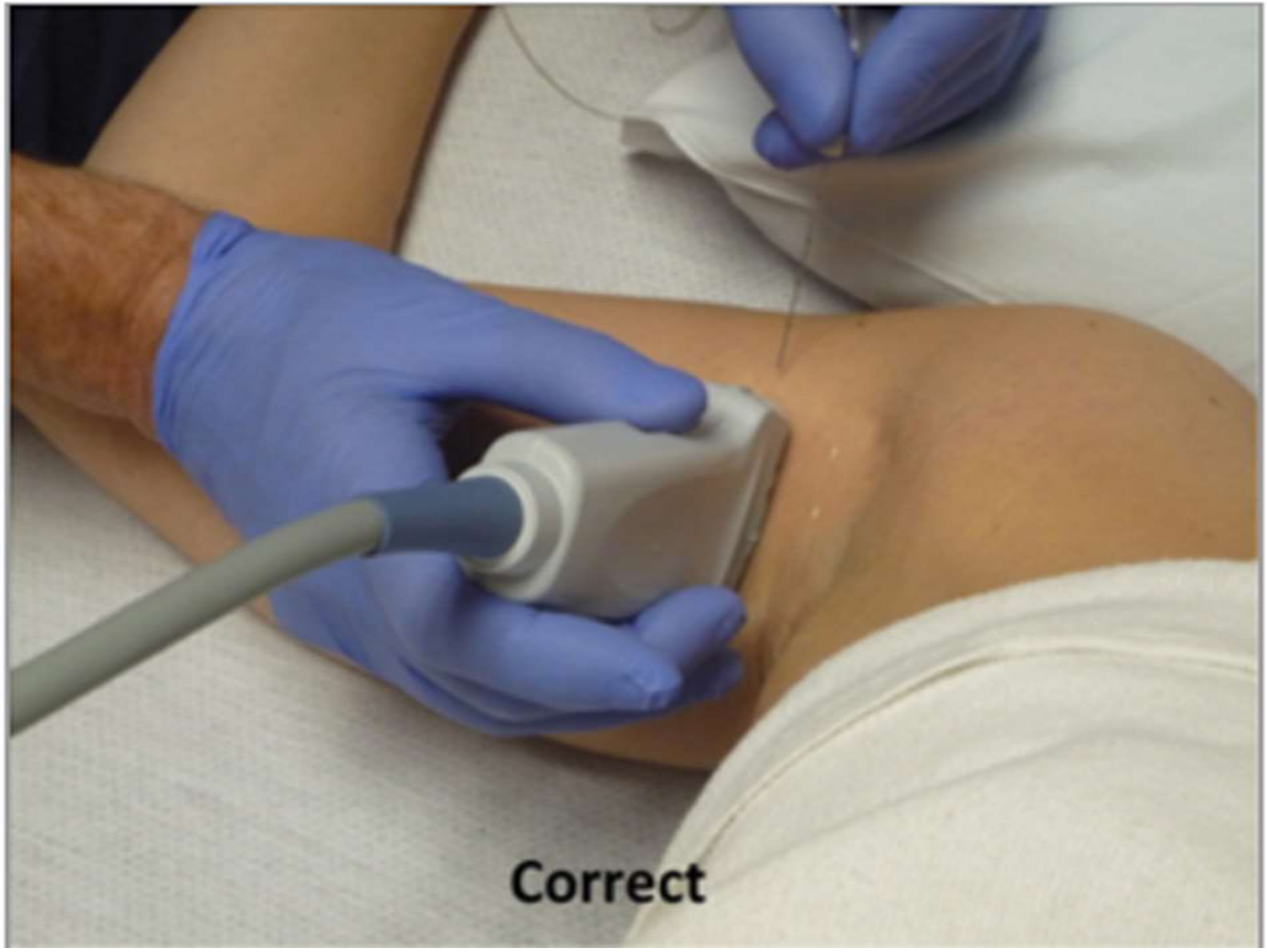
Correct

Scan landmarks

Use vascular and bony landmarks to orientate in a scan

For example, use the subclavian artery and first rib to orientate in a supraclavicular scan of the brachial plexus

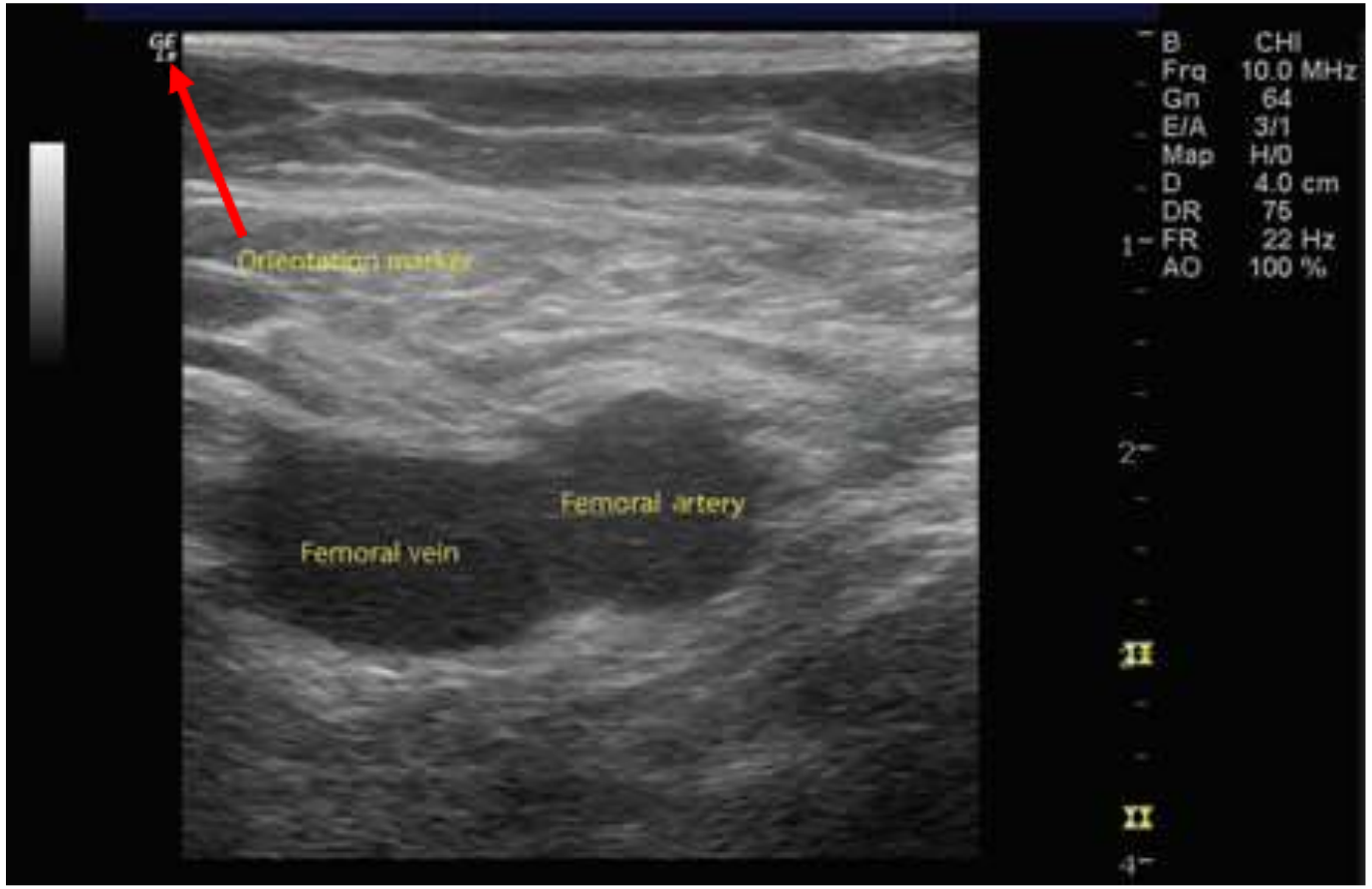
Orientation marker
Femoral artery
Femoral vein
B CHI
Frq 10.0 MHz
Gn 64
E/A 3/1
Map H/0
D 4.0 cm
DR 75
FR 22 Hz
AO 100 %

Transverse scan

During a transverse scan, the ultrasound probe is placed in a perpendicular plane to the target being imaged

The image on the screen is a cross-sectional view of the nerve or blood vessel

Nerves and vessels appear round

The terms transverse, short axis, and out-of plane

(OOP) are often used interchangeably

Median nerve

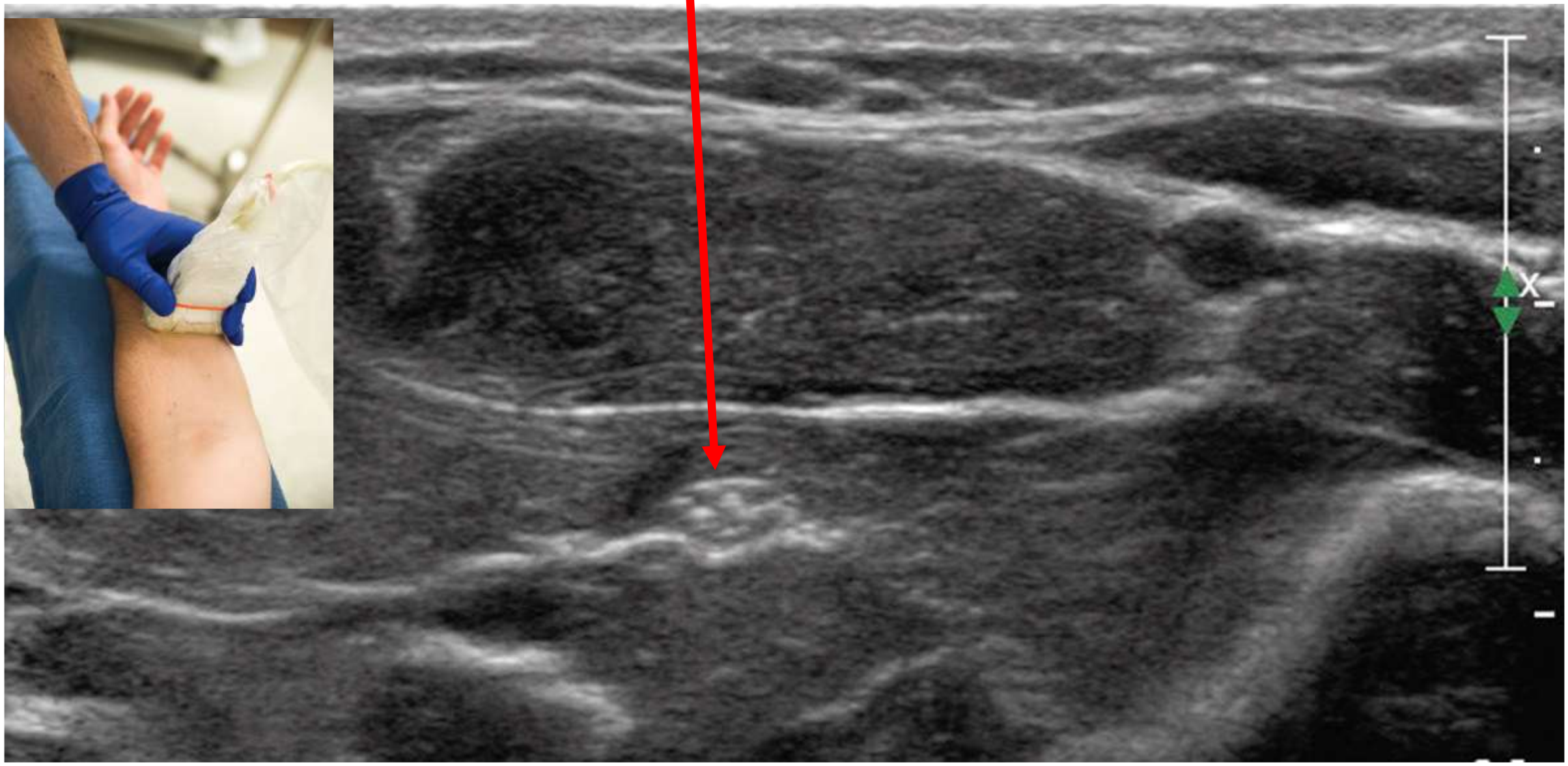

Longitudinal scan

During a longitudinal scan, the probe is placed in the same plane as the target being imaged

The ultrasound beam travels along the long axis of the nerve or blood vessel

In a longitudinal scan, blood vessels and nerves appear as linear structures

The terms longitudinal, long axis and in-plane (IP) can be used interchangeably

Median nerve

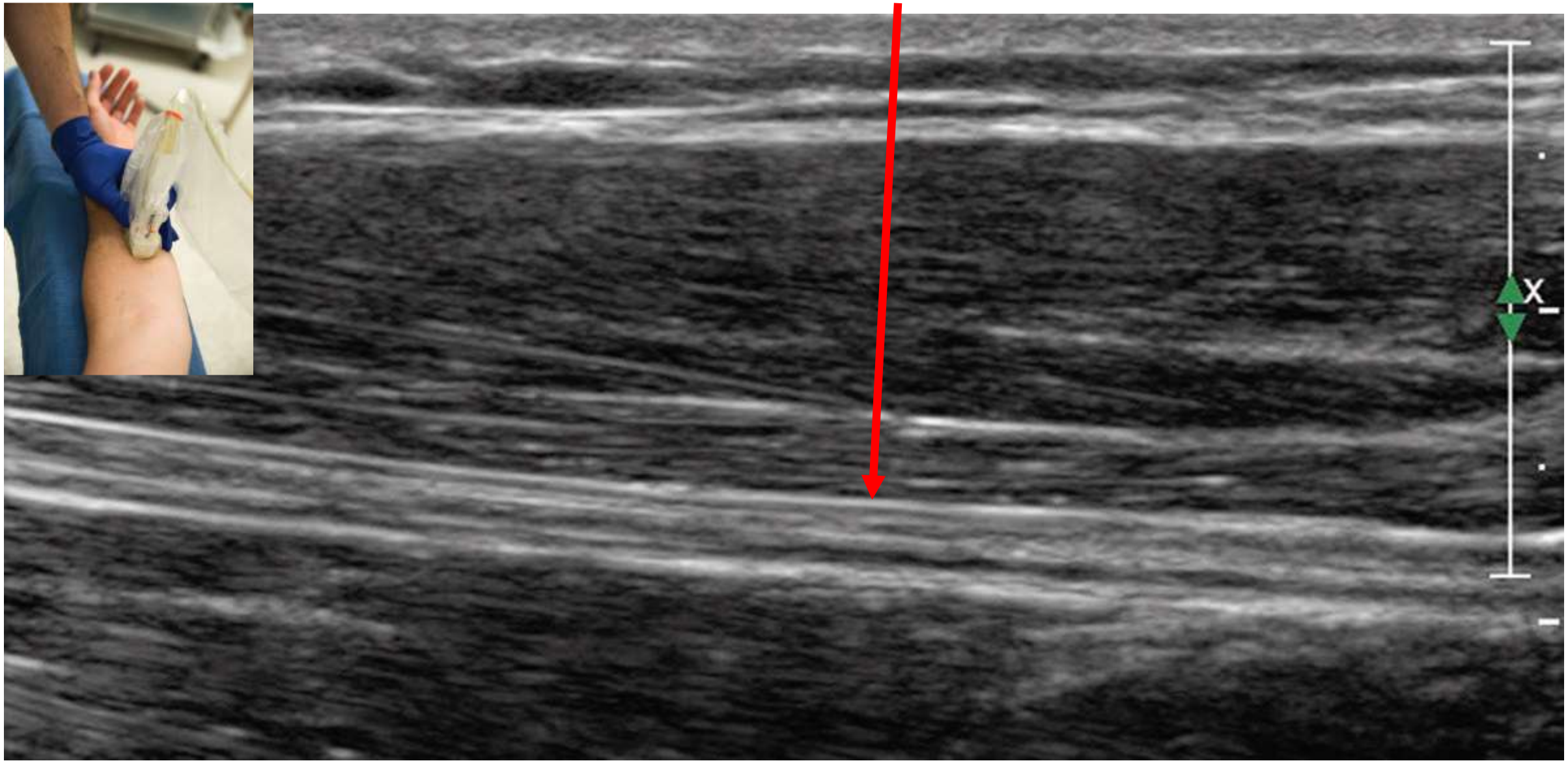

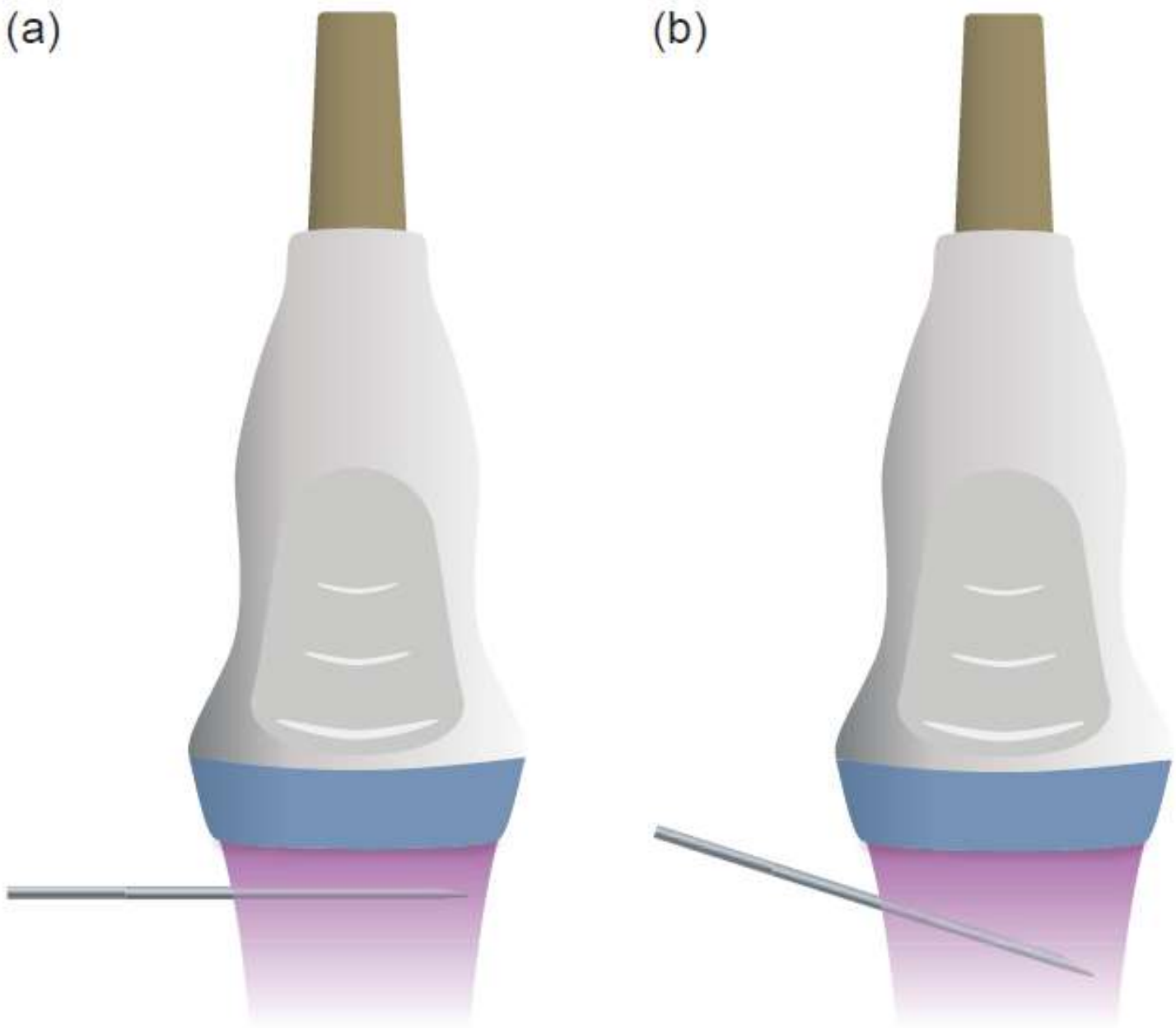
(a)
(b)

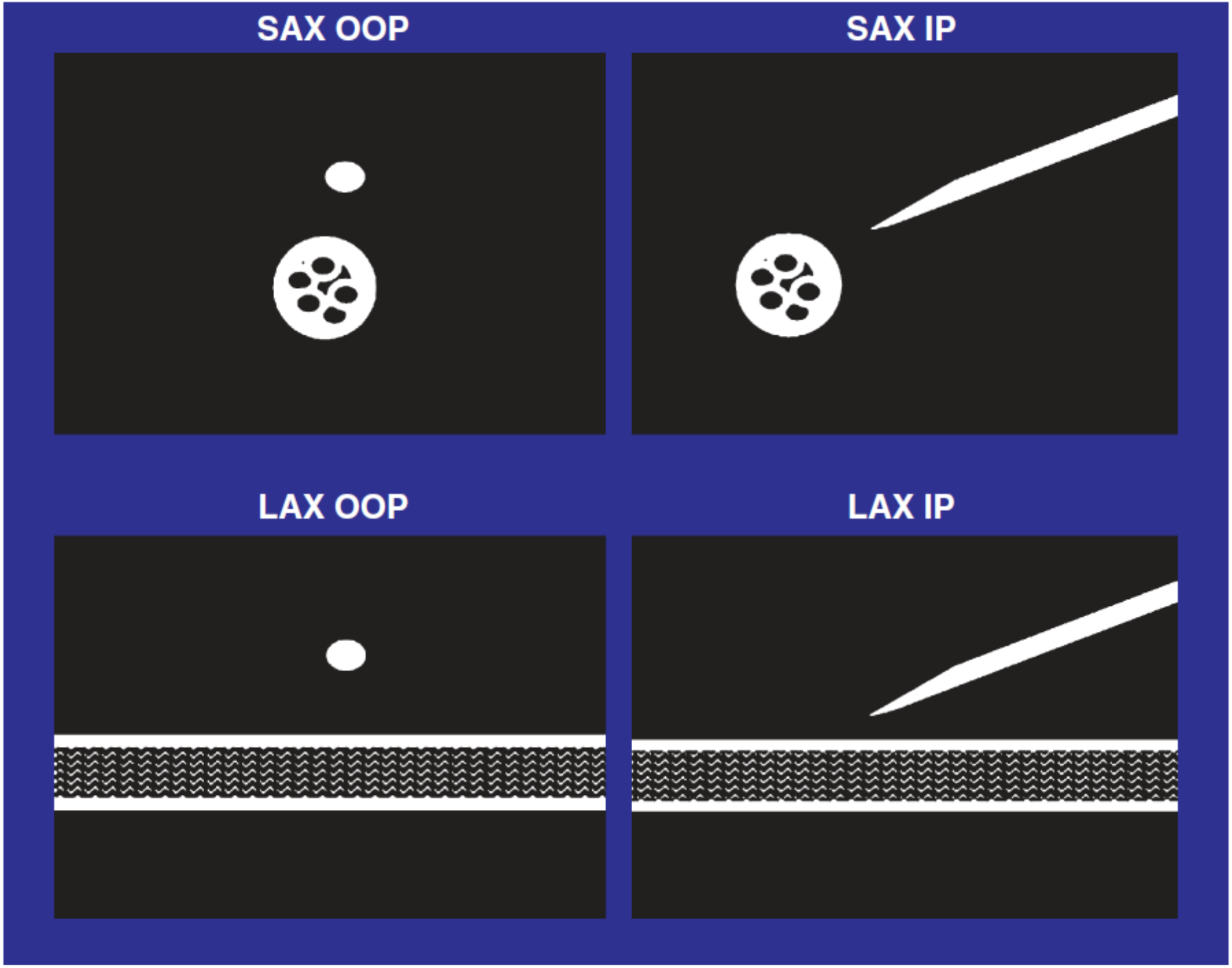
SAX OOP
SAX IP
LAX OOP
LAX IP

Transducer Manipulation

Sliding (moving contact) the transducer along the known course of the nerve using a short-axis view often helps

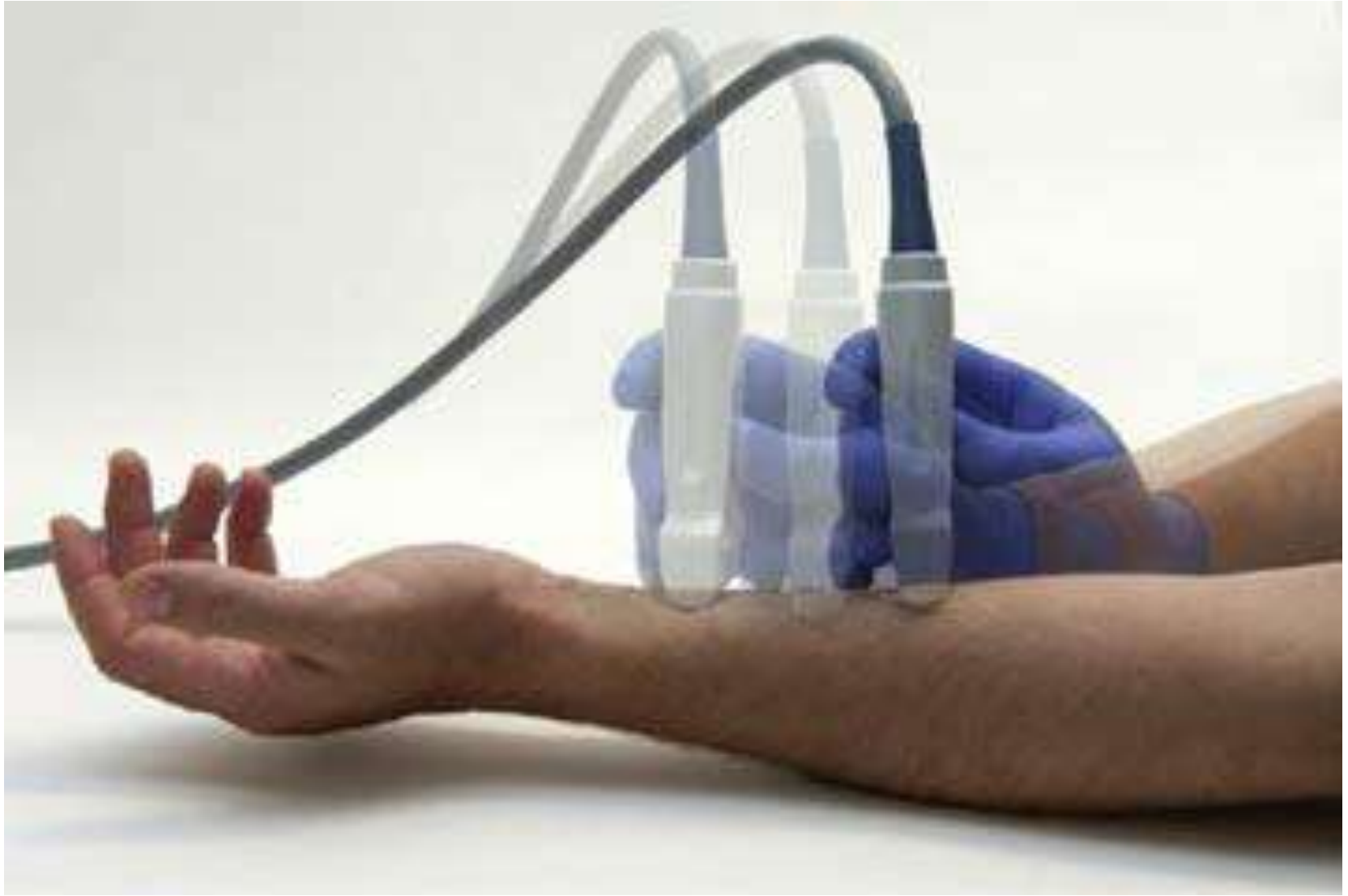

- Sliding is one of the most useful technique for tracking

- In tracking practitioner first scan a nerve or other thing in an area which that target point is better seen and then follow it with sliding the probe to specific area for intervention or diagnostic procedures

- Compression is often used to confirm venous structures
- To improve imaging, compression not only provides better contact, but it also brings the structures closer to the surface of the transducer
- Therefore estimates of tissue distances will vary

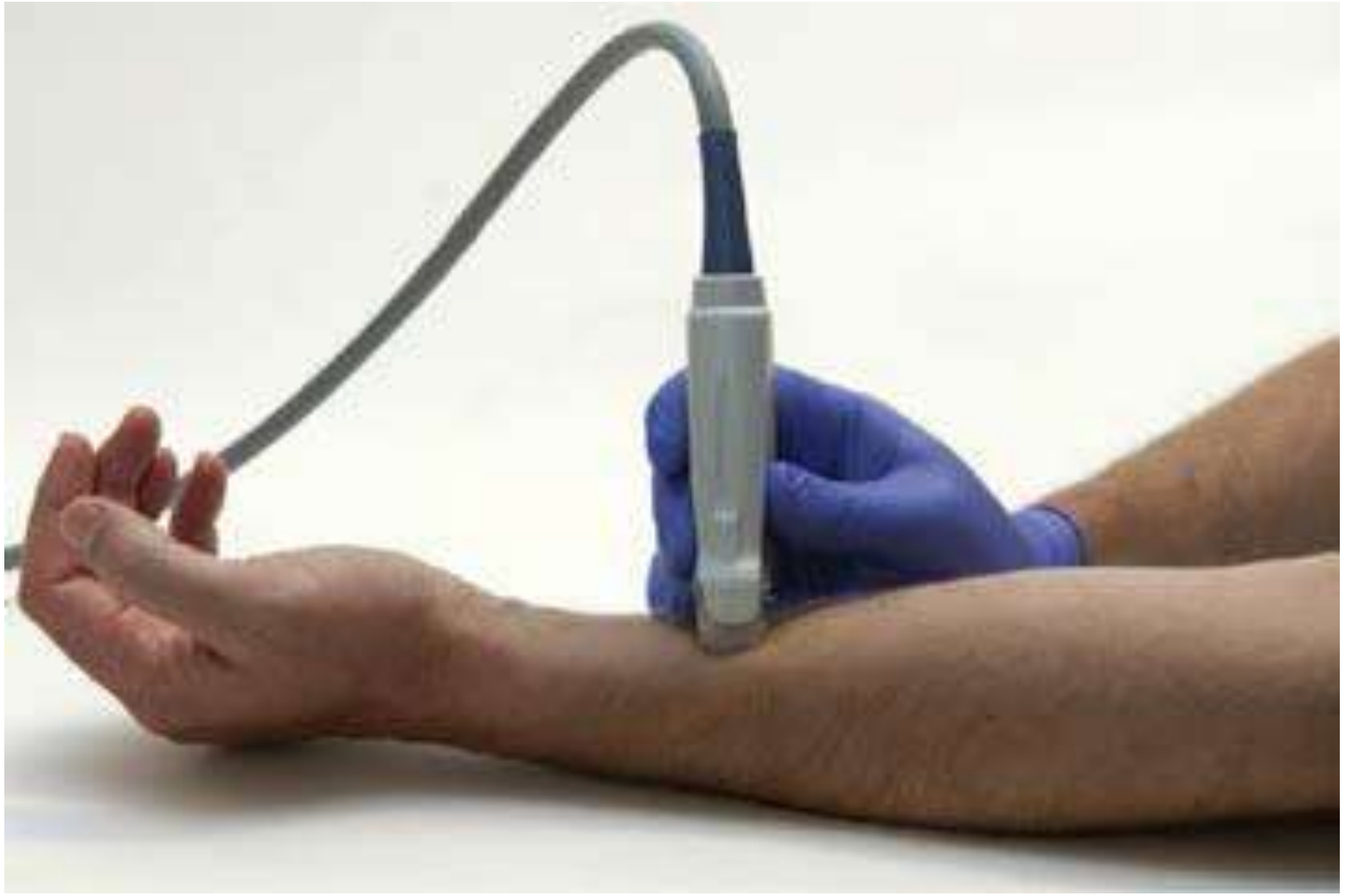

Rotation of the probe will produce true short-axis views rather than oblique or long-axis views

- Rocking (in-plane, toward, or away from the indicator)
- Is often necessary to improve visibility of the needle and anatomic structures when the working room is limited

Tilting (cross-plane, side-to-side) will vary the echo

brightness of peripheral nerves. Optimizing this angle is critical to promote nerve visibility

Although the term anisotropy was first used to describe changes in received echoes when rocking the transducer with structures viewed in long axis, it has also been used for short-axis views when tilting the transducer

Needle Tip Visibility

- Metal needles are hyperechoic and can cause reverberation artifact

- Needle tip visibility is best when the needle path is parallel to the active face of the transducer

- As the angle of incidence is increased, the mean brightness will decrease

- ❖The bevel angles were ground from 10 to 70 degrees but were found to have no effect on the needle tip echo

- ❑However, bevel orientation does influence the needle tip echo

- ➢Visibility is best with the bevel either directly facing or averting the transducer

- Because needle diameters are smaller than the scan plane thickness, larger needles are more echogenic than finer ones

Visualization of needles in echogenic tissue is difficult, particularly in bright adipose tissue

A number of strategies have been proposed to improve needle tip visibility

low-receiver gain can improve the detection of the needle tip echo

Spatial compound imaging can help identify the needle tip when the needle path is at an angle with respect to the transducer(with some limitations)

- Rocking back the transducer can improve the angle between the ultrasound beam and needle during in-plane technique

- Most practitioners orient the needle so that the needle bevel faces the transducer

Hustead bevels tended to be more visible than side port needles that lack cutting bevels

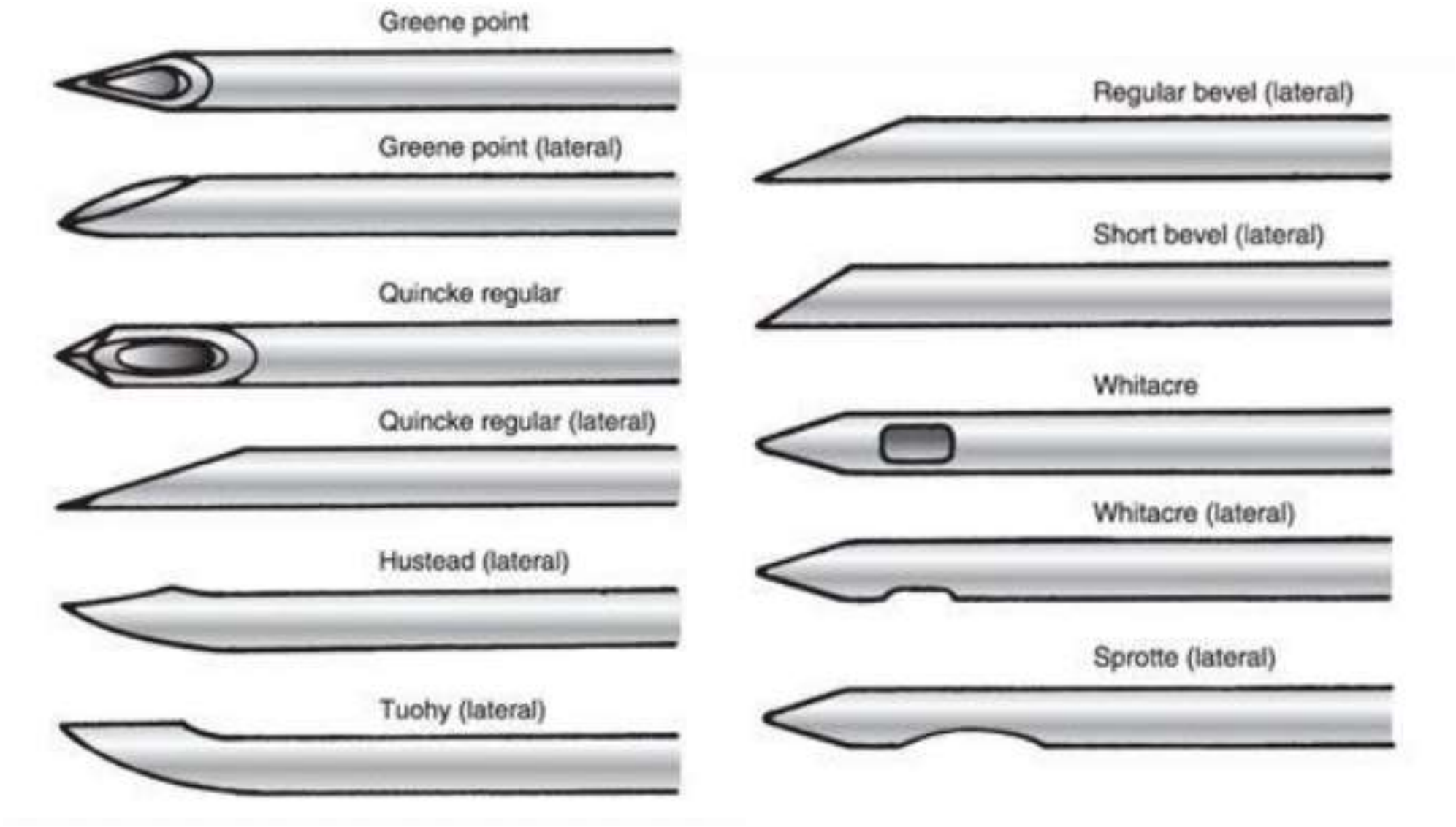

https://aneskey.com/equipment-4/

Needles with echogenic modifications are now commercially marketed for peripheral nerve blocks

One engineering strategy has been to texture the needle surface so that echoes return to the transducer source, regardless of the angle of insonation

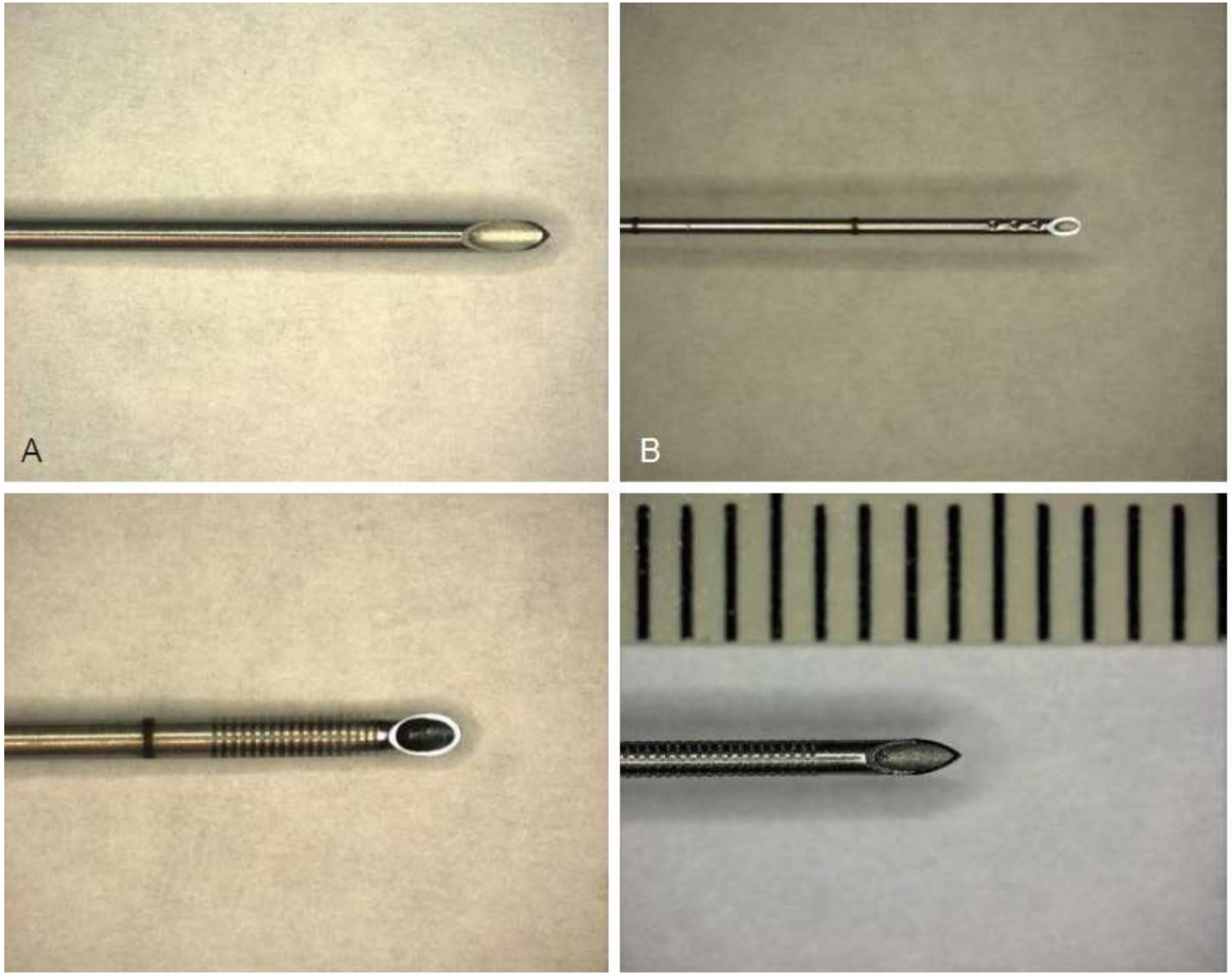
A
B

Selection the probe


HFL50
15-6MHz

Linear probe

Hockey-stick probe

Curvilinear probe

High-frequency sound waves provide the best resolution but will not penetrate far into tissue

The frequency range is therefore chosen to be the highest that will allow adequate insonation of the entire depth of field

A low-frequency transducer can be used to image large nerves that lie deep, such as the cords of the brachial plexus that surround the second part of the axillary artery or the proximal sciatic nerve in the gluteal region

The footprint size (i.e., the length of the active face transducer that contacts the skin) is chosen to provide a broad enough view of the structures of interest

As a general rule, the footprint should be at least as large as the anticipated depth of field

Linear-array transducers generally have a higher scanline density than curved arrays and therefore produce the best image quality

Images from linear arrays are usually displayed in a rectangular format

When a linear transducer is needed but space at the site of block is limited by anatomic structures such as adjacent bone, a compact linear (hockey stick) transducer that has a smaller footprint can be very useful



Tissue appearance under ultrasound

Strongly reflected waves, such as those from specular reflectors and those from boundaries of tissues with great differences in acoustic impedance (bone/soft tissue), will have a white or hyperechoic

Appearance

Examples of hyperechoic appearance would be bone, diaphragm, or a block needle

Ultrasound waves from scattering reflectors or those returning from deeper regions that have undergone extensive attenuation have a gray or hypoechoic appearance

Examples of hypoechoeic appearance would be soft tissue, such as muscle, solid organs, and fat

Substances with high water content (e.g., blood, cerebrospinal fluid) conduct sound very well and reflect very poorly and thus are termed echolucent

They appear as dark areas (hypoechoic)

Substances low in water content or high in materials that are poor sound conductors (e.g., air, bone) reflect almost all the sound and appear very bright (hyperechoic)

When waves are not reflected and travel unimpeded, the structure will have a black, or anechoeic appearance

Large blood vessels have an anaechoic appearance because the ultrasound waves travel through blood, which is relatively homogenous in its acoustic impedance, without being reflected

Any structure behind a highly reflective surface will have an anaechoic appearance

Arteries	**Anechoic/hypoechoic, pulsatile, non-compressible**
Veins	Anechoic/hypoechoic, non-pulsatile, compressible
Fat	Hypoechoic, compressible
Muscles	Heterogeneous (mixture of hyperechoic lines within a hypoechoic tissue background)
Tendons/ fascia	Hyperechoic
Bone	Very hyperechoic with acoustic shadowing behind
Nerves	Hyperechoic below the clavicle/ hypoechoic above the clavicle
Air bubbles	Hyperechoic
Pleura	Hyperechoic line
Local anesthetic	Hypoechoic, expanding hypoechoic region

Skin and Subcutaneous Tissue

Normal skin (epidermis and dermis) varies in thickness from 1 to 5 mm throughout the body and is uniformly hyperechoic

The attenuation of ultrasound by skin (>1 dB/[MHz-cm]) is more than other soft tissues (0.5 to 0.75 dB/[MHz-cm])

This is particularly important for thoracic paravertebral blocks in the upper back region where the skin is thick

Subcutaneous tissue is hypoechoic with connective septa visible as streaks parallel or nearly parallel to the skin surface


S
SC
EOM
IOM
TAM
P

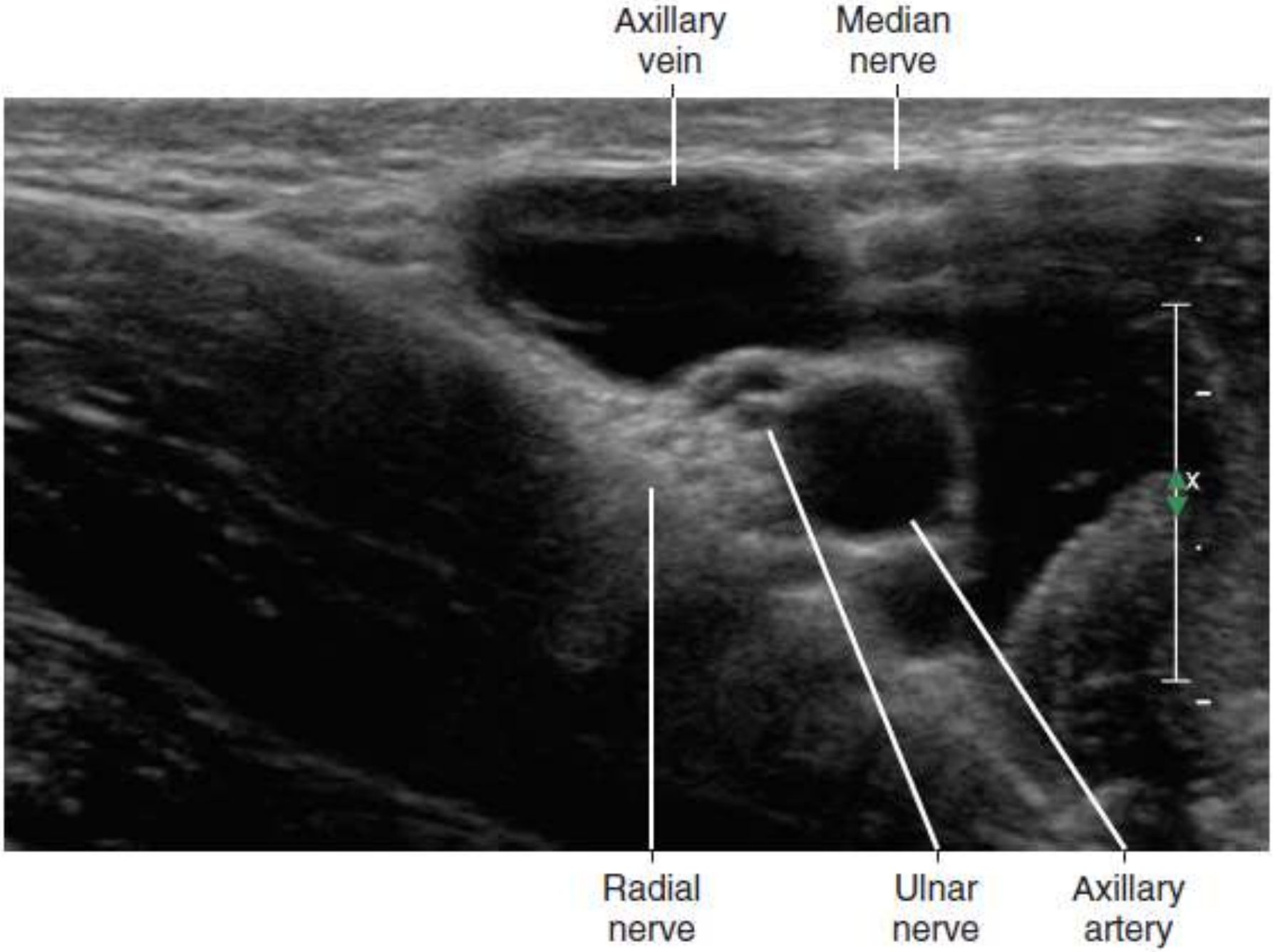
Axillary vein
Median nerve
x
Radial nerve
Ulnar nerve
Axillary artery

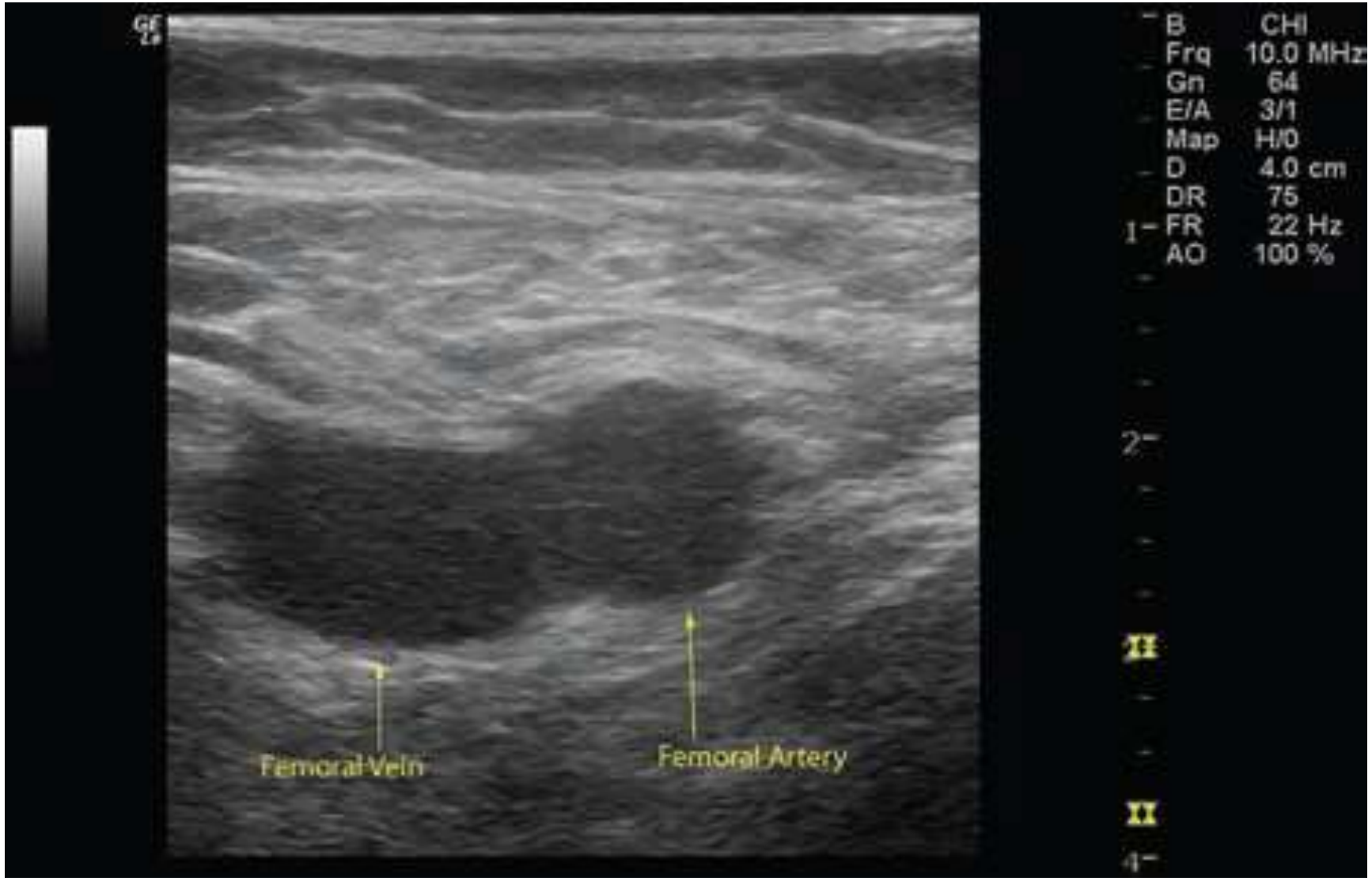
B CHI
Frq 10.0 MHz
Gn 64
E/A 3/1
Map H/0
D 4.0 cm
DR 75
FR 22 Hz
AO 100 %
Femoral Vein
Femoral Artery

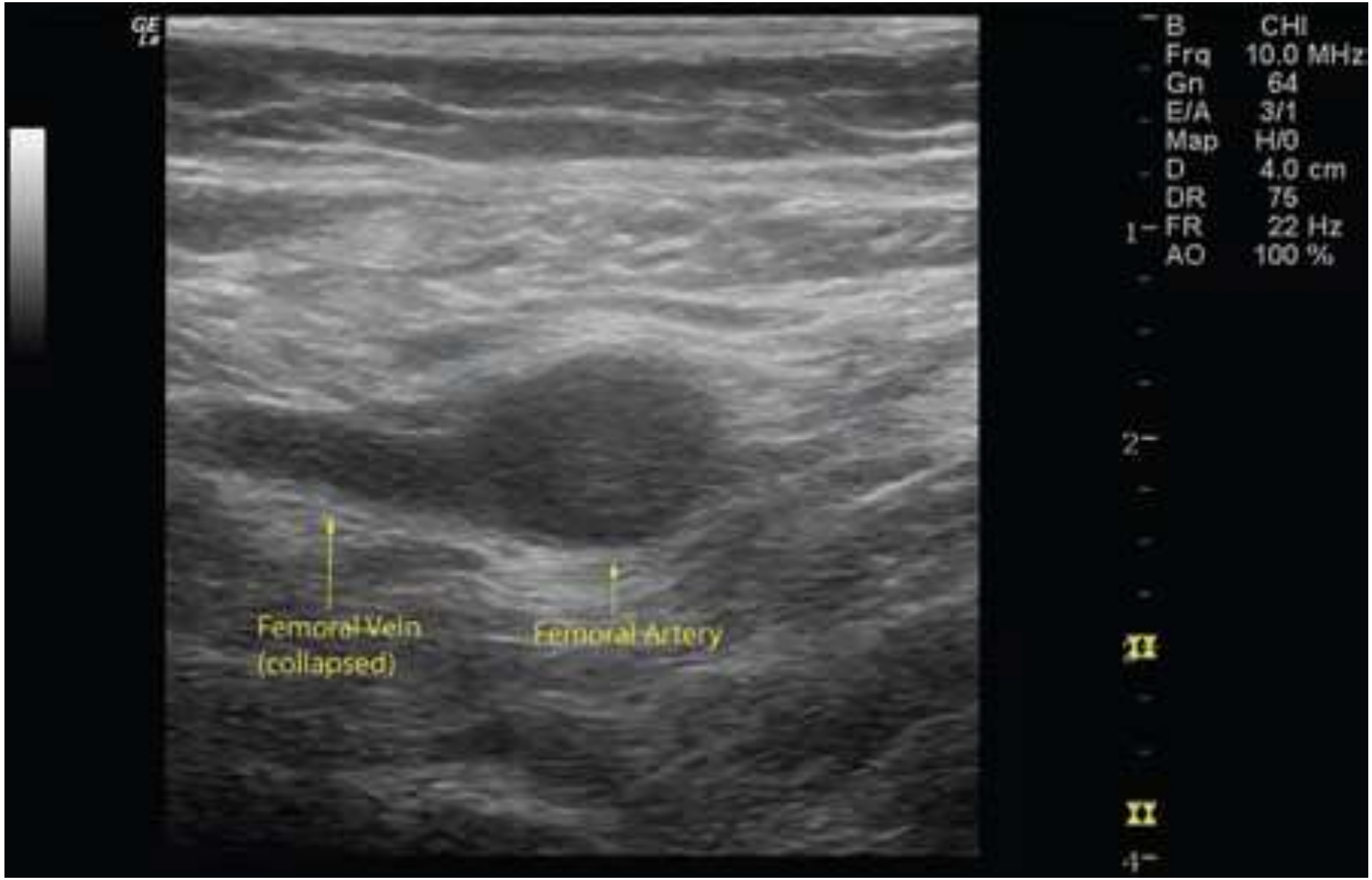
B CHI
Frq 10.0 MHz
Gn 64
E/A 3/1
Map H/0
D 4.0 cm
DR 75
FR 22 Hz
AO 100 %
Femoral Vein
(collapsed)
Femoral Artery

Fat :hypoechoic background with hyperechoic lines. Fat is compressible whereas muscle and nerves are not compressible

Muscle: hypoechoic background with hyperechoic lines. Muscle is not compressible and may be surrounded by a bright hyperechoic line representing fascia

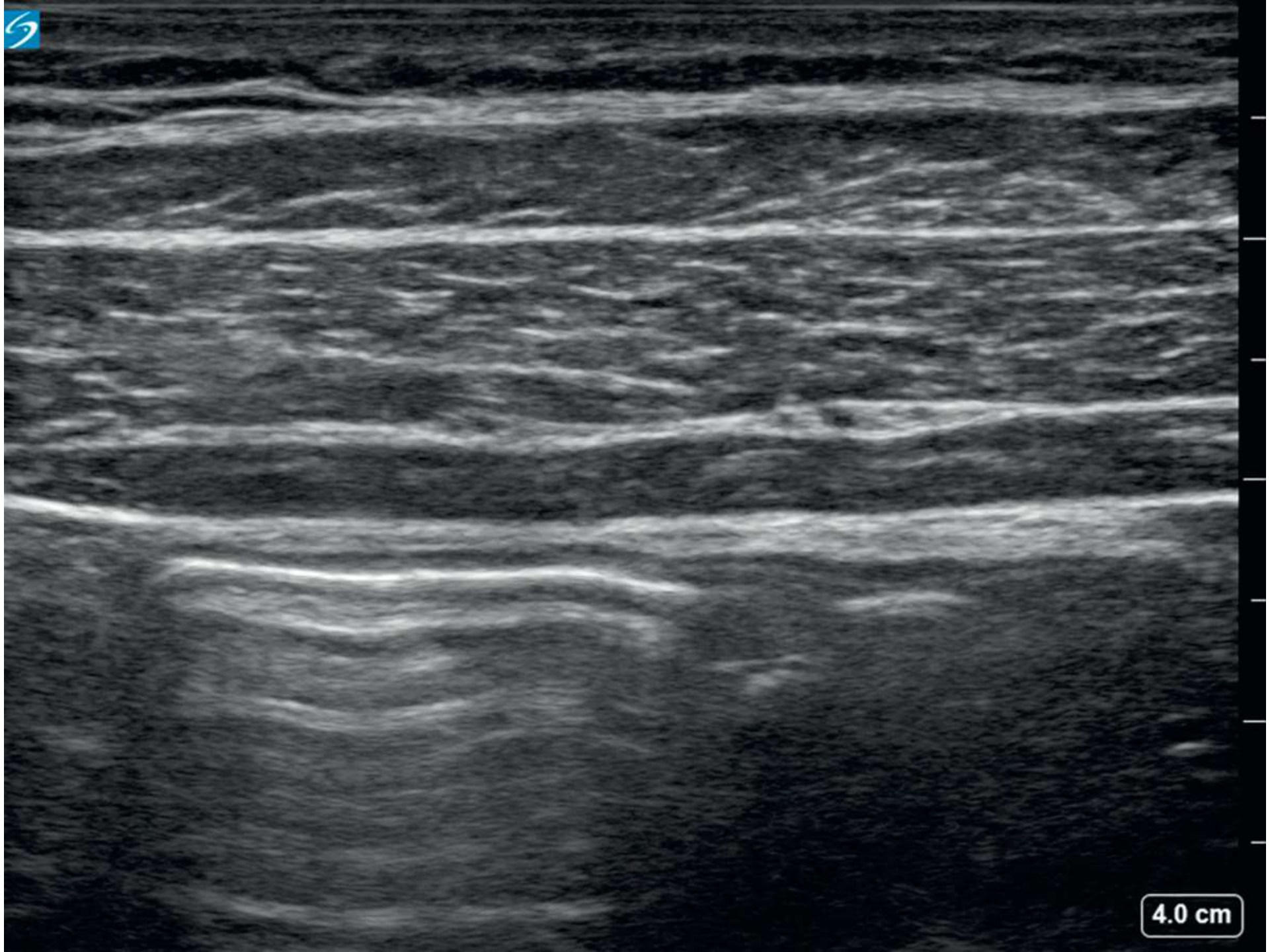
4.0 cm

- Tendons are the strong anatomic structures that connect muscle to bone

- Tendons are highly anisotropic

- Tendons and nerves are both imaged BUT :

✓ Tendons and nerves are primarily distinguished by tracing their course
✓ Tendons are more anisotropic than nerves
✓ At high frequencies of insonation (≥10 MHz), the fibrillar echotexture of tendons can be distinguished from the fascicular echotexture of nerves

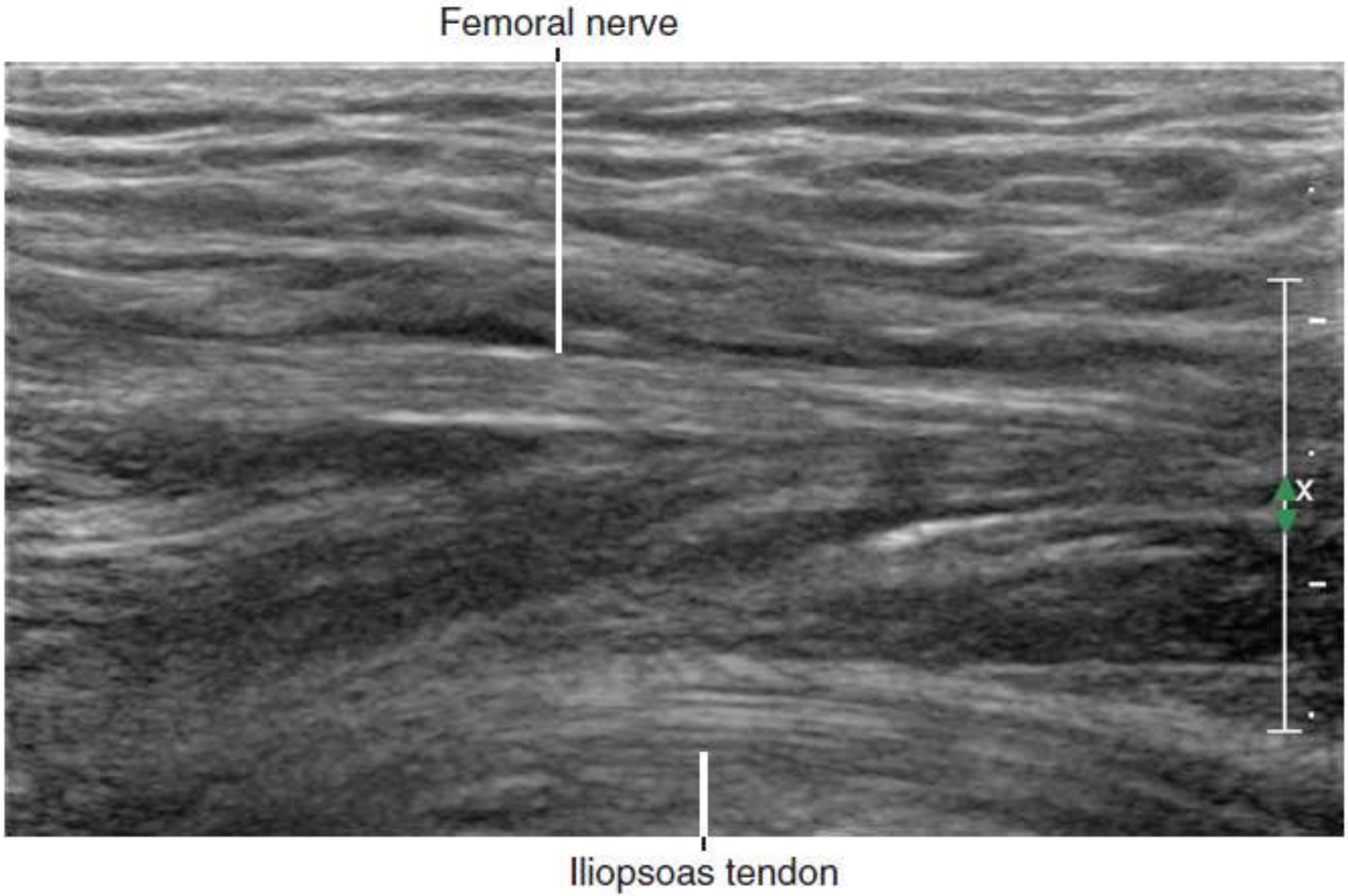
Femoral nerve
X
Iliopsoas tendon

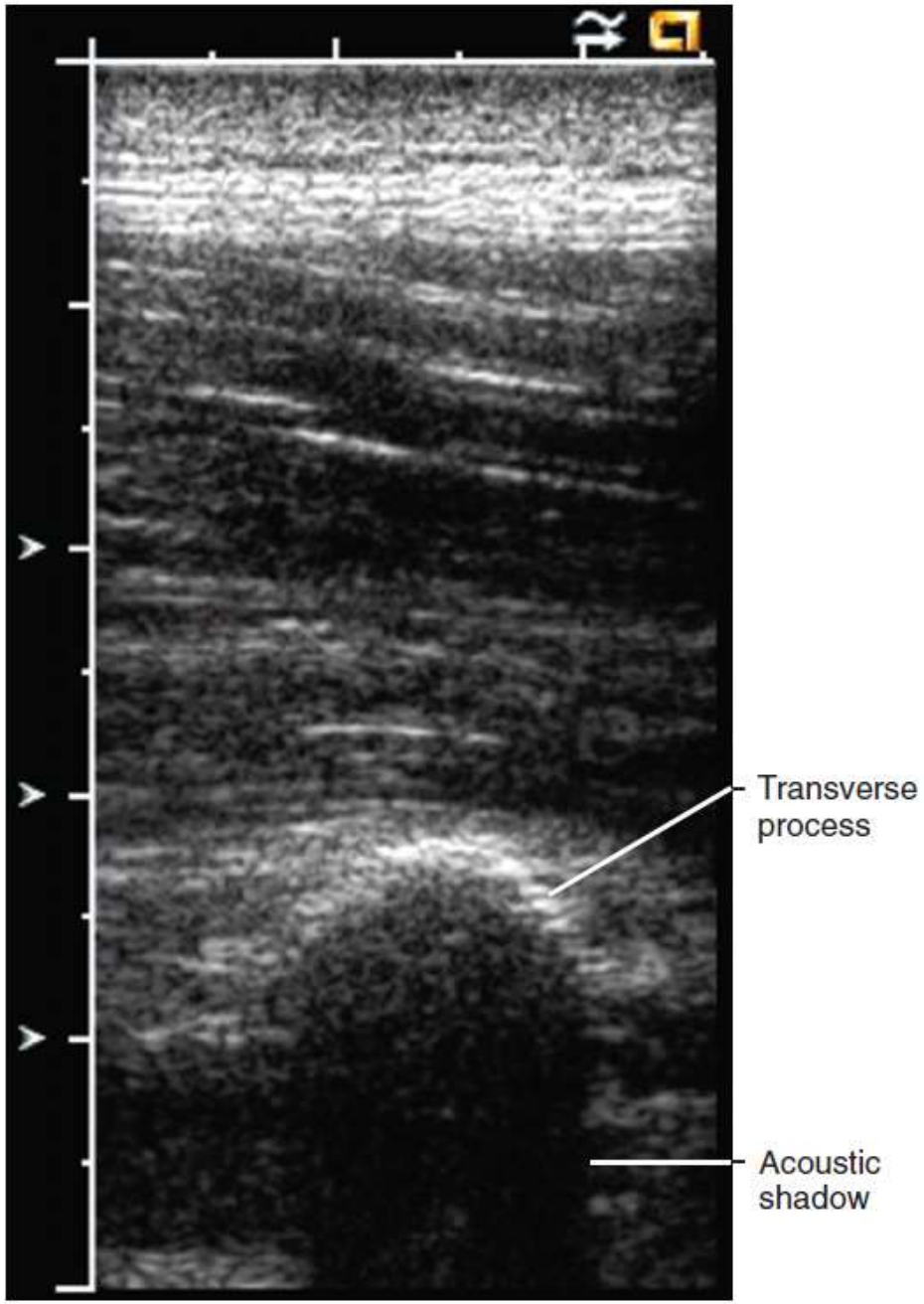

Ultrasound appearance of bone, demonstrating a bright cortical line and acoustic shadowing. In this sonogram, a shortaxis view of a transverse process is shown

The pleura is a strong reflector of ultrasound waves

Comet-tail artifact, indicating reverberation of sound waves, is observed deep to the pleural line on ultrasound scans

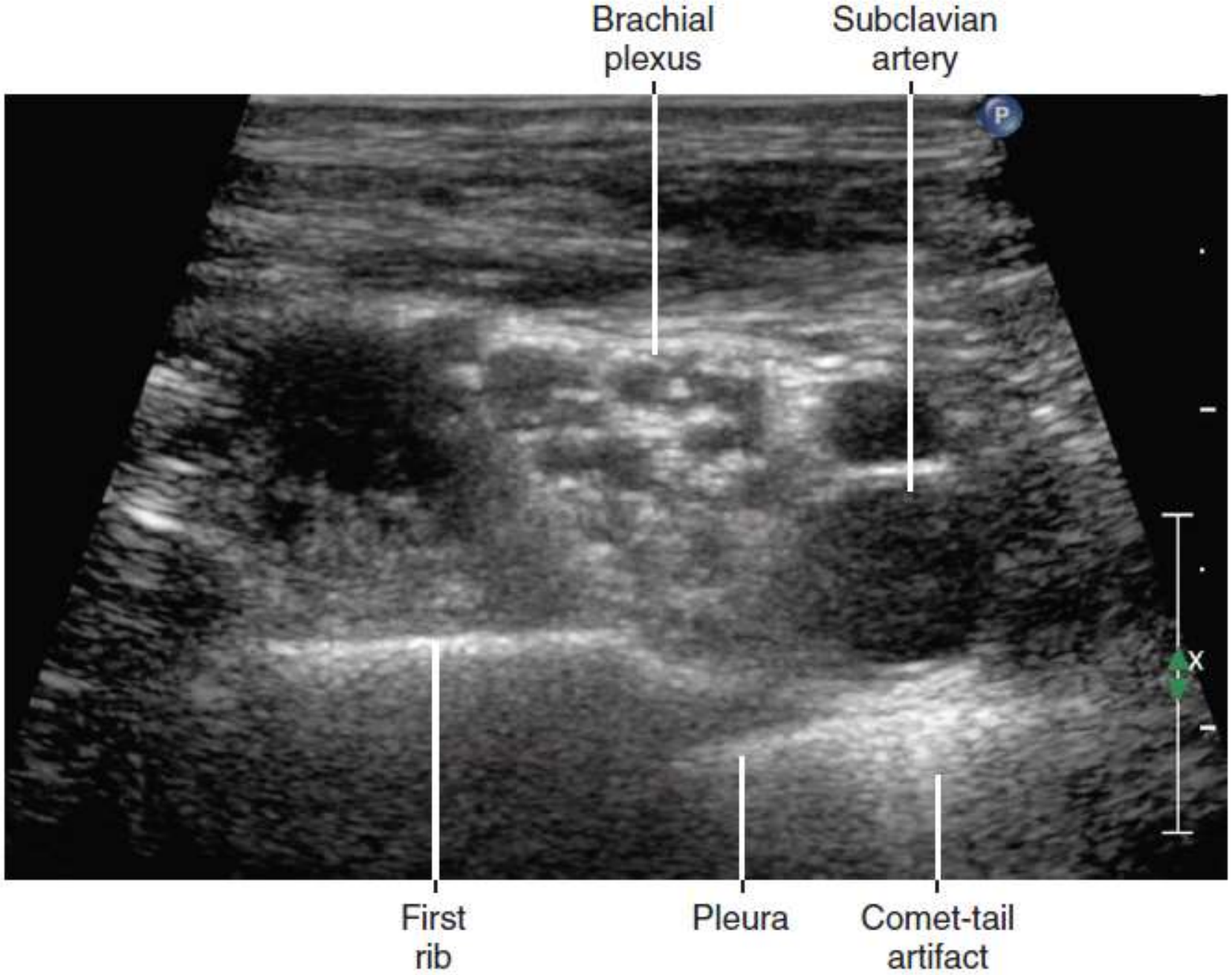
Brachial plexus
Subclavian artery
First rib
Pleura
Comet-tail artifact

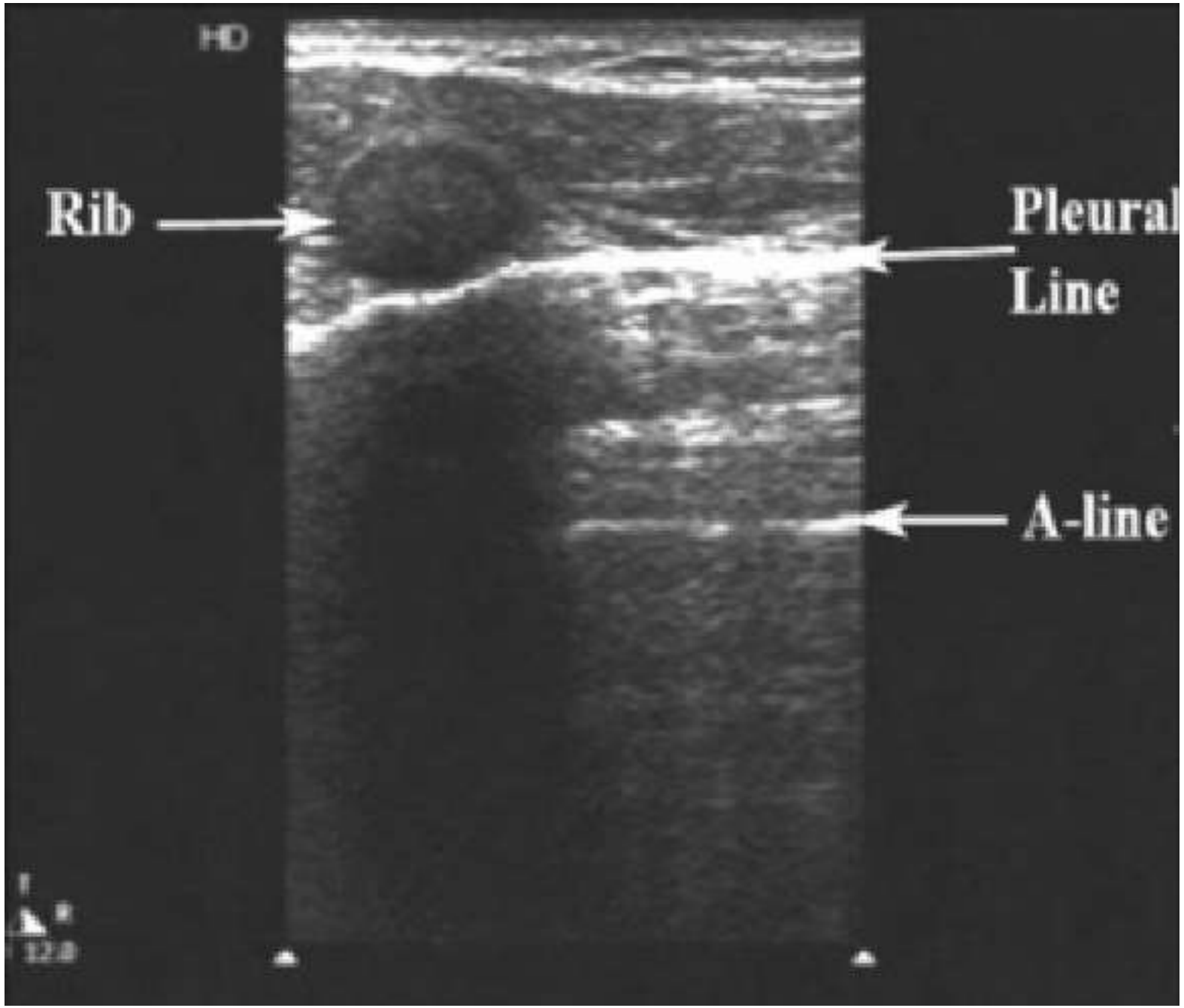
Rib
Pleural
Line
A-line

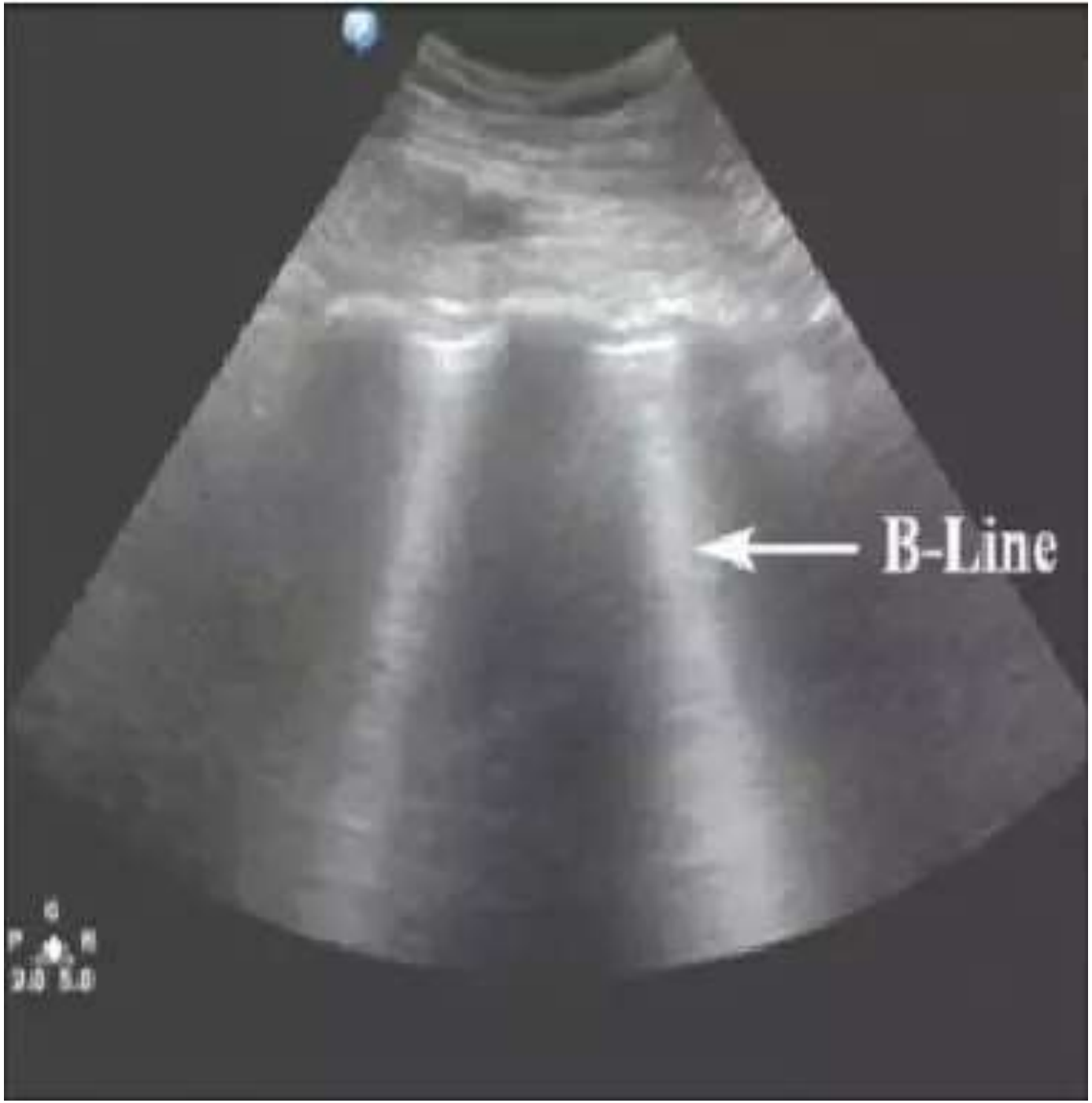
B-Line

Nerves

Nerves may appear as hyperechoic or hypoechoic

Nerves above the clavicle appear hypoechoic and below the clavicle appear hyperechoic

Neural tissue itself is hypoechoic. It is the connective tissue that surrounds nerves that give some nerves their hyperechoic appearance

Nerves can be round, oval, or triangular in shape

Peripheral nerves are usually viewed in short axis rather than long axis

One of the most powerful techniques to identify nerve fascicles is to slide a broad linear transducer over the known course of a peripheral nerve with the nerve viewed in short axis (transverse cross section)

The sciatic nerve displays a great deal of anisotropy

Slight angle changes of the probe will aid in bringing the sciatic nerve into view

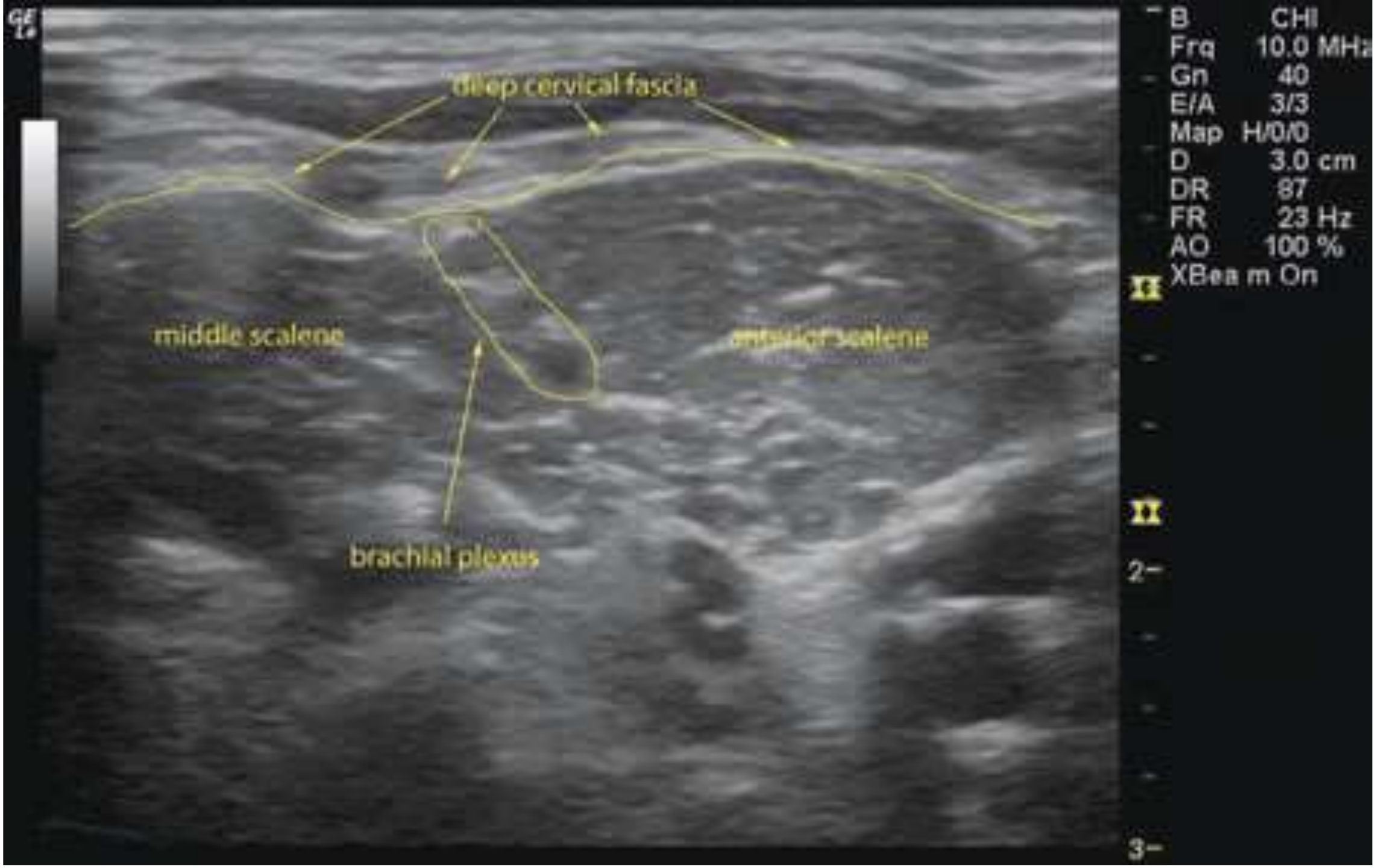
deep cervical fascia
middle scalene
anterior scalene
brachial plexus
B CHI
Frq 10.0 MHz
Gn 40
E/A 3/3
Map H/0/0
D 3.0 cm
DR 87
FR 23 Hz
AO 100 %
XBeam On
2
3

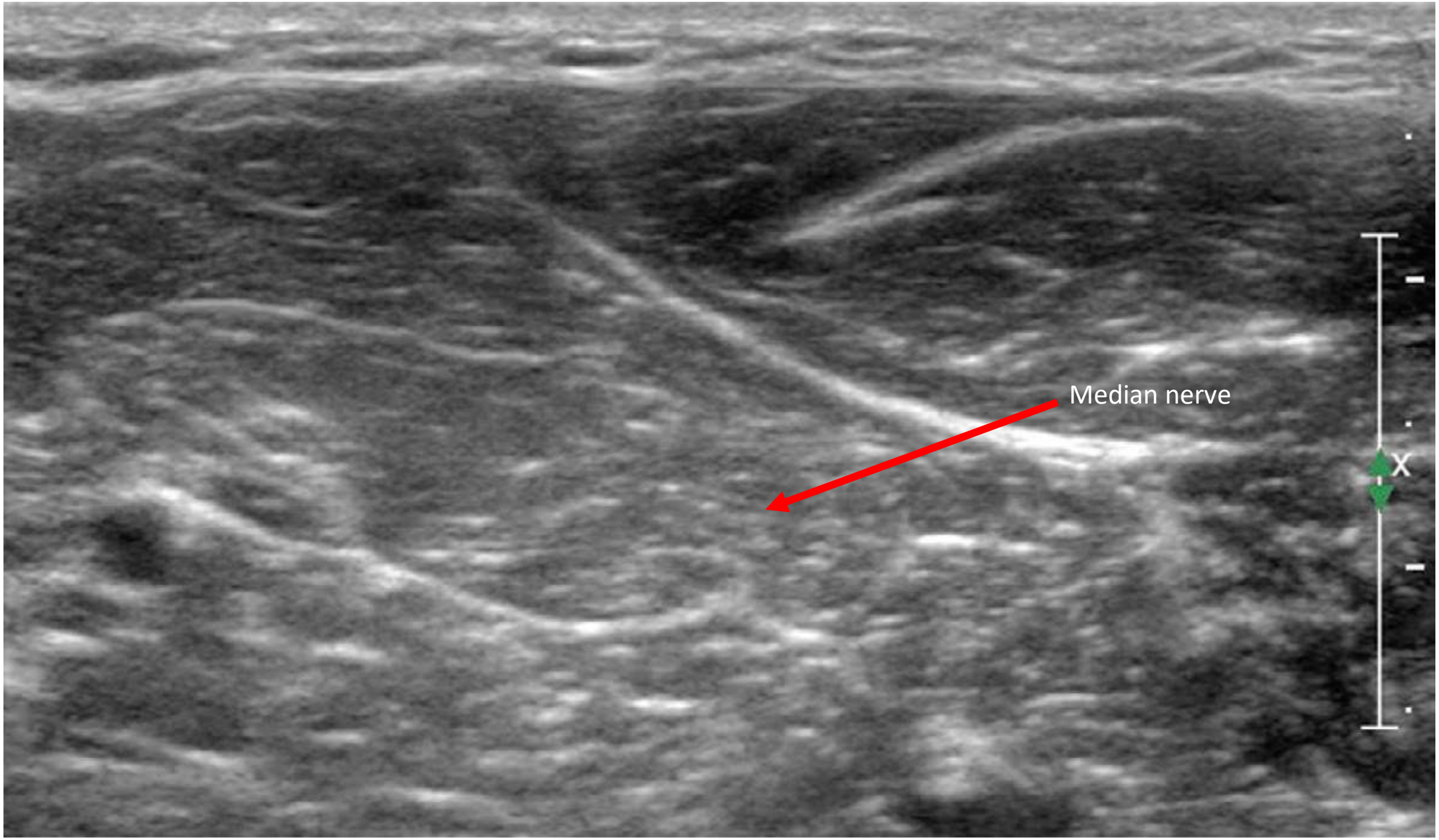
Median nerve
X

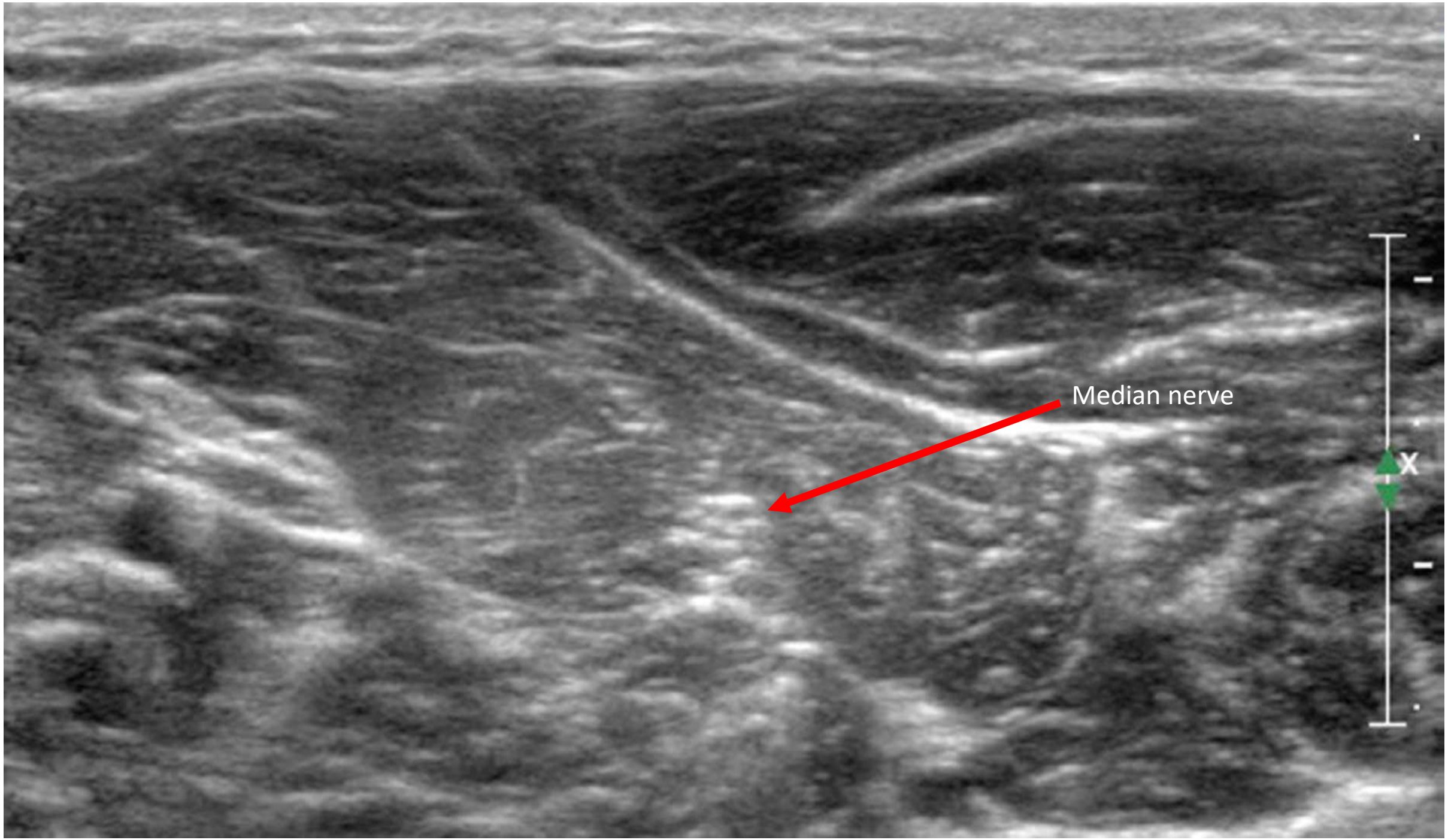
Median nerve
X

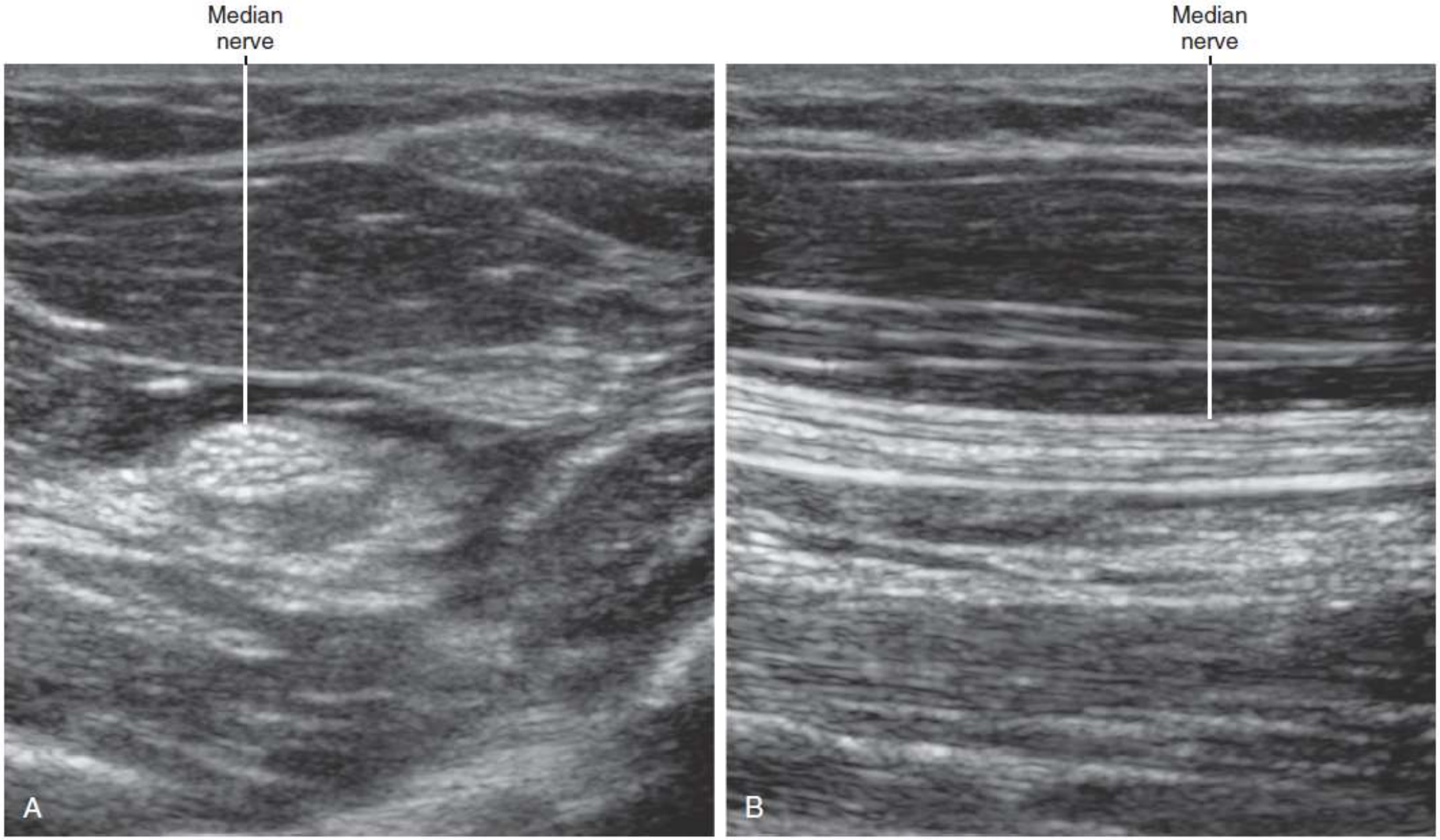
Median
nerve
A
Median
nerve
B