

Nerve blocks in pediatrics

F.Mosaffa

Akhtar hospital, SBMU

Key points

- Regional anaesthesia in children has many welldocumented benefits.
- Advances in ultrasound technology have enabled practitioners to perform regional blocks in children with greater accuracy.
- Central neuraxial blocks have been progressively replaced by peripheral nerve blocks.
- Large retrospective studies and data from a prospective registry suggest that regional anaesthesia is a viable and safe option for postoperative pain relief in children

The benefits of RA in children

- reduced opioid consumption;
- reduced incidence of postoperative nausea and vomiting;
- reduced postoperative pain scores;
- reduced incidence of respiratory complications
- When appropriate, peripheral nerve blocks (PNBs) should be offered as an alternative to neuraxial anaesthesia

Differences Between the Pediatric and Adult

Children do not understand the importance of lying still for a procedure.

- Children are not able to communicate or differentiate paresthesia, pain, or pressure on injection.**
- Anatomical structures are smaller and are situated more closely to each other and to the adjacent vessels.**
- Target nerves are more superficial to the skin.**
- There is a lower concentration of plasma protein binding, especially in young children**

- Regional anesthesia is usually performed in children under deep sedation or general anesthesia.

General Equipment

- Sterile skin preparation solution.
- Sponges/gauze.
- Drape.
- Marking pen and ruler for landmark identification.
- Selection of different sizes of syringes.
- A variety of needles with a selection of gauges for skin infiltration, drawing up 5 % dextrose, local anesthetics, sedation, or induction of general anesthetic.

Midazolam (IM/IV: 0.1–0.15 mg/kg up to 0.5 mg/kg, IV infusion with loading dose of 0.05–0.2 mg/kg over 2–3 min. Continuous infusion initiated at a rate of 0.06–0.12 mg/kg/h)

– Propofol (IV: 1–2 mg/kg for sedation, then 100–150 µg/kg/min infusion)

– *Short-acting opioids:*

• Fentanyl (IV sedation: 1–2 µg/kg, then 0.5–1 µg/kg/h IV infusion).

• Remifentanyl (IV: 2–18 years: 1 µg/kg over 30–60 s, then 0.05–0.1 µg/kg/min IV infusion). All sedation medication should be titrated to response.

– Several commonly used local anesthetics with different concentrations, as well as 50 mL bags or ampules of normal saline for drug dilution if necessary.

– All local anesthetics should be stored separately from the intravenous drugs.

Resuscitation Equipment

- Oxygen supply, nasal prongs, and face masks.
- Different sizes of Guedel airways, face masks, laryngeal masks, and endotracheal tubes.
- Laryngoscopes (Macintosh and Miller blades) and gum elastic bougie.
- Ambu bag (bagger).
- Suction.
- Various sizes of intravenous cannulae.
- Defibrillator

Resuscitation Drugs

- **Atropine** (0.02 mg/kg)
- **Epinephrine** (0.01 mg/kg)
- **Suxamethonium** (2 mg/kg)
- **Ephedrine** (1–12 years: 0.2–0.3 mg/kg; 12–18 years: 2.5–5 mg)
- **Glycopyrrolate** (5–10 µg/kg)
- **Intralipid® 20 %** (1.5 mL/kg bolus over 1 min followed by 0.25 mL/kg/min infusion; bolus dose can be repeated at 5-min intervals if there is no return of spontaneous circulation)

Monitoring

- Electrocardiogram
- Noninvasive blood pressure
- Pulse oximetry
- Capnography

Needle Tip Design

- blunt needles
- Long-beveled needles
- Tuohy needles 18G (20G catheter) or 20G (22–24G catheter)
- Special Sprotte[®] cannulas (Fig. 1.4) have a lateral “eye” with smooth edges to prevent shearing of the catheter. They also have an atraumatic tip.

Tohy





Needle Gauges

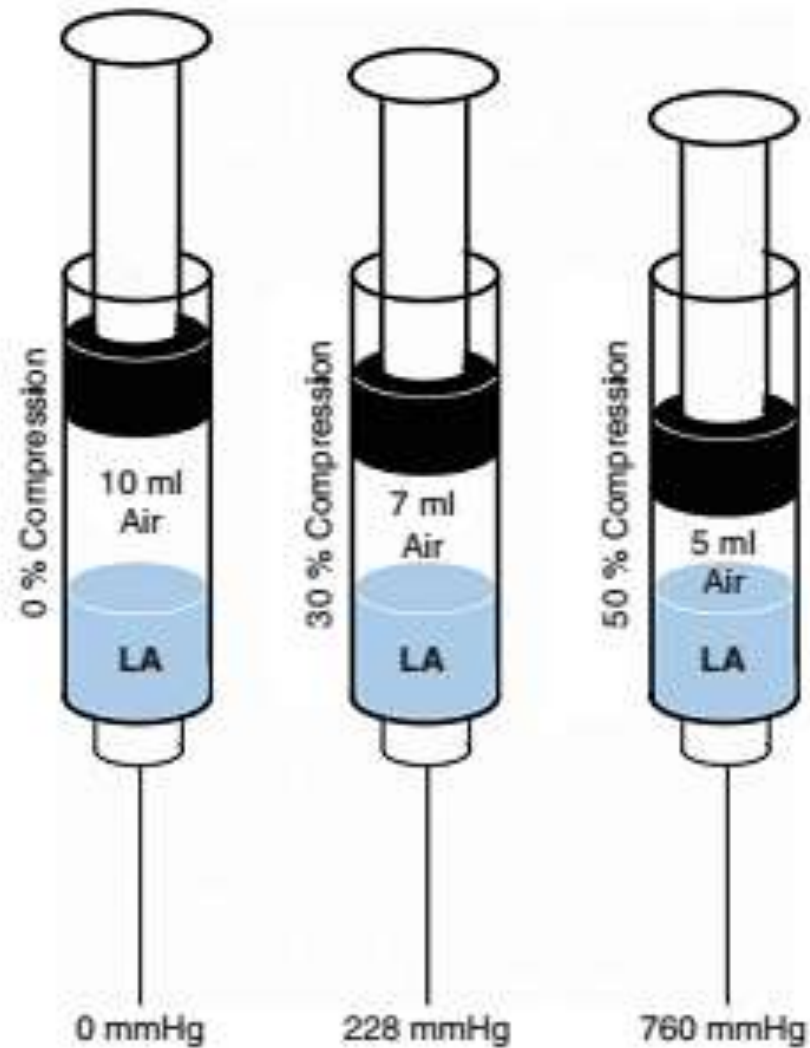
- 22G insulated needle for single-shot peripheral nerve blocks,
- For catheter insertion, 20–21G and 24G catheters with 18G and 20G Tuohy needles,

Injection Pressure Monitoring

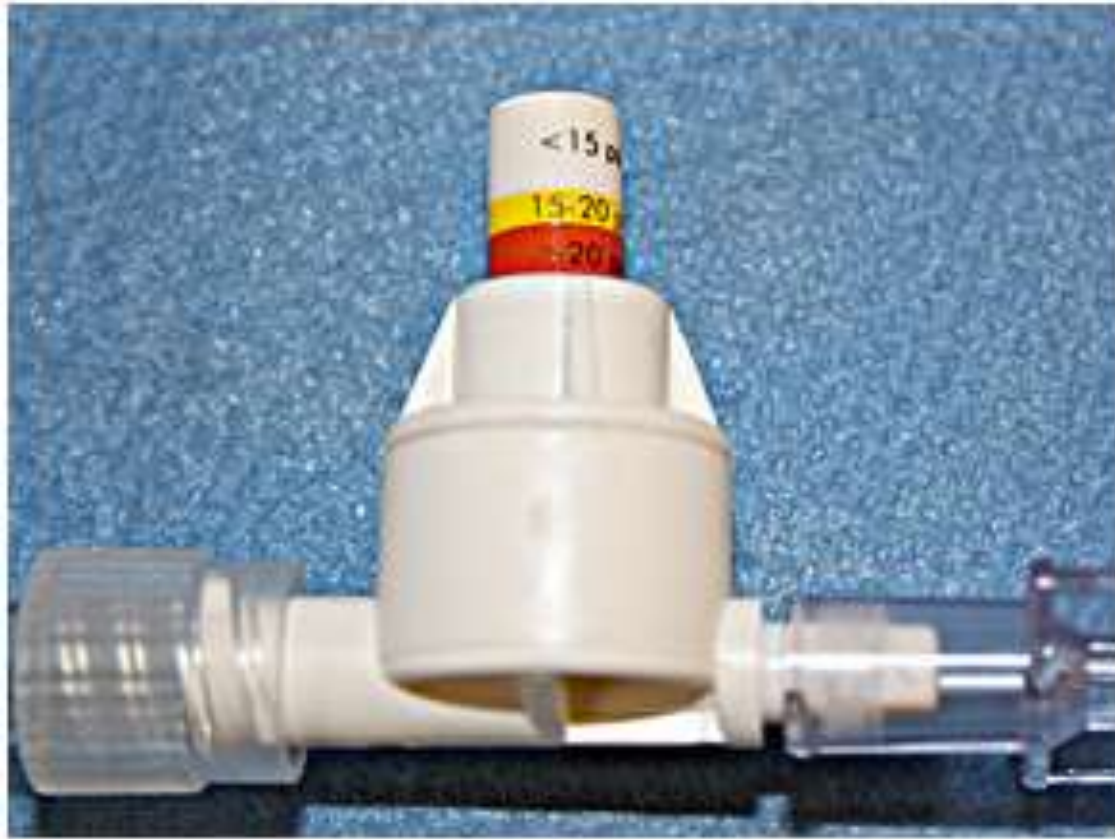

Fig. 1.8 Commercially available single-use, in-line pressure monitor for monitoring injection pressure during peripheral nerve blockade

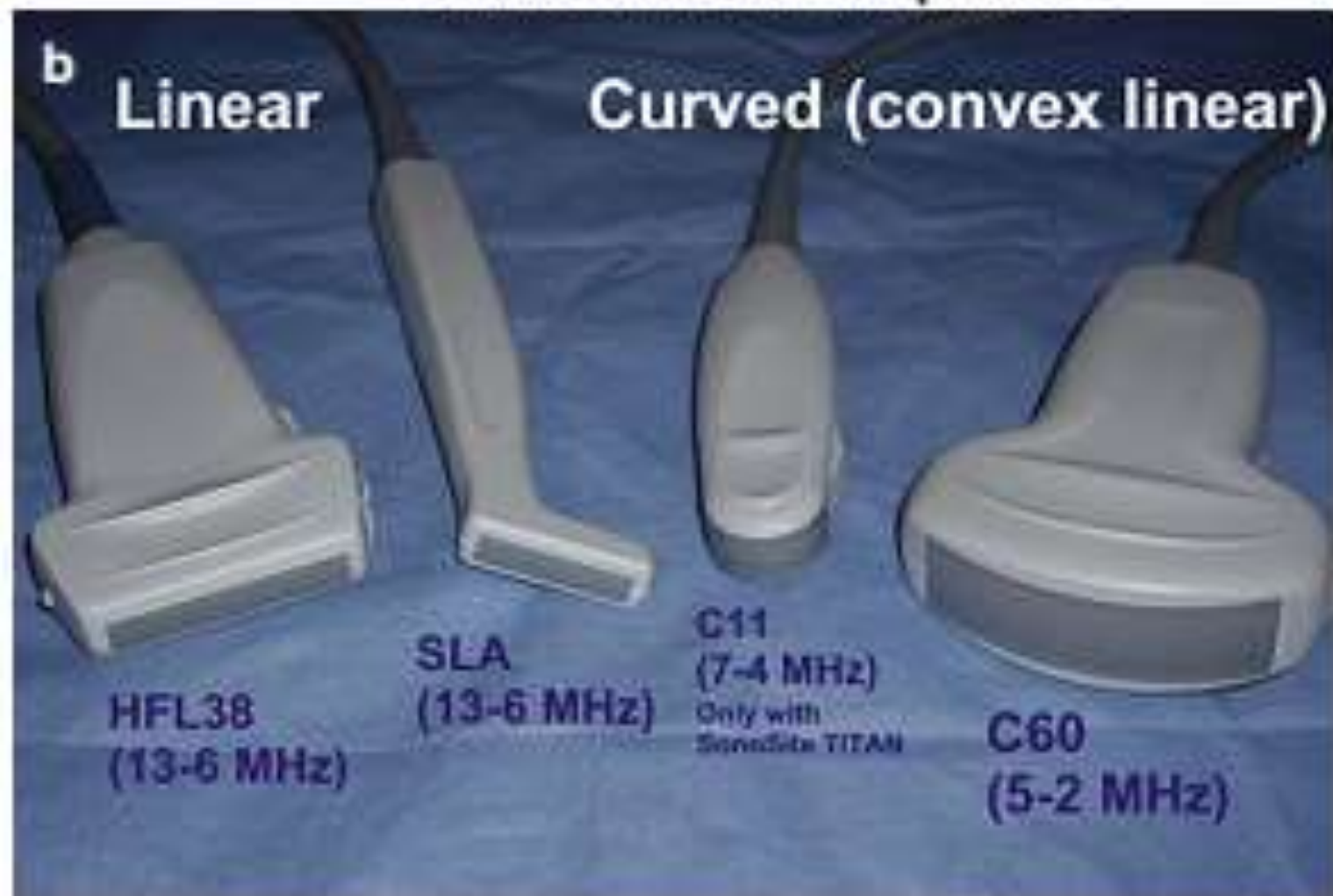
Pressure monitoring



US as a diagnostic tool

- aid in visualising anatomical structures
- Decreasing local anesthetic volume
- prevent the need for the use of a PNS and reduce the potential for tissue damage in skeletal or connective tissue disorders, such as epidermolysis bullosa and syndactyly
- increases precision and success rate, enables a faster onset of block

Ultrasound beam planes




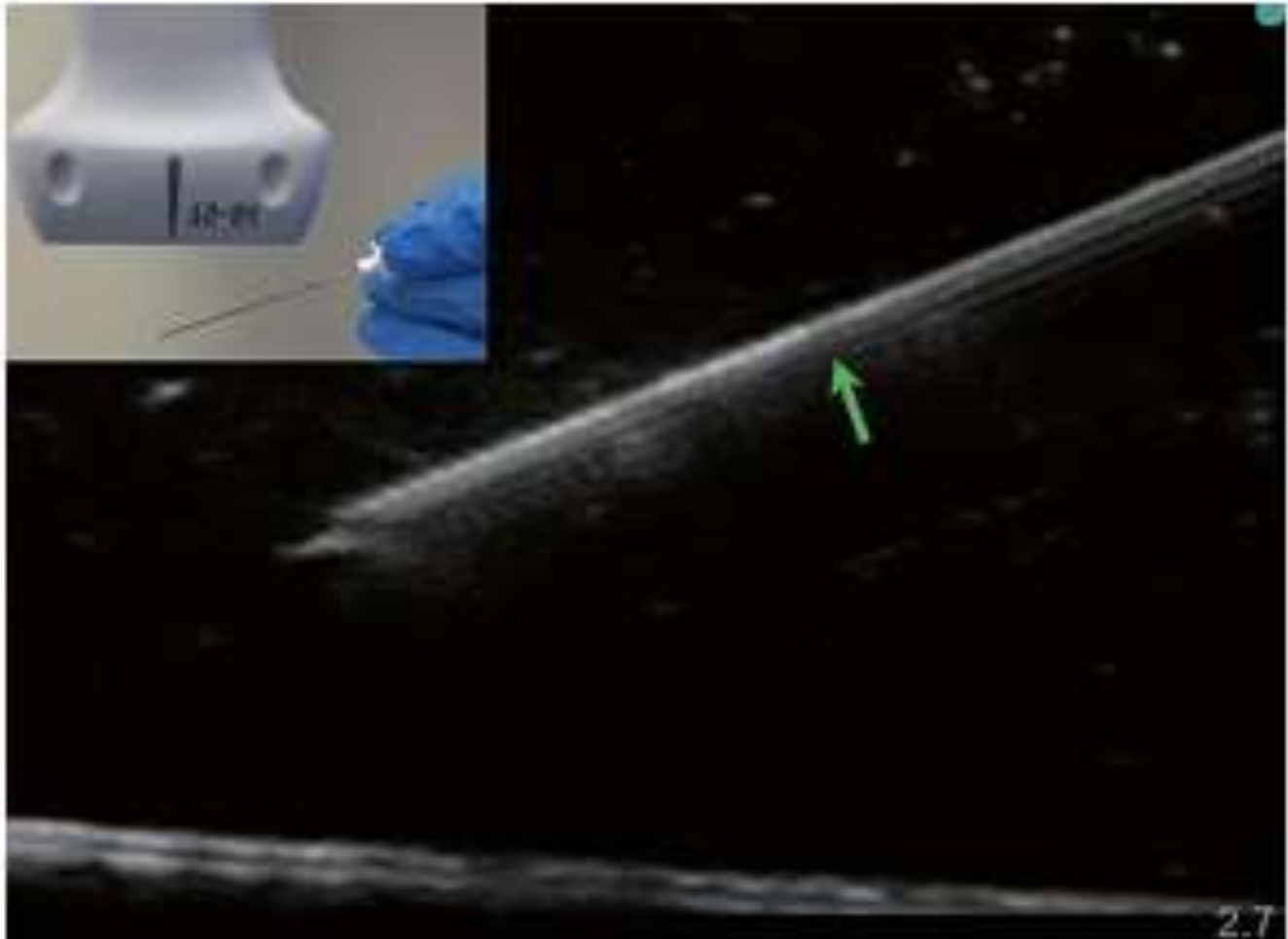


Fig. 4.4 Tilting (a), rotating (b), and manipulating (c) the alignment of the ultrasound probe is necessary to visualize the tip of the needle. The *line* on the paper indicates the original axis of the probe

Needling Technique



- **The in-plane (IP) technique**, maintaining the needle path along the transducer long axis, is the **technique of choice in children**

Complications

- ***Sedated or anesthetized*** during block performance.
- Many children will not be able to report ***paresthesia*** regardless of alertness
- An inability to report and detect ***early CNS signs of toxicity***
- Need to carefully watch ***cardiac signs*** of local toxicity

Congenital and pre-existing disease

Peripheral Neuropathy

e.g., diabetes, multiple sclerosis, peripheral vascular disease

CNS Disorders

e.g., multiple sclerosis, post-polio syndrome

Maintaining a standard of care during regional anesthesia practice:

Preoperative patient selection

Appropriate parental and parent consent

Using appropriate equipment and technique

Monitoring regional anesthesia practice

Accurate and meticulous anesthesia documentation

Postoperative communication and follow-up visit

Relative contraindications

- Anatomical anomalies; technical challenges: small structures
- Preexisting progressive neurological disease; comatose states; sepsis; coagulopathy
- Lengthy procedures that outlast the duration of action of the local anesthetic

Absolute contraindications

- Parental and patient refusal
- Lack of experience and skills; lack of appropriate equipment (e.g., nerve stimulator, ultrasound, proper size of needle); lack of appropriate equipment for resuscitation and monitoring (e.g., oxygen, mask, drugs, etc.)
- Infection at the site of injection; allergy to local anesthetics; coagulopathy

Allergic Reactions

- Rare
- Mild local reactions (e.g., pruritus, erythema),
Antihistamine
- Mild but become systemic (e.g., nausea,
vomiting: +Corticosteroid
- True anaphylaxis (e.g., hypotension,
bronchospasm) :Advanced Life Support
guidelines, epinephrine (0.01 mg/kg s.c. or
i.m.)

Systemic Toxic Reactions

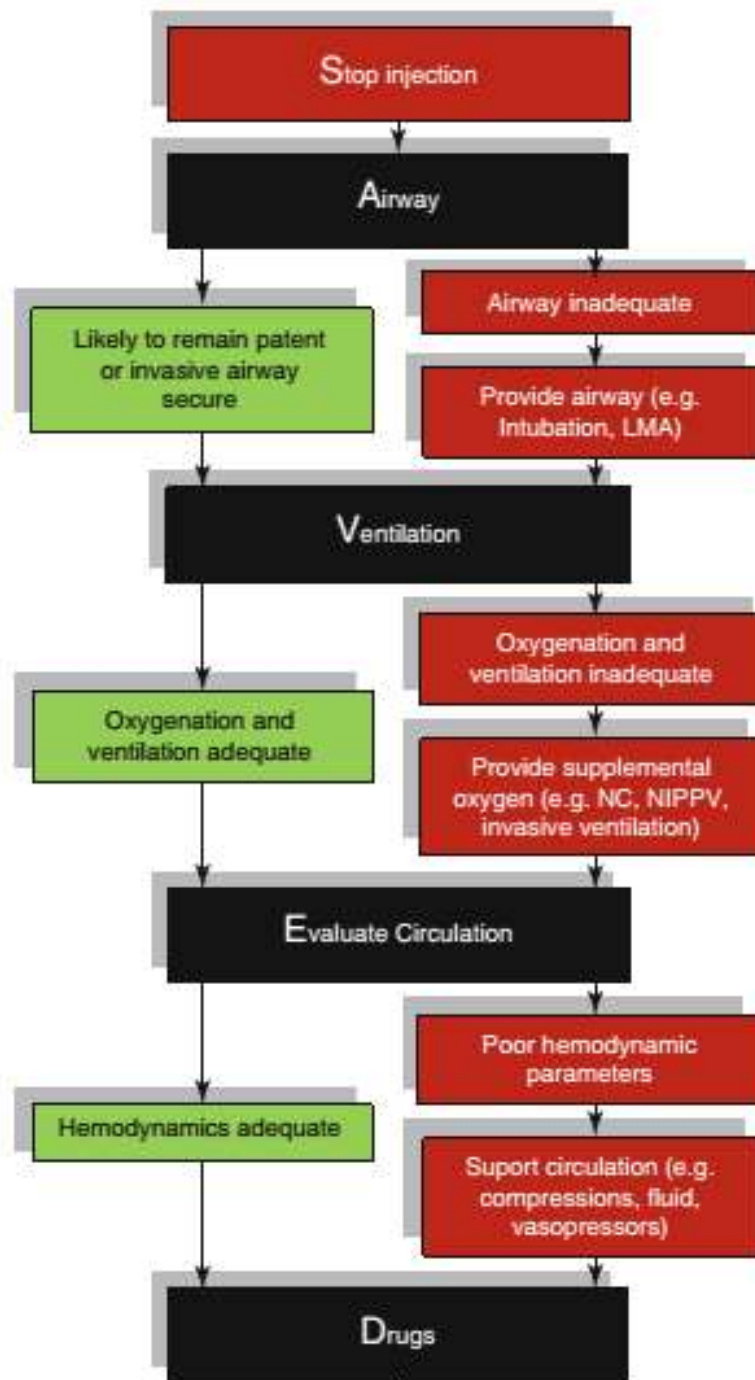
- so exceedingly rare
- less than 0.05 %
- The first signs may in fact be dysrhythmias, hypotension, or even cardiac arrest.
- Monitoring T wave height
- Adding adrenaline (epinephrine) (2-5 mic perkg) to LA to detect accidental intravascular injection in children is *controversial*.
- Should be injected slowly, in fractionated boluses (0.1-0.2 ml per kg), with intermittent aspiration and under ECG monitoring



Baseline ECG



Marked increase in T wave height after intravascular injection of bupivacaine with epinephrine



Use medications as appropriate:

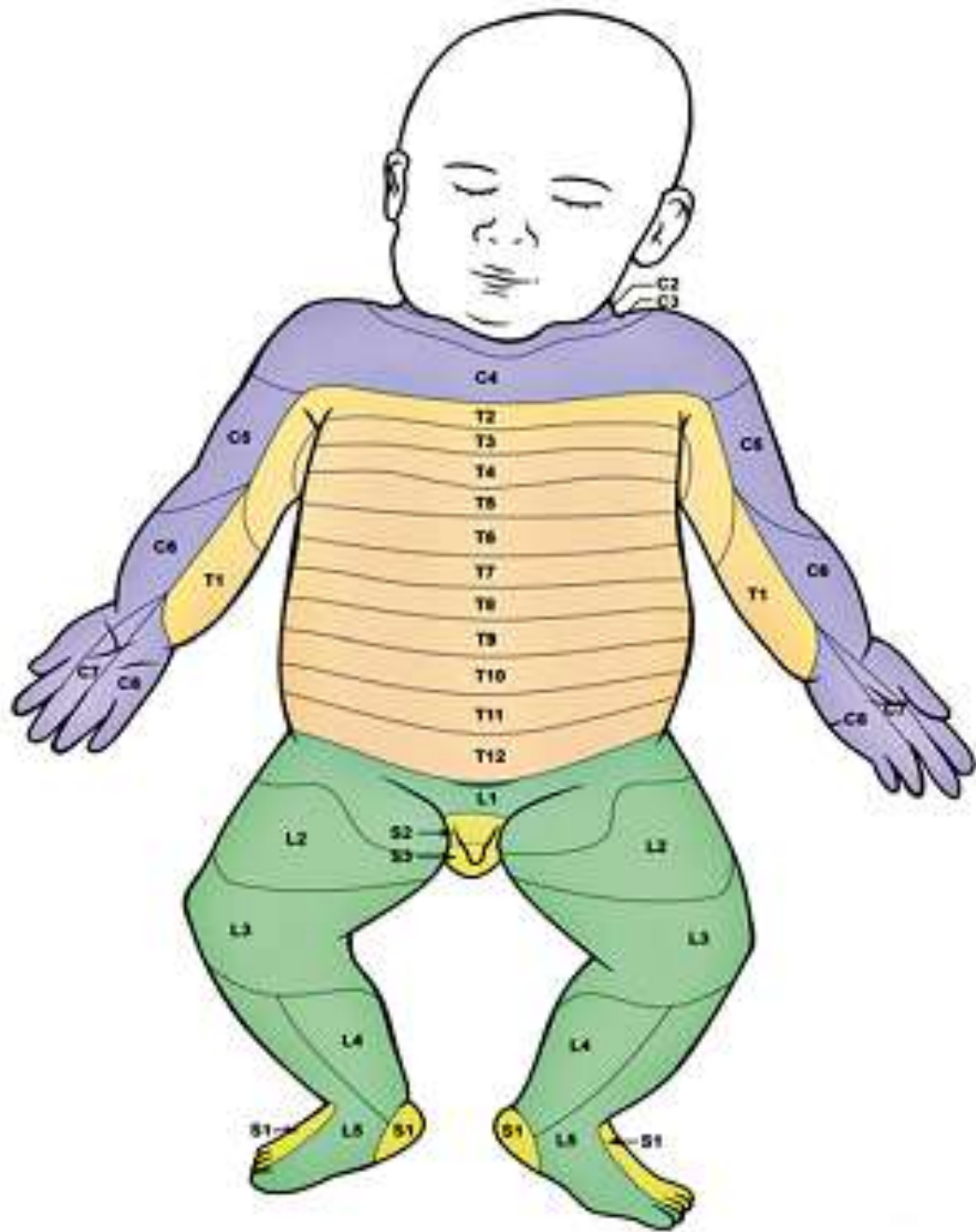
- **Lipid emulsion** (administer early) Bolus of $1.5 \text{ ml} \cdot \text{kg}^{-1}$ iv over one minute Infusion of $0.25 \text{ mL} \cdot \text{kg}^{-1} \cdot \text{min}^{-1}$
Repeat bolus q3-5 min to a total of $3 \text{ mL} \cdot \text{kg}^{-1}$
- **Bronchospasm/Edema** → antihistamines, corticosteroids, bronchodilators
- **Hypotension** → fluid, epinephrine ($10\text{--}100 \mu\text{g}$ aliquots)
- **Seizures** → midazolam ($0.05\text{--}0.1 \text{ mg} \cdot \text{kg}^{-1}$), propofol ($0.5\text{--}1.5 \text{ mg} \cdot \text{kg}^{-1}$), barbiturates (thiopentone [$1\text{--}2 \text{ mg} \cdot \text{kg}$])
- **Ventricular arrhythmias** → amiodarone (300 mg initially, followed by repeat 150 mg bolus 3–5 minutes later)

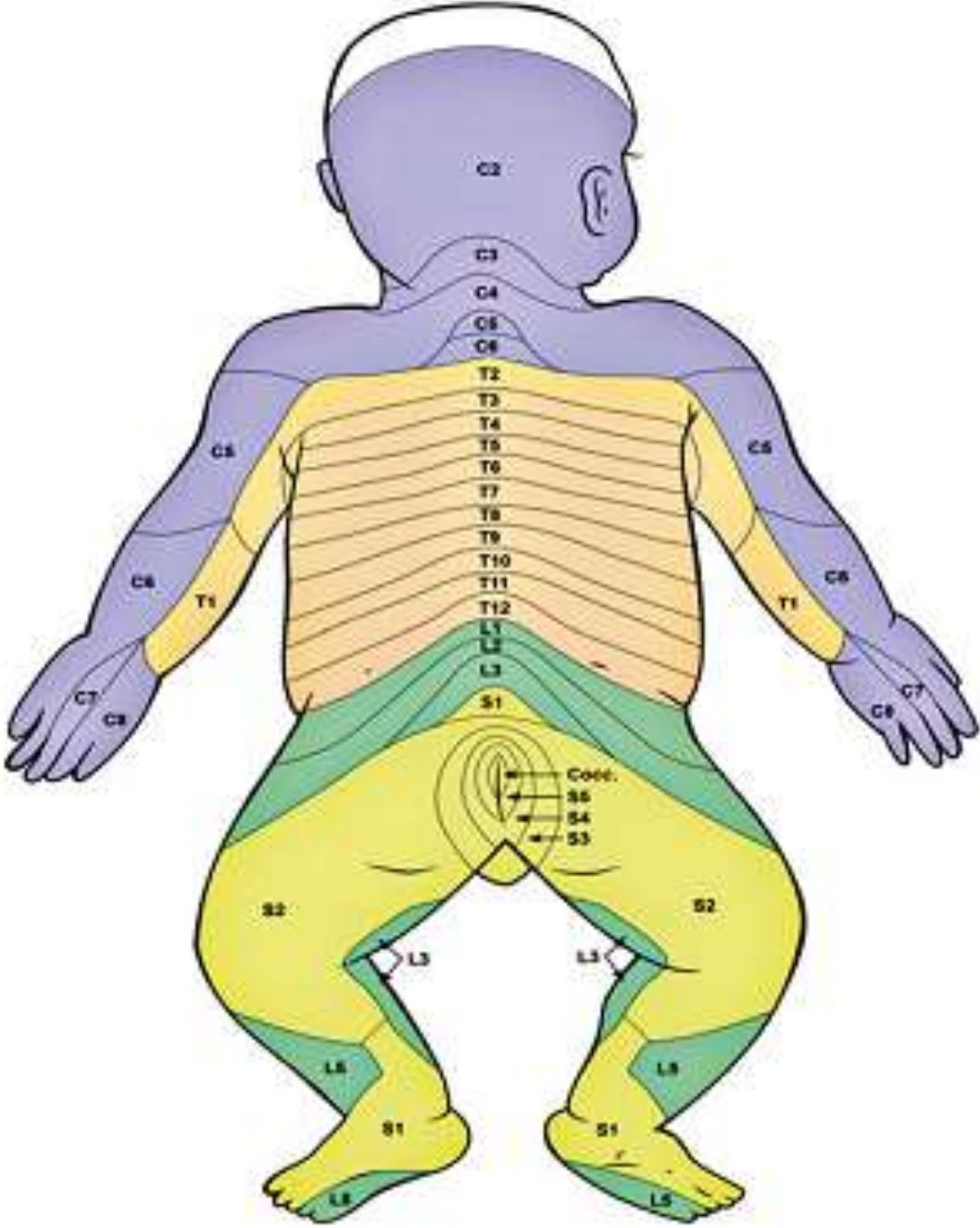
Acute compartment syndrome

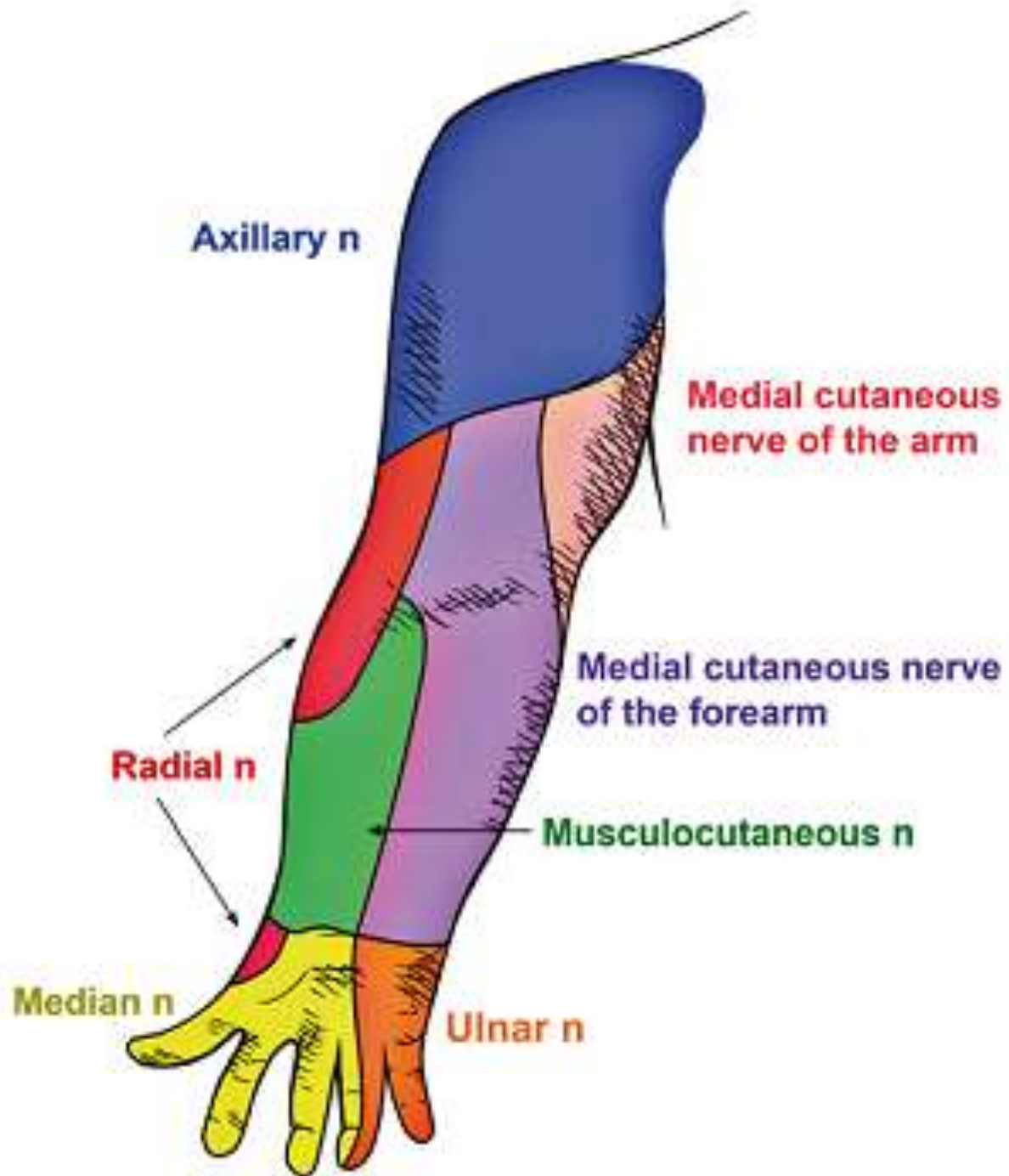
- A sudden increased pressure within a fascial compartment after a fracture, trauma or an ischaemic vascular event.
- A compartment pressure >30 mmHg is considered critical.
- only a few case reports of ACS in paediatrics have been published, and none of them showed a convincing link between RA and delayed diagnosis of ACS

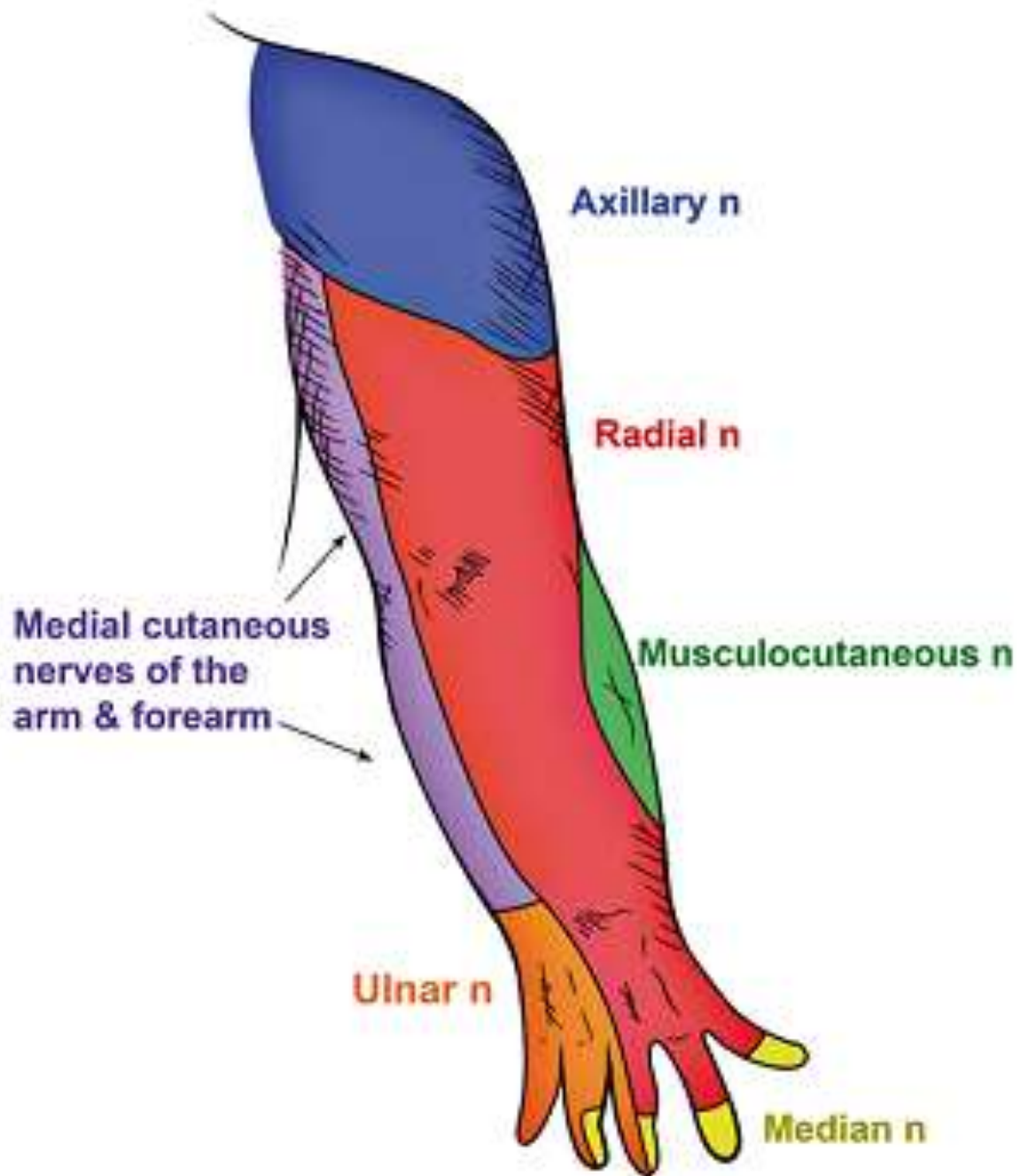
Methods/equipment for reducing the risk of nerve injuries

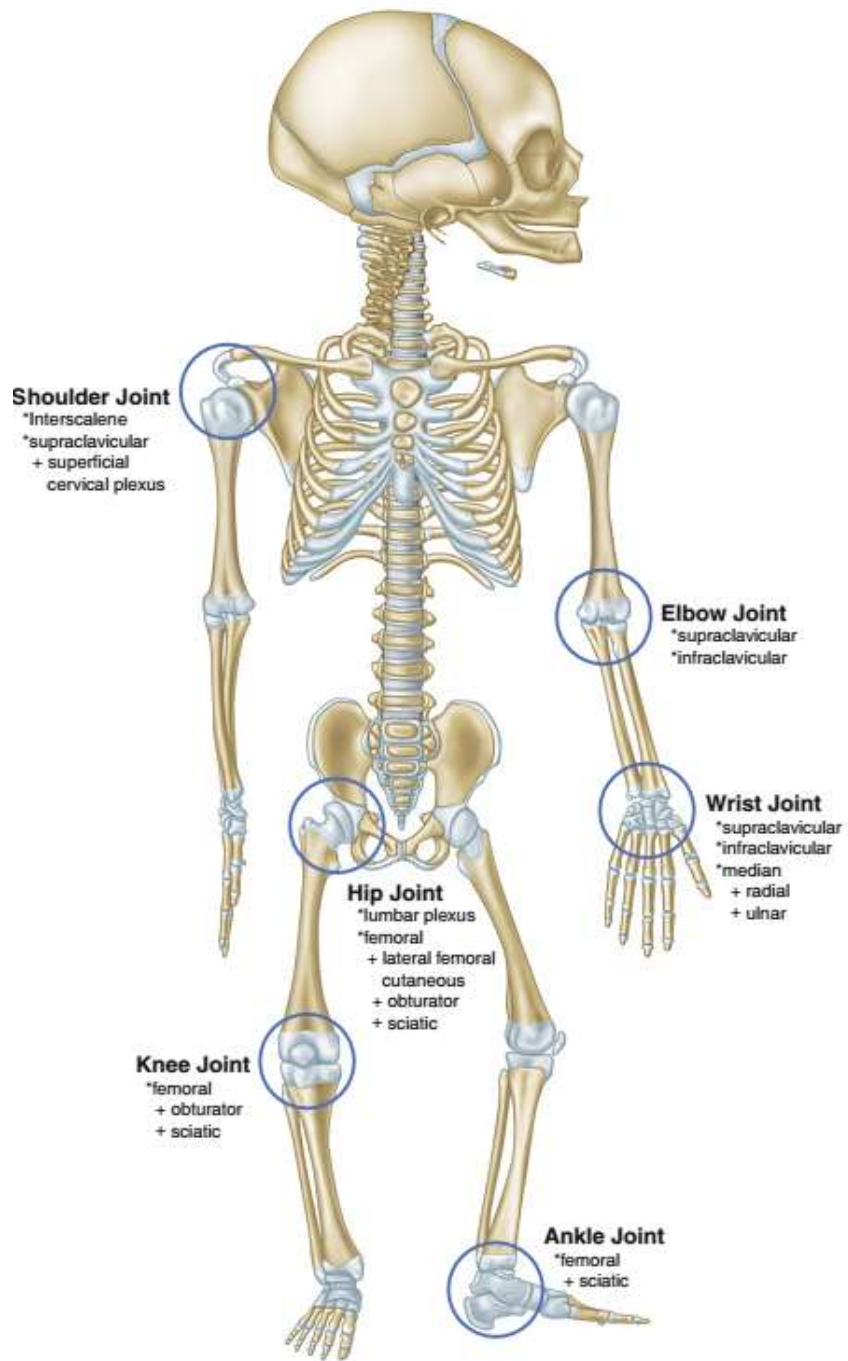
- **Needle type:** small gauge, short beveled
- **Patient:** awake with appropriate level of sedation
- **Nerve stimulation:** use accurate nerve stimulators and insulated nerve needles (current ≥ 0.2 mA)
- **Ultrasound:** direct visualization of nerves and surrounding structures by using high-resolution ultrasound equipment if available
- **Paresthesia:** injection should be stopped and needle repositioned if persistent
- **High injection pressure:** avoid rapid and high-pressure injections (pressure < 20 psi)
- **Local anesthetic:** avoid high concentrations (i.e., lidocaine 2 % or bupivacaine 0.75 %)



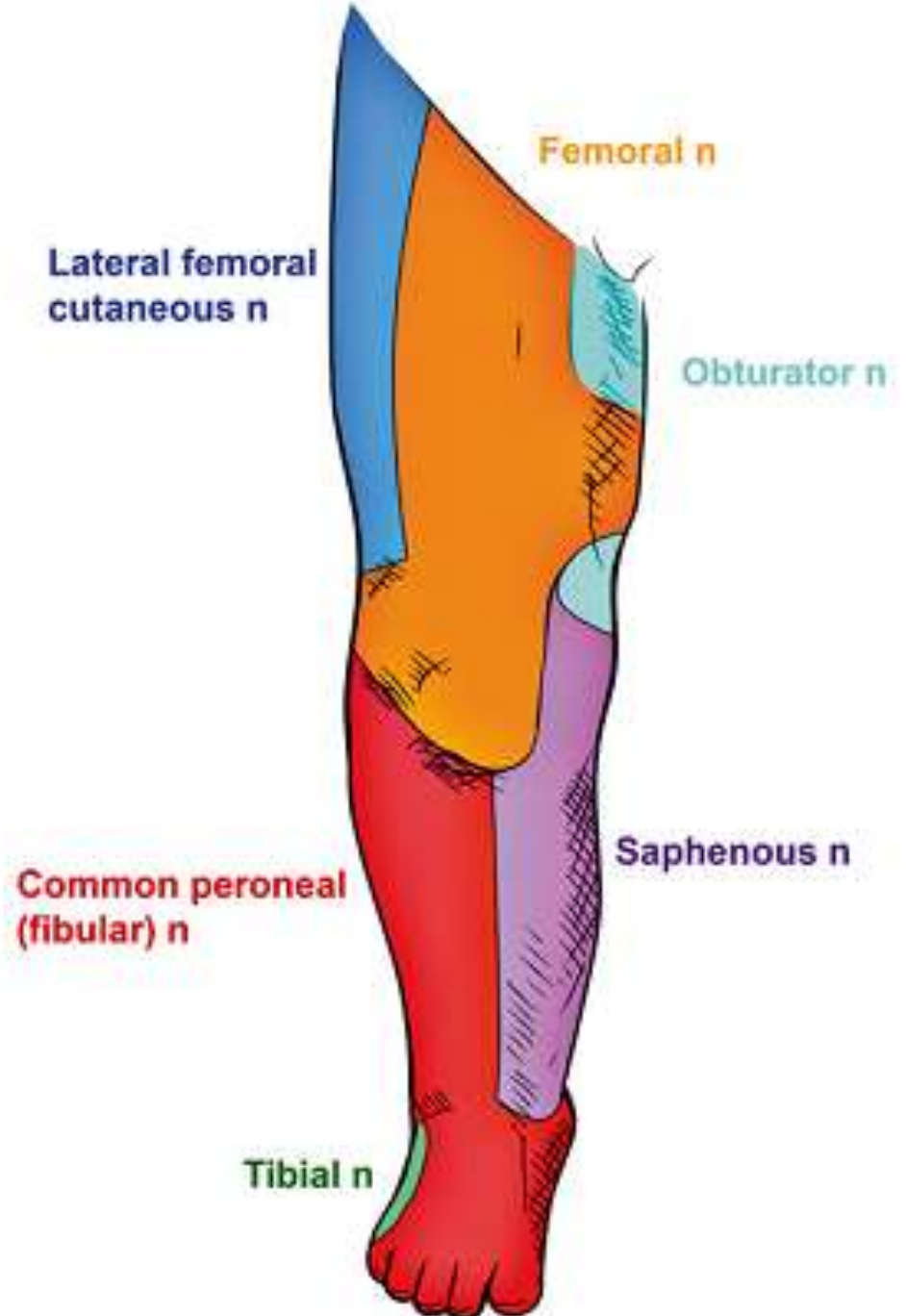


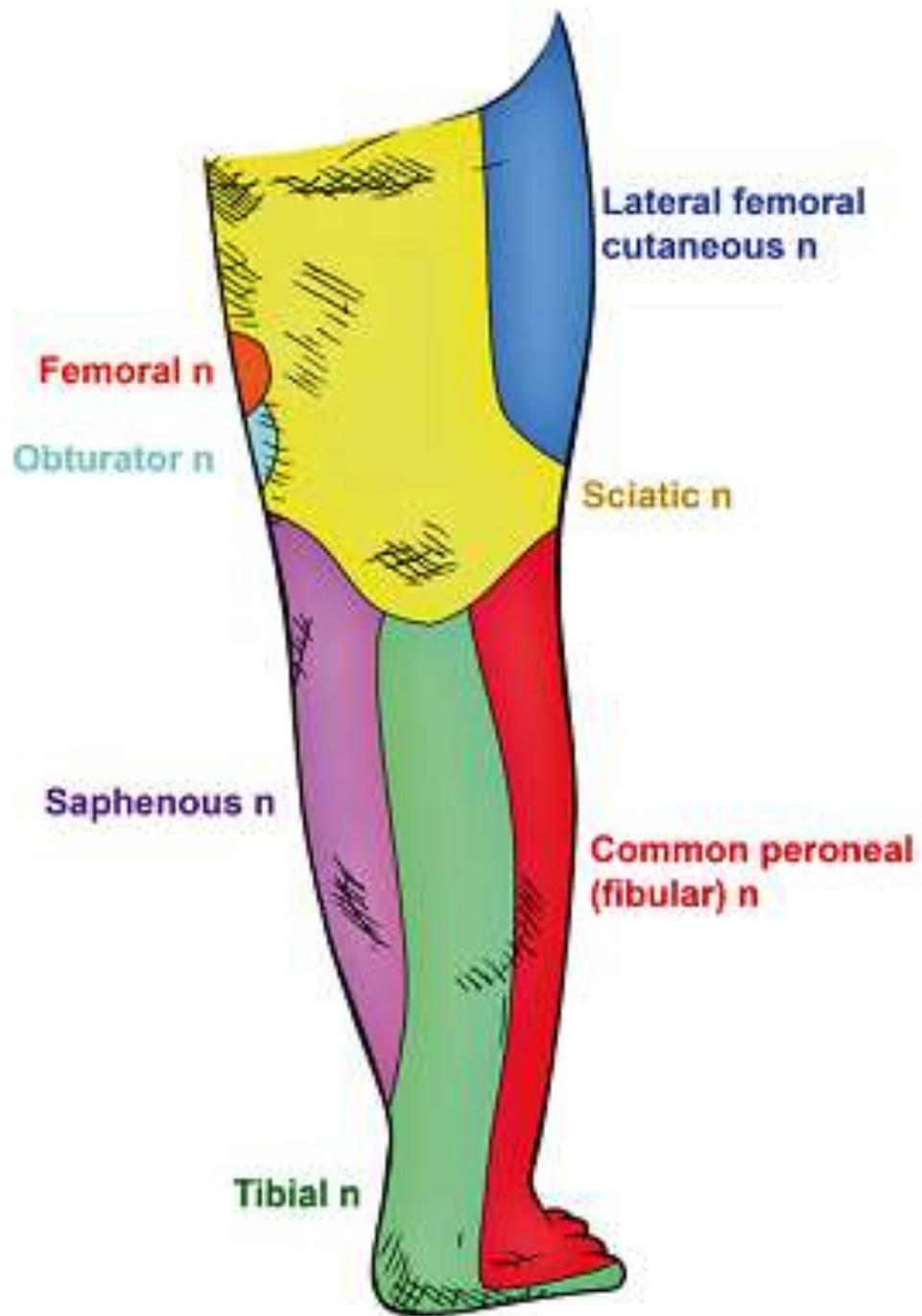






Location of the major joints





Upper Extremity Blocks

- The most common approaches to the brachial plexus in children include the **supraclavicular, infraclavicular, and axillary** approaches.

Supraclavicular approach

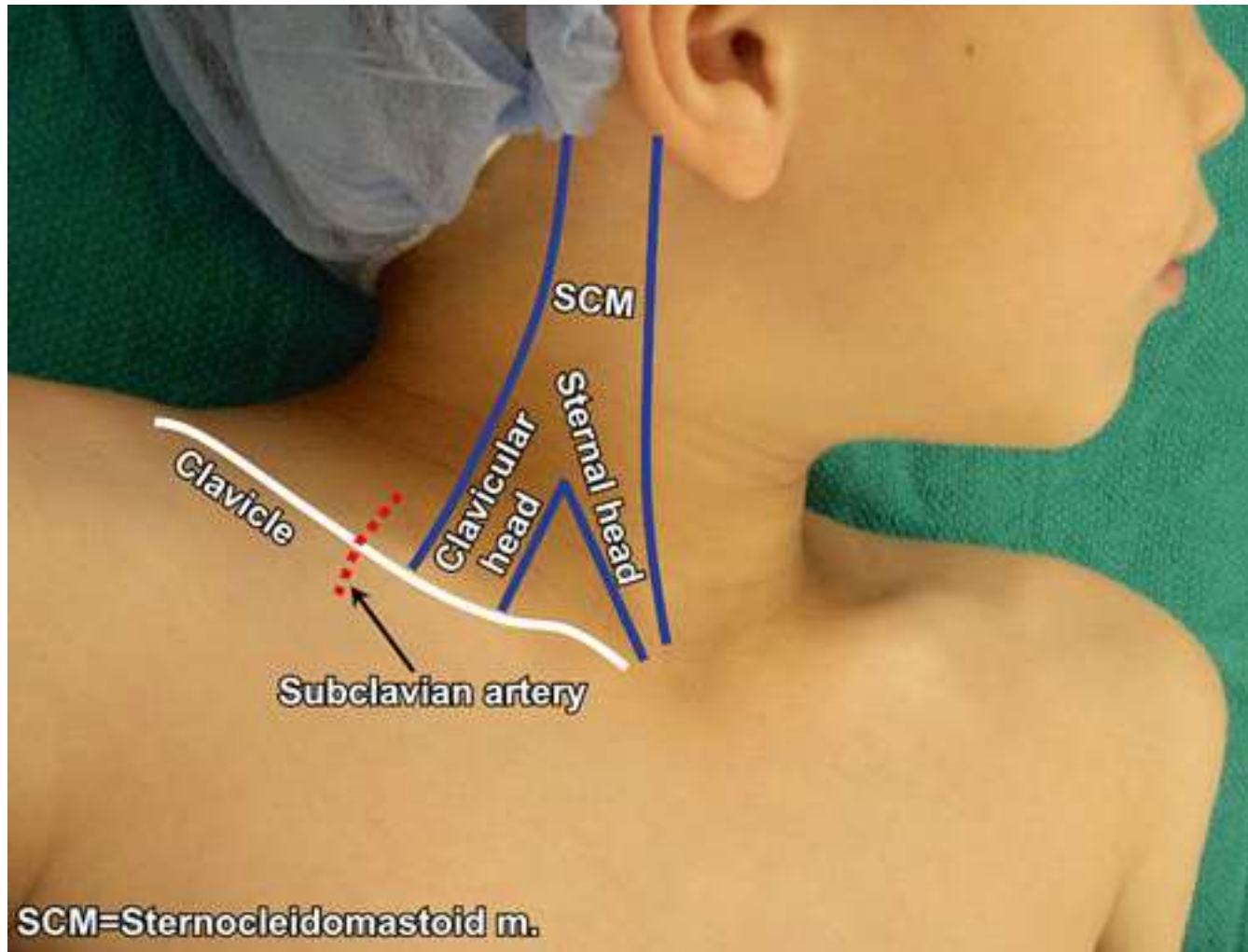
- **Indications**

- • Hand, forearm, and elbow surgery

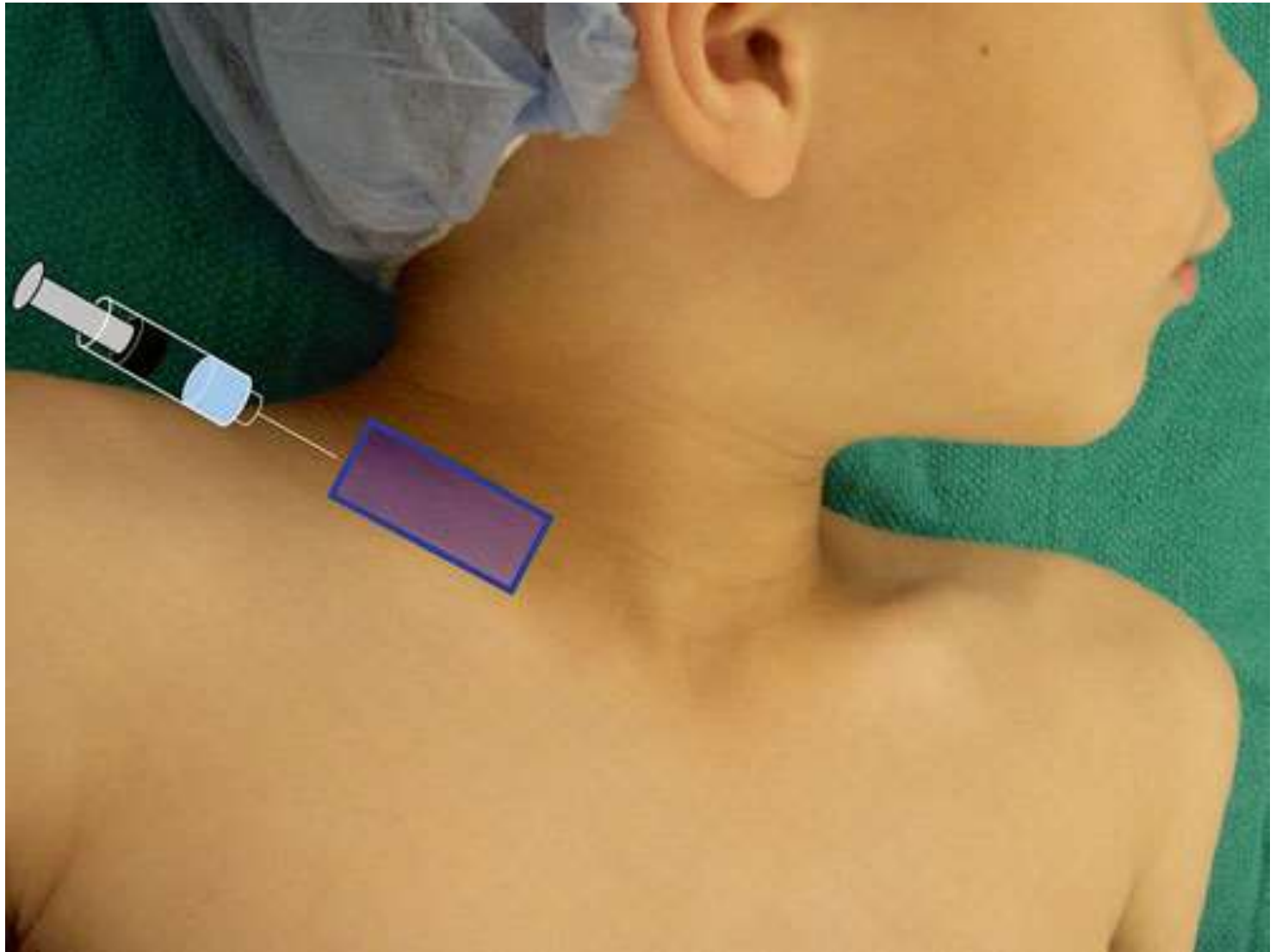
- **Local Anesthetic Application**

- 0.15–0.2 mL/kg.
- 0.25 % bupivacaine, 0.5 % bupivacaine,
- 0.2 % ropivacaine, or 2 % lidocaine

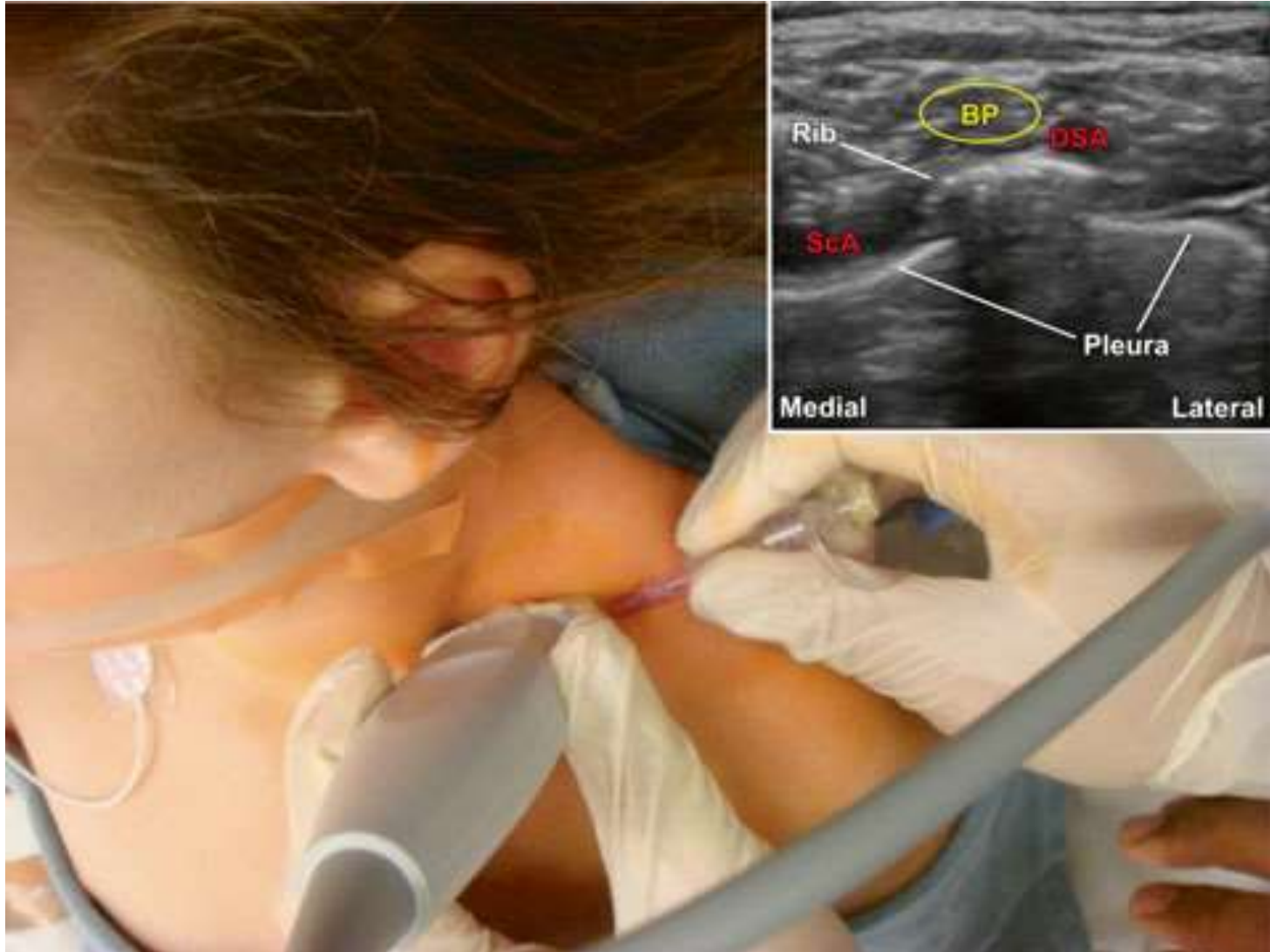
Supraclavicular approach



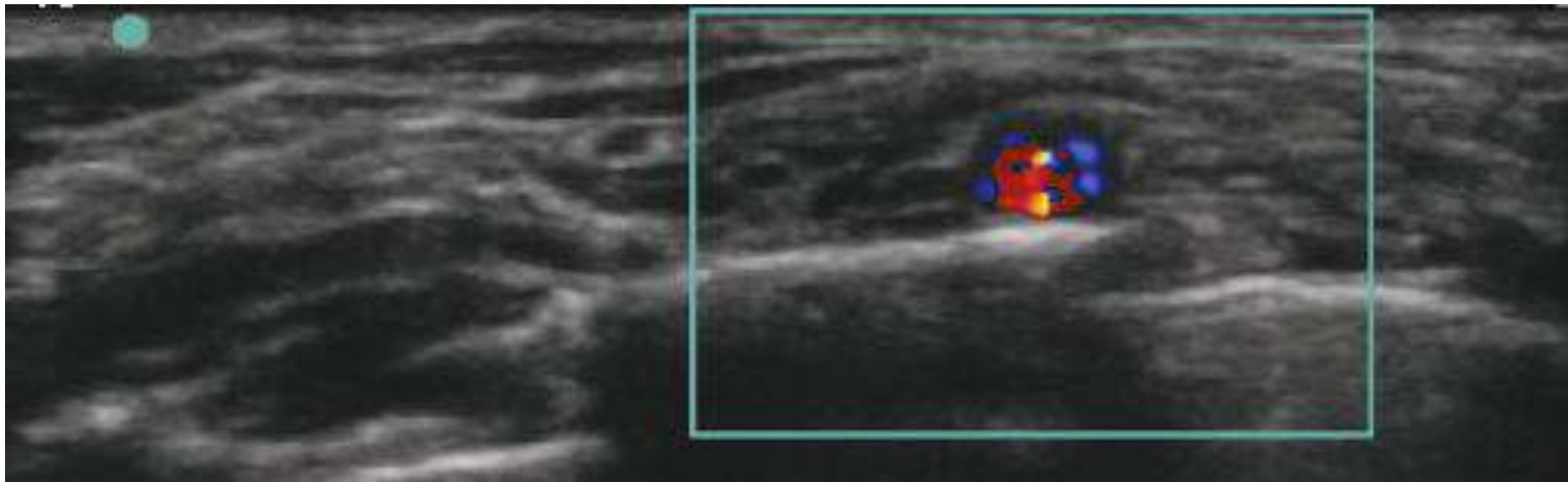
Supraclavicular approach



Supraclavicular Brachial Plexus Block



Supraclavicular block



- A 5-year-old female patient, 20.4 kg, presented for closed reduction percutaneous pinning of the left elbow.
- An ultrasound-guided supraclavicular nerve block was administered with a 20G needle ; 3.5 mL 0.25 % bupivacaine with epinephrine 1:200,000 was given for postoperative analgesia.
- Block duration was 6–12 h, and surgery lasted for 2 h and 8 min. Pain reporting following surgery was 0/10 (FLACC scale) at PACU admission and 0/10 (FLACC scale) at PACU discharge.

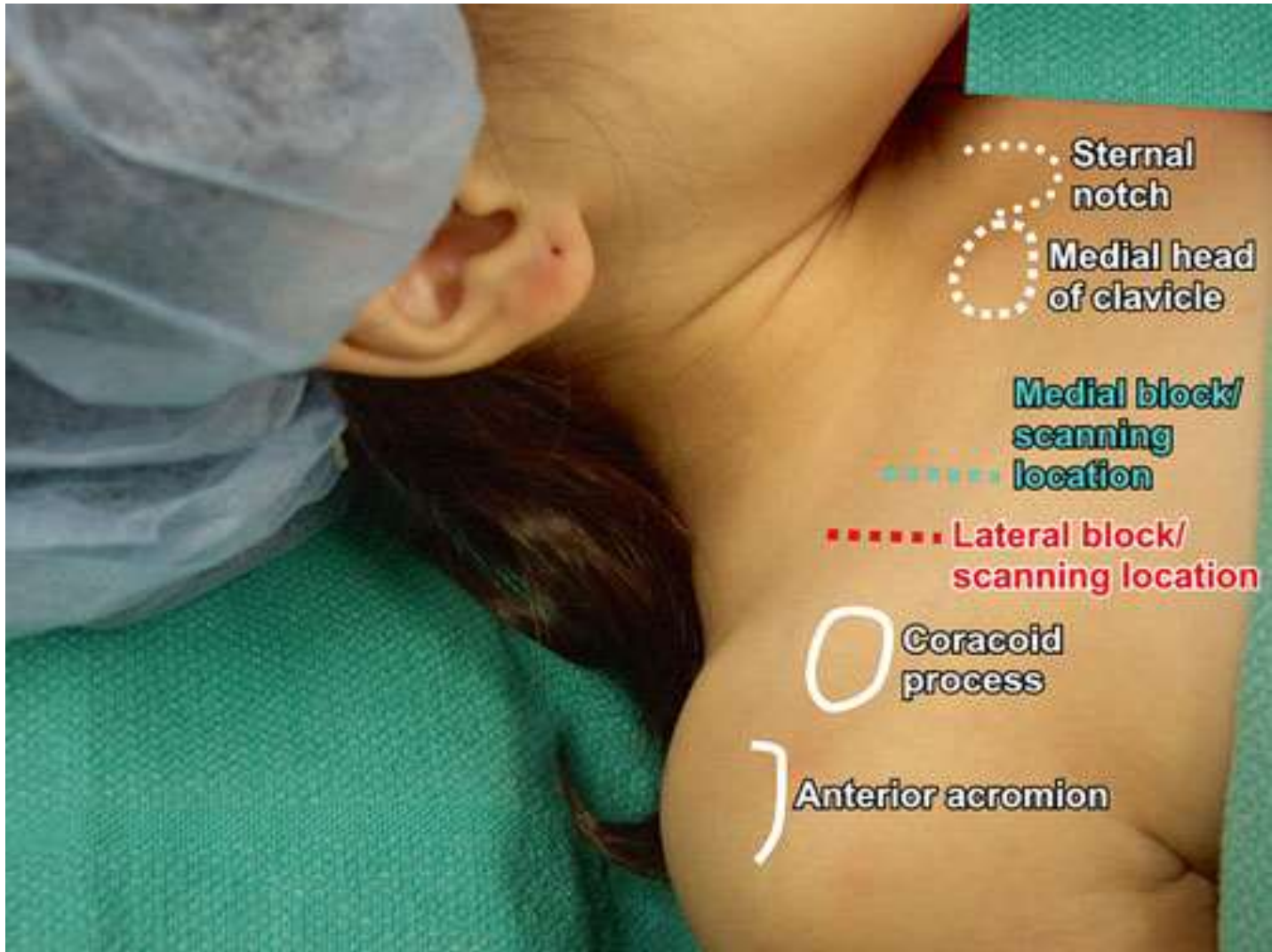
Infraclavicular approach

- **Indications**

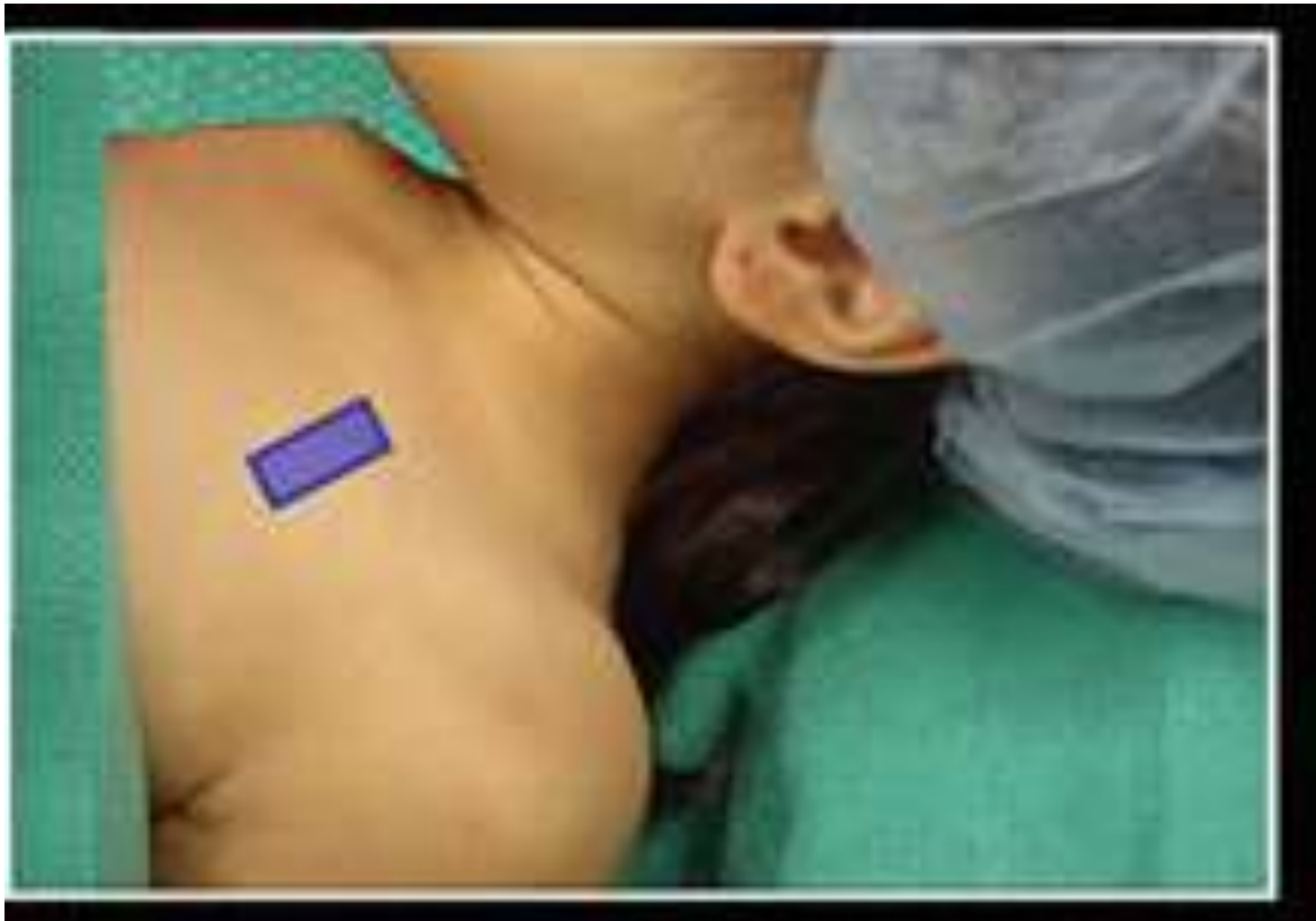Surgery of the upper arm including the proximal humerus, elbow, forearm, and hand.

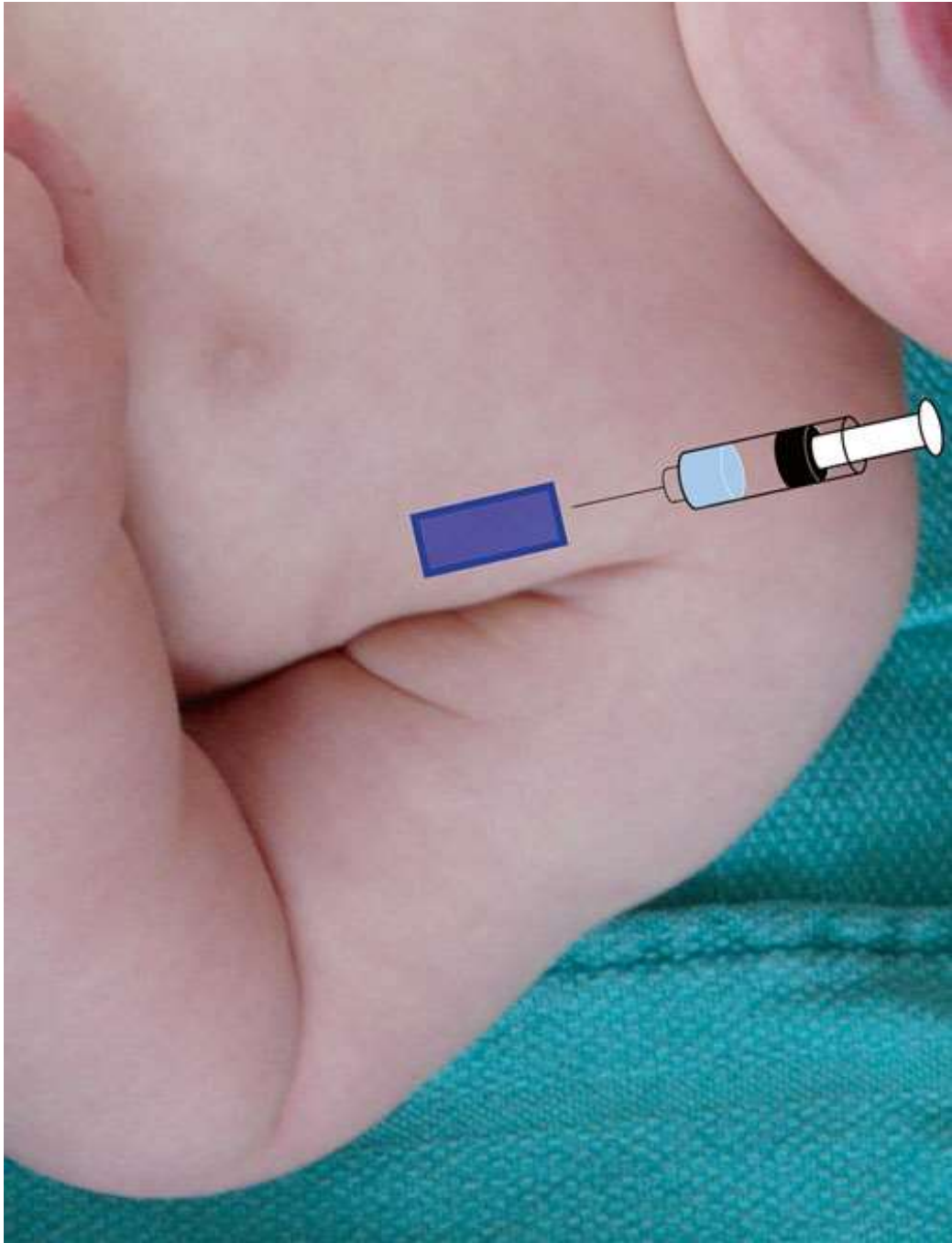
- 0.5 mL/kg of 0.2–0.5 % ropivacaine or 0.25–0.5 % bupivacaine

Infraclavicular approach



Infraclavicular approach

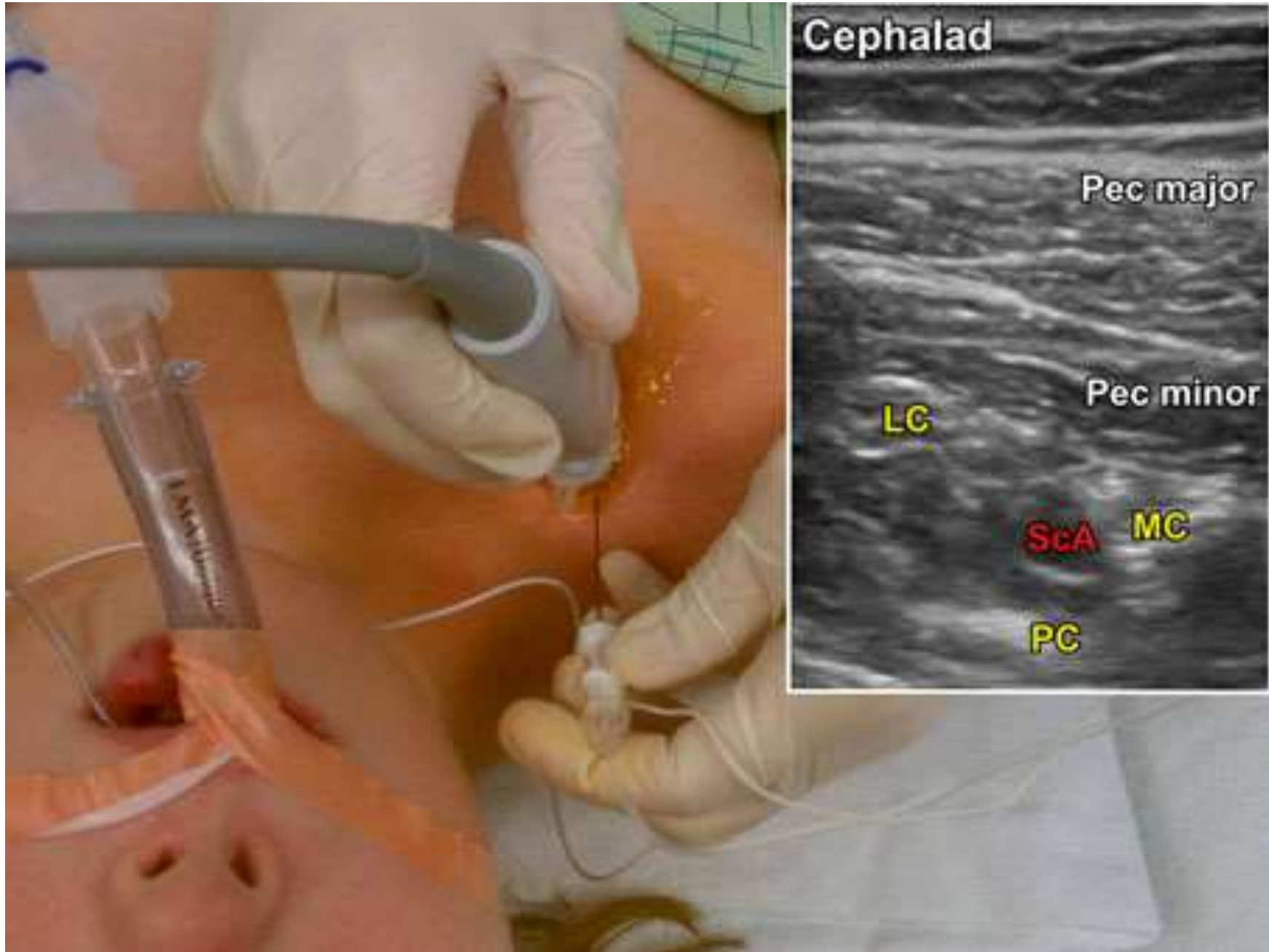




Clinical Pearls

- Place the linear probe medial to the coracoid process and inferior to the clavicle.
- After recognizing the axillary artery, look for the cords using an IP approach, with the tip of the needle aimed towards the posterior cord.
- Avoid using a medially positioned ultrasound probe (pleura)

Infraclavicular Block



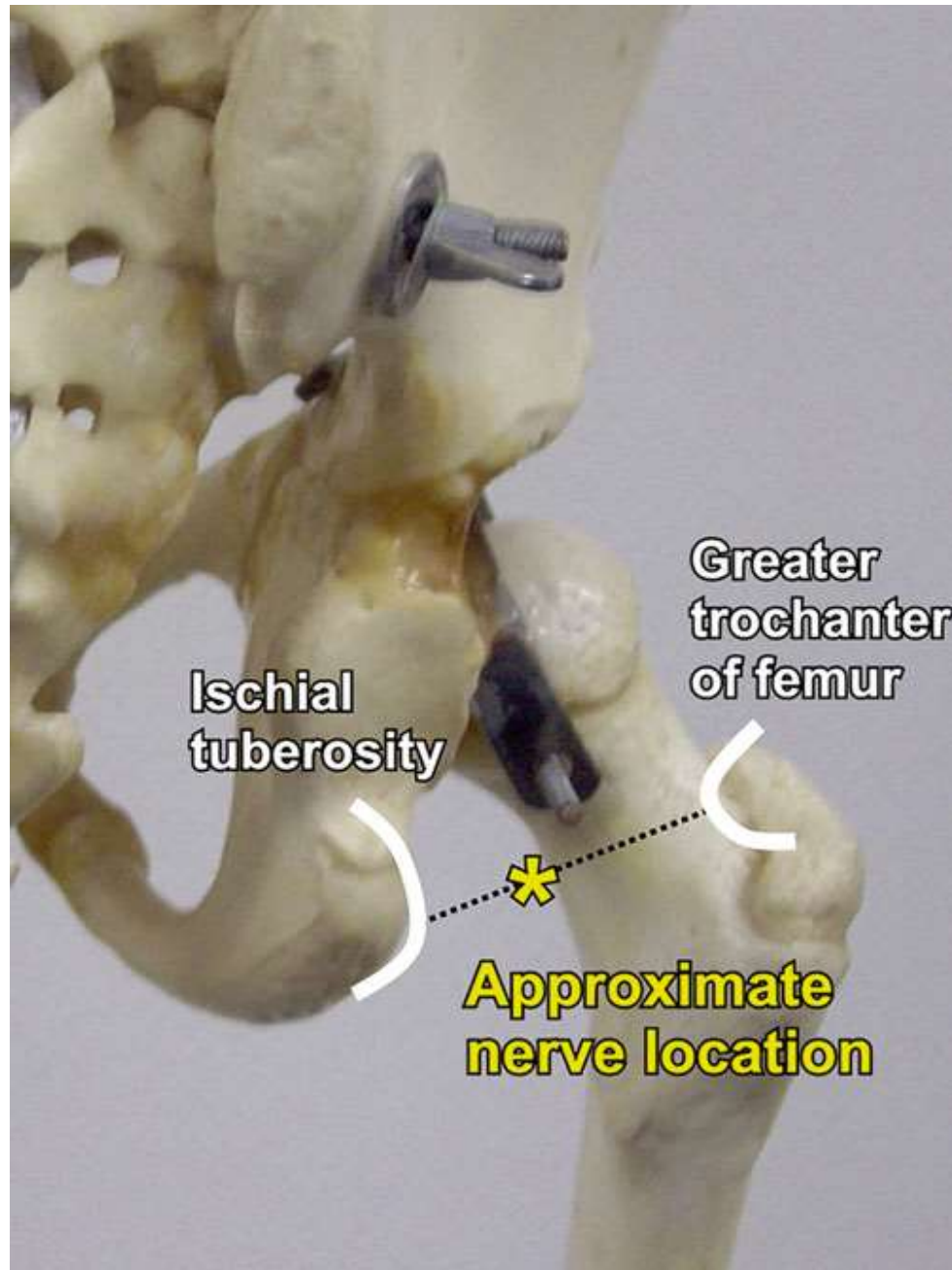
- An 8-year-old female patient, 50.3 kg,
- open reduction and fixation of the right small finger
- a 22G needle and 10 mL 0.25 % bupivacaine with 1:200,000 epinephrine

Block duration was 6–12 h;

Infragluteal/Subgluteal Sciatic Nerve Block Approach

- **Indications**
- • Sciatic nerve before bifurcation:
 - – Knee surgery (with supplemental blockade of the femoral nerve)
 - – Removal of leg implants
- • Sciatic nerve after bifurcation (may require supplemental blockade of the saphenous nerve):
 - – Surgery on the lower limb
 - – Foot and ankle surgery

- (1) 1 % lidocaine,
- (2) 0.5 % bupivacaine,
- (3) a mixture of equal volumes of 0.5 % bupivacaine and 1 % lidocaine,
- 0.5 mL/kg in patients <20 kg and 10 mL plus 0.25mL/kg 20 kg, up to 25 mL maximum injected volumes.

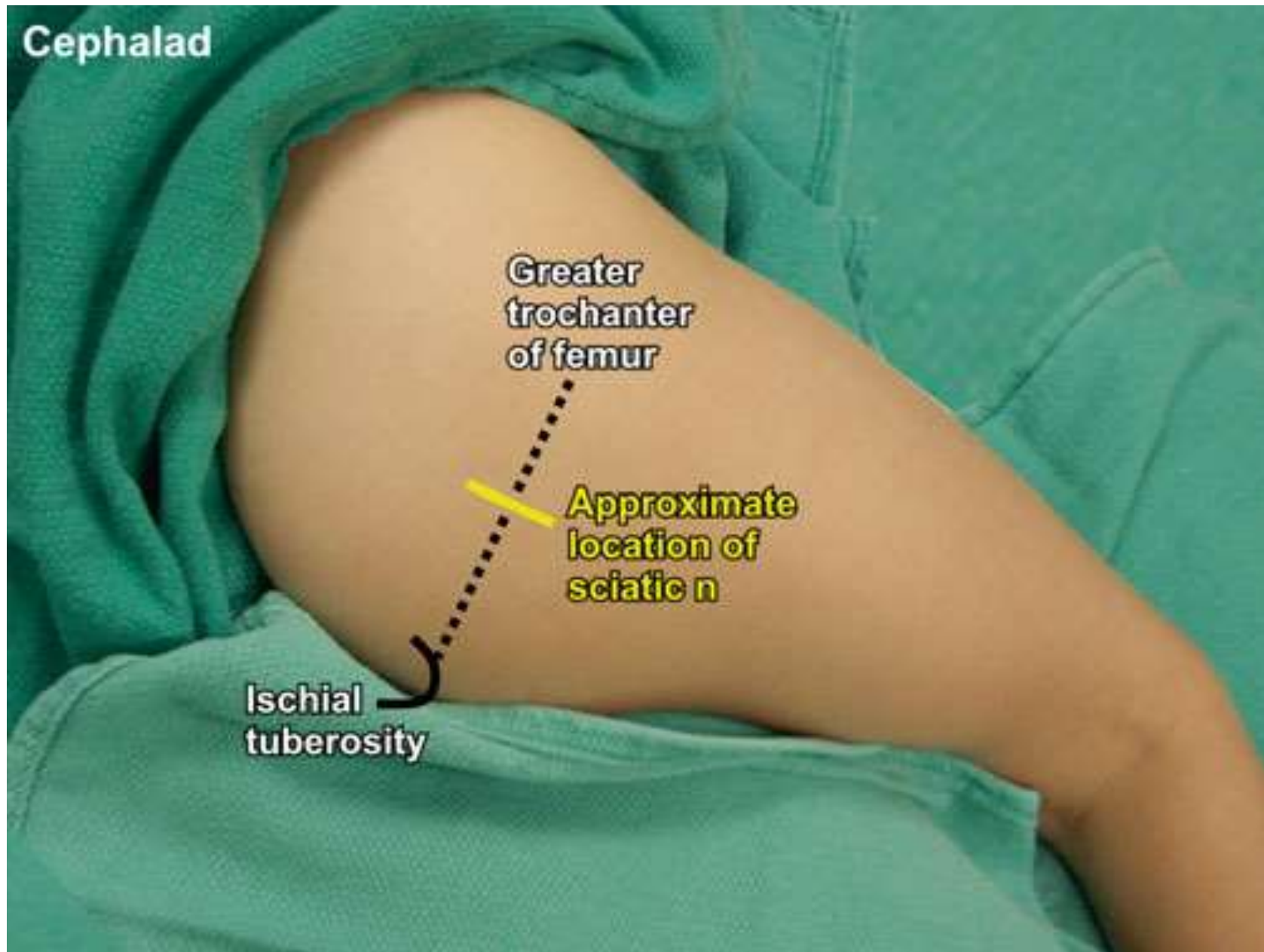


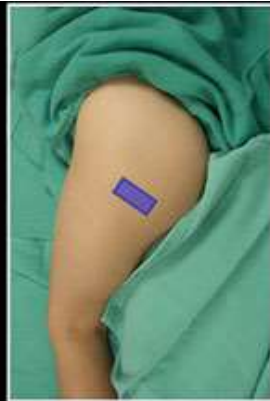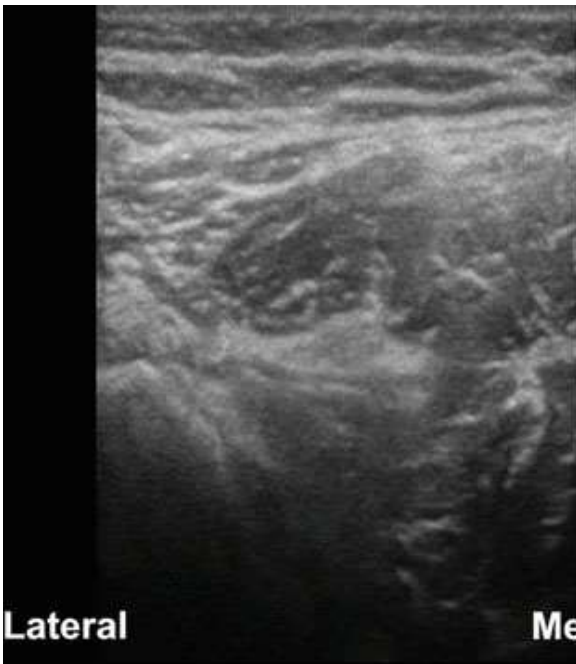
Cephalad

Greater
trochanter
of femur

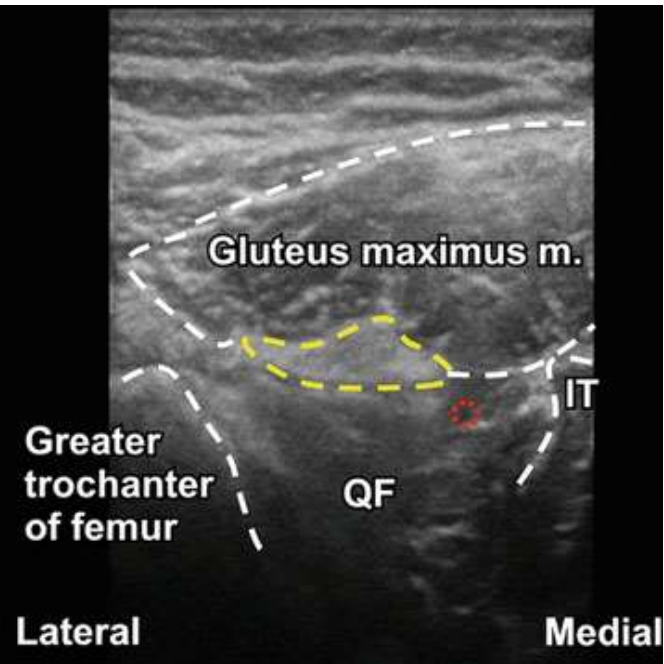
Approximate
location of
sciatic n

Ischial
tuberosity

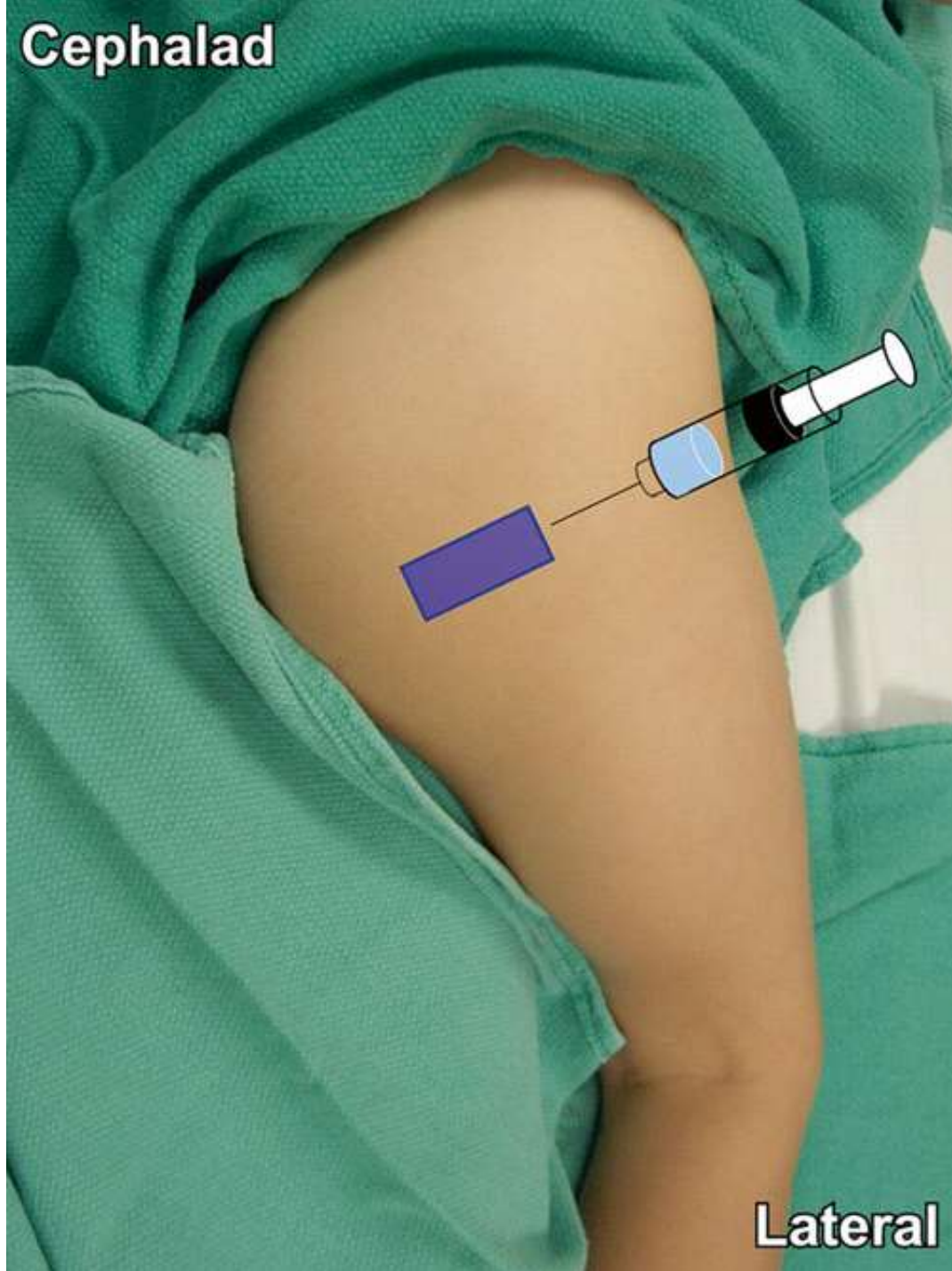




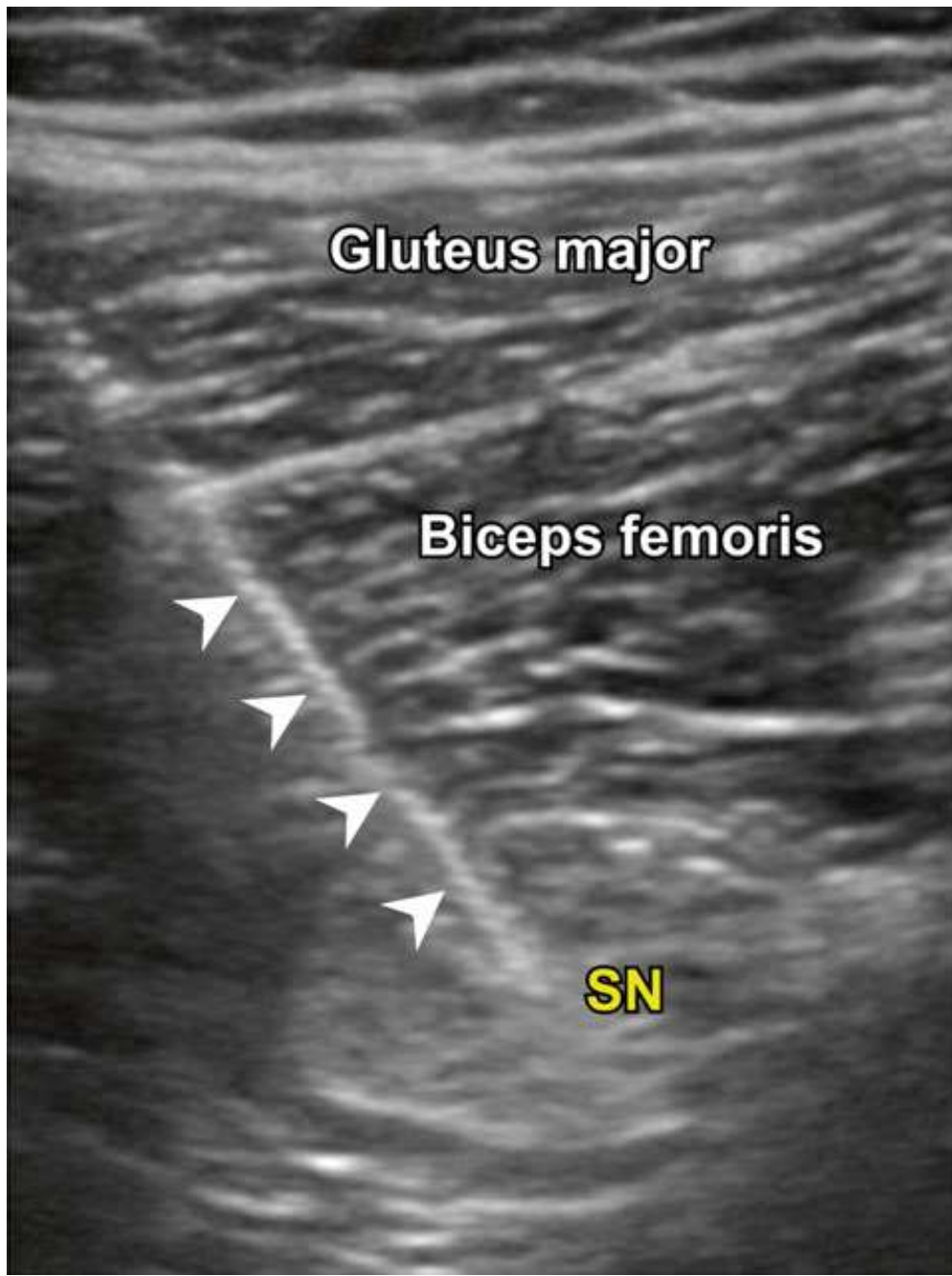Sciatic n.
Inferior subgluteal artery
IT = Ischial tuberosity
QF = Quadratus femoris m.



Cephalad



Lateral



Gluteus major

Biceps femoris

SN

- A 10-year-old girl, 40 kg
- Open reduction and internal fixation of the ankle
- A 22G, 80 mm needle and a 13–6 MHz linear high-frequency probe
- 10 mL 0.25 % bupivacaine
- the block lasted for 8 h

Femoral Nerve Block

- **Indications**
- Femoral nerve block provides surgical anesthesia and, primarily, postoperative analgesia in the anterior thigh and knee. Combined with a sciatic nerve block, complete anesthesia below the mid-thigh can be achieved.

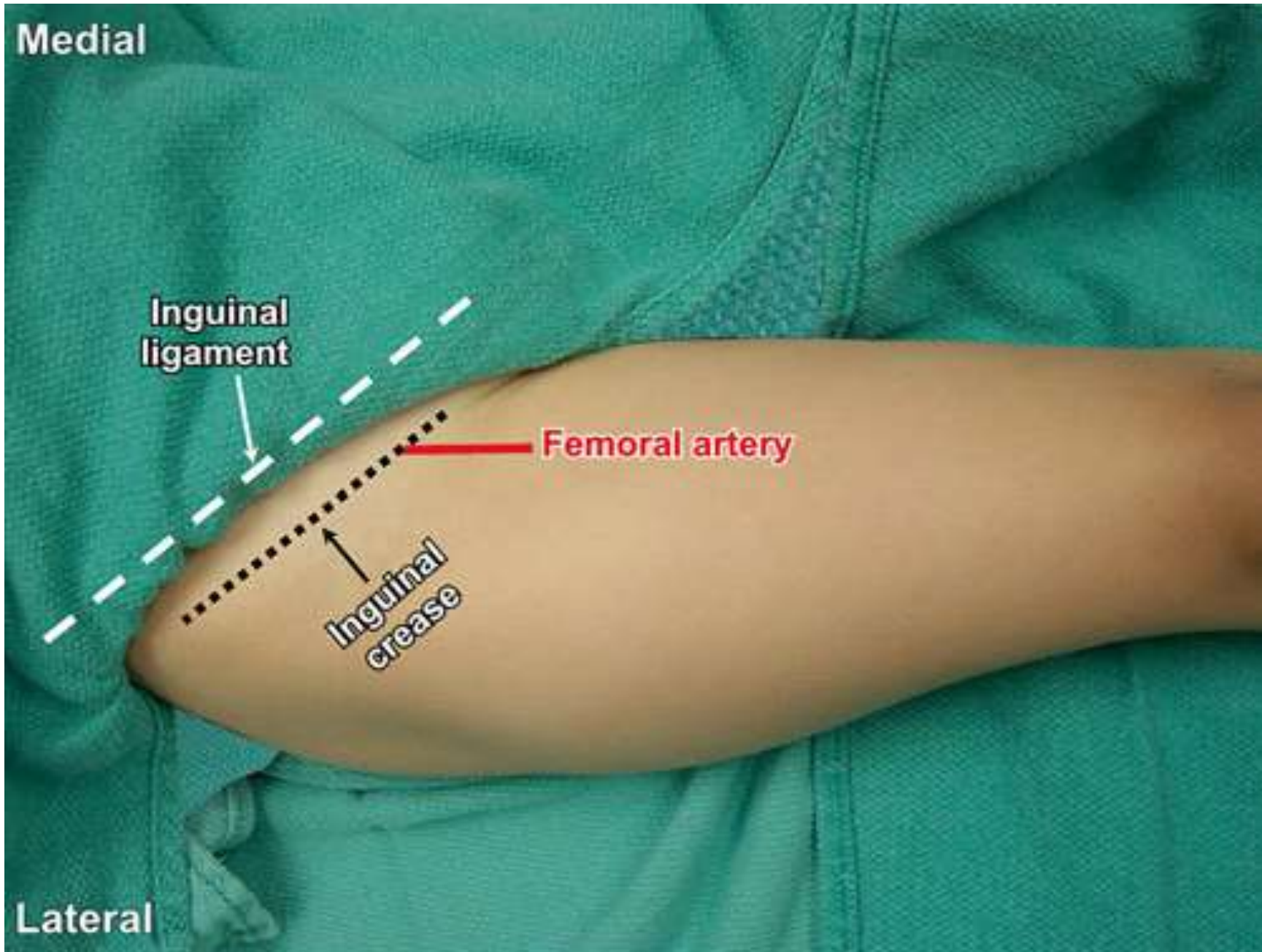
Medial

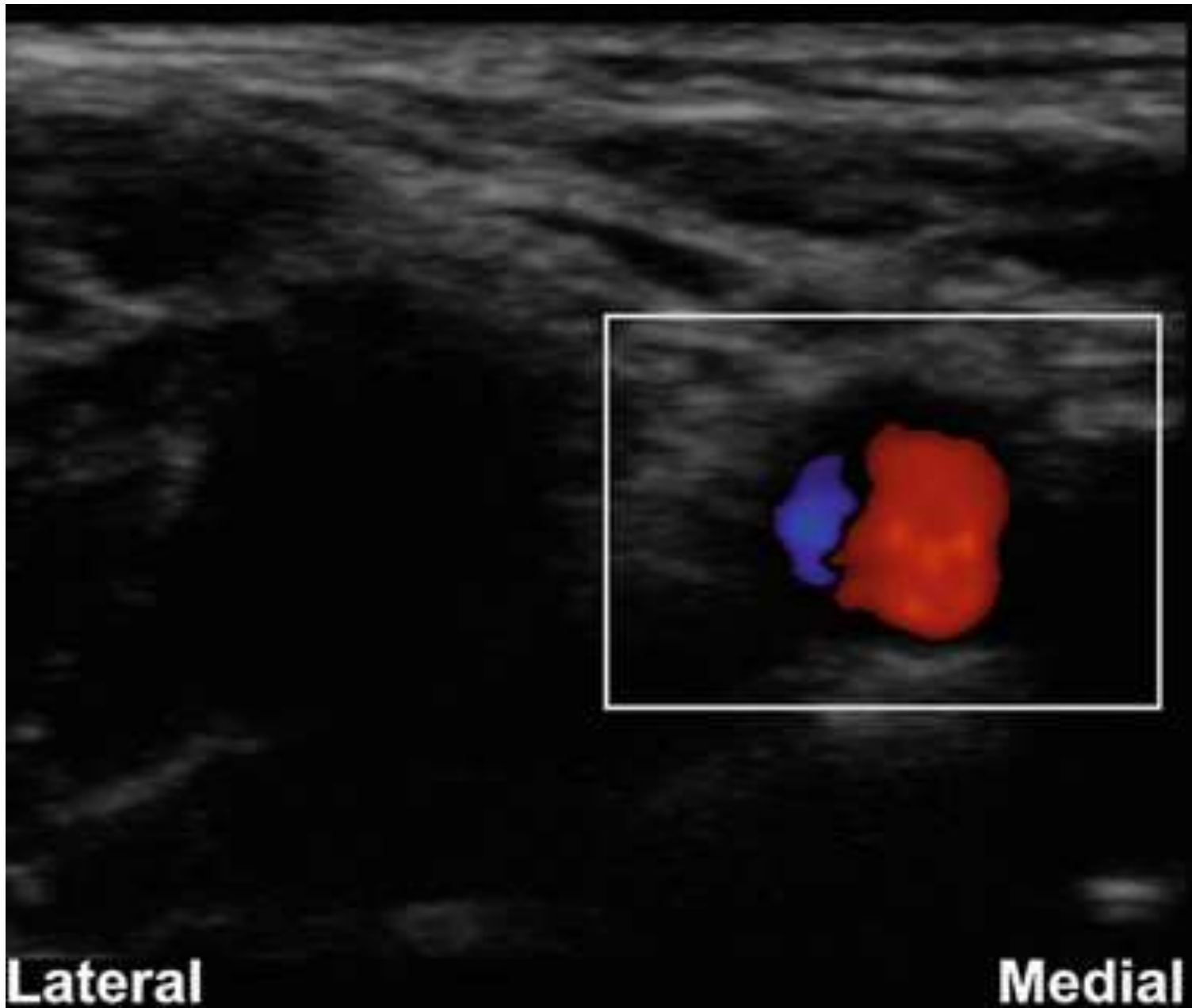
Inguinal
ligament

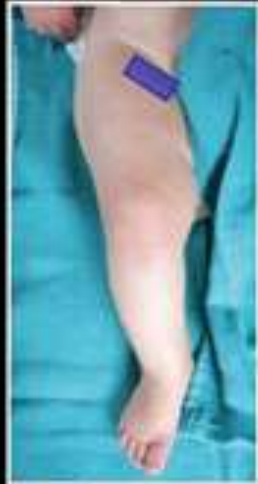Femoral artery

Inguinal
crease

Lateral







Fascia lata
Fascia iliaca

Femoral artery

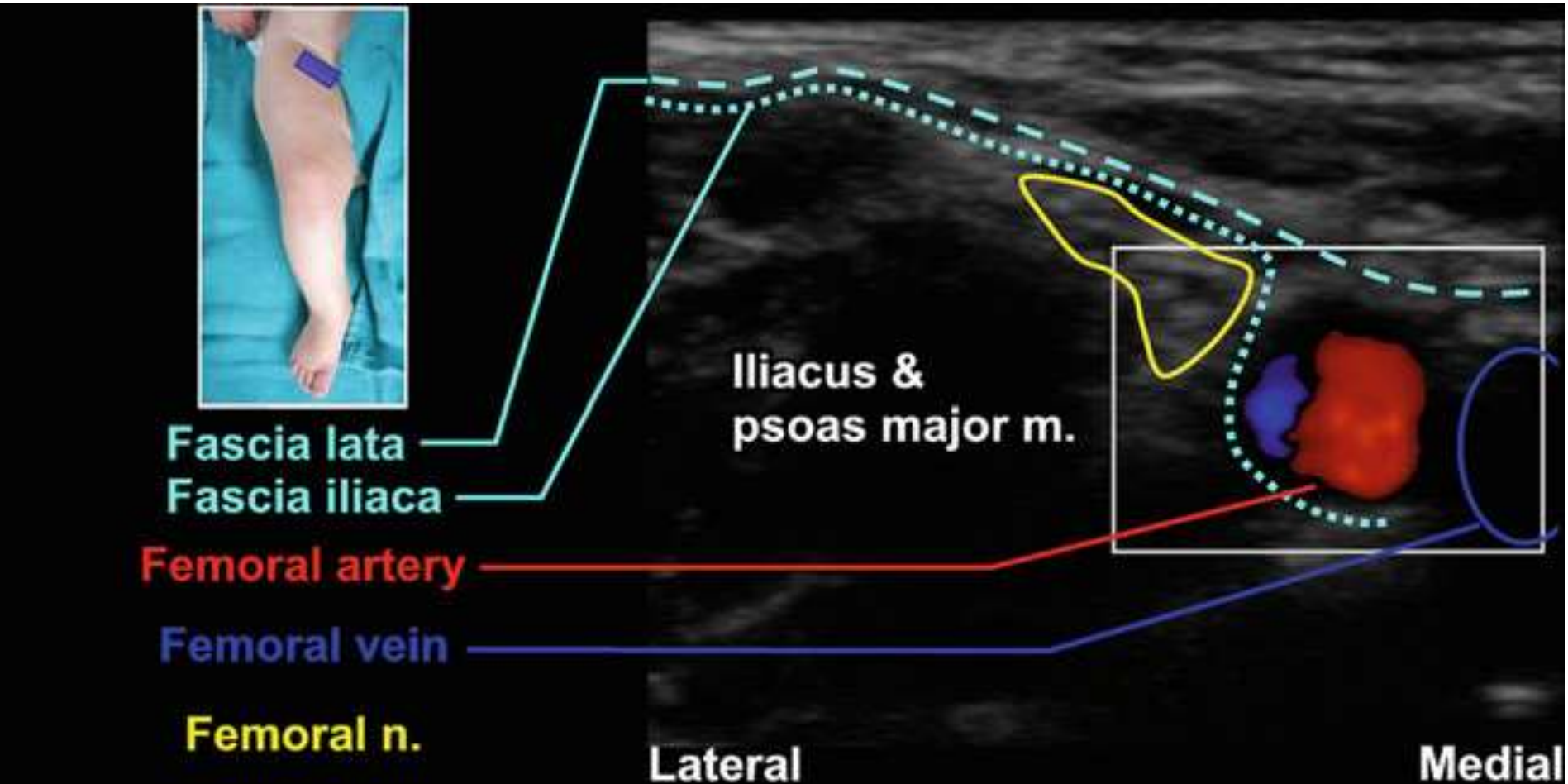
Femoral vein

Femoral n.

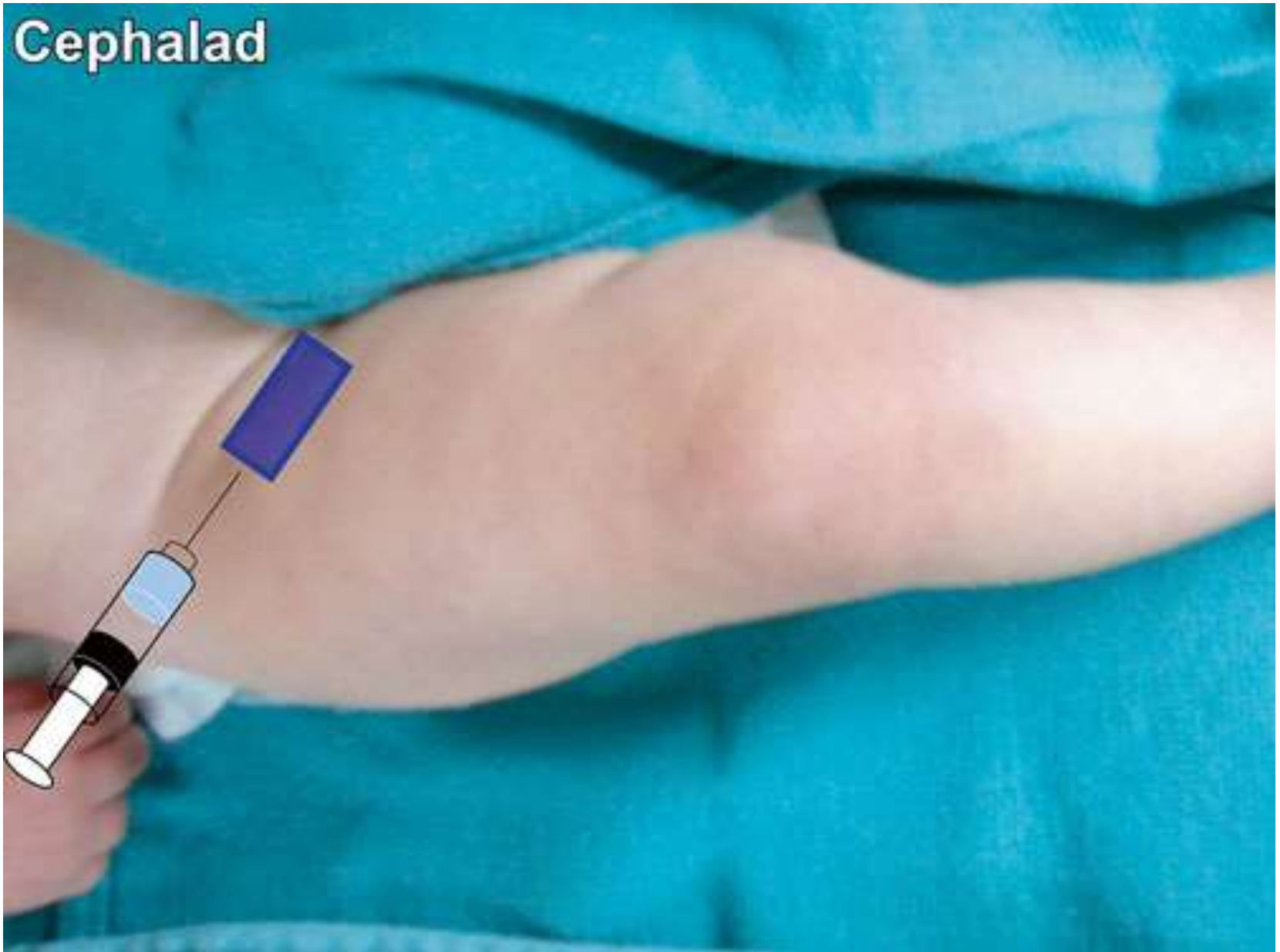
Iliacus &
psoas major m.

Lateral

Medial

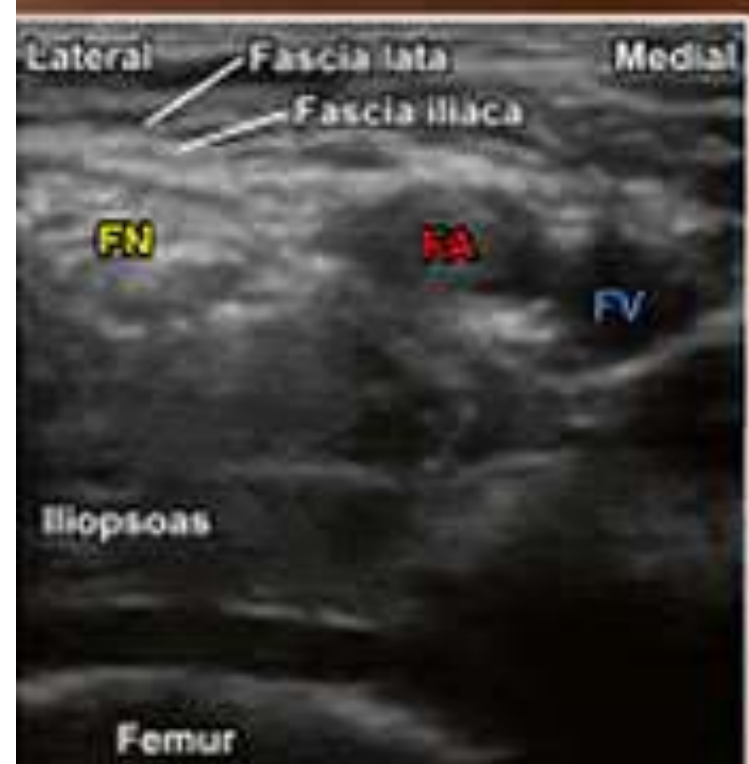
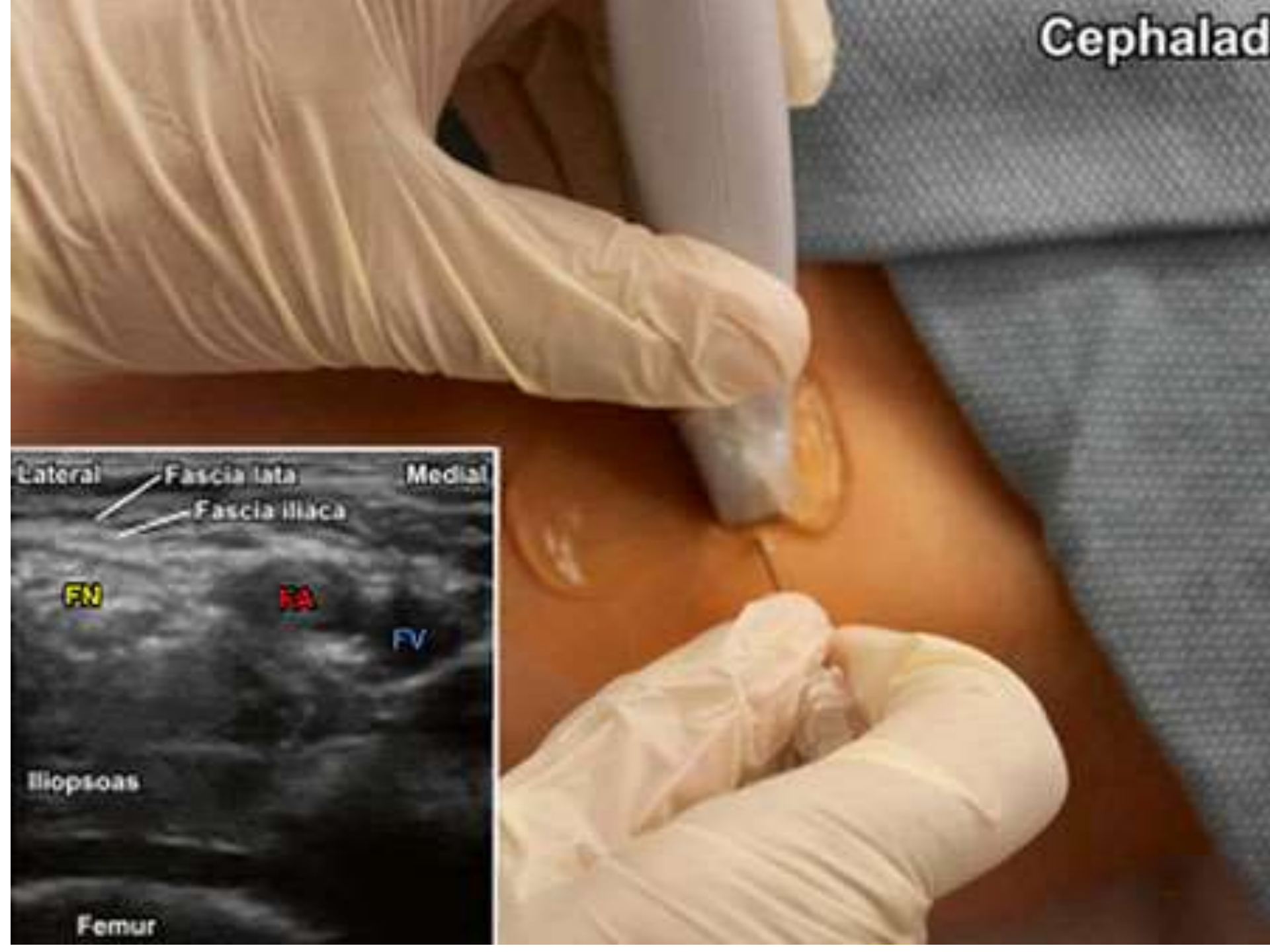
Cephalad



- Inject 0.2–0.5 mL/kg of 0.25 % bupivacaine or 0.2 % ropivacaine without exceeding the recommended toxic dose of local anesthetic (2 mg/kg for bupivacaine and 3–4 mg/kg for ropivacaine without epinephrine).

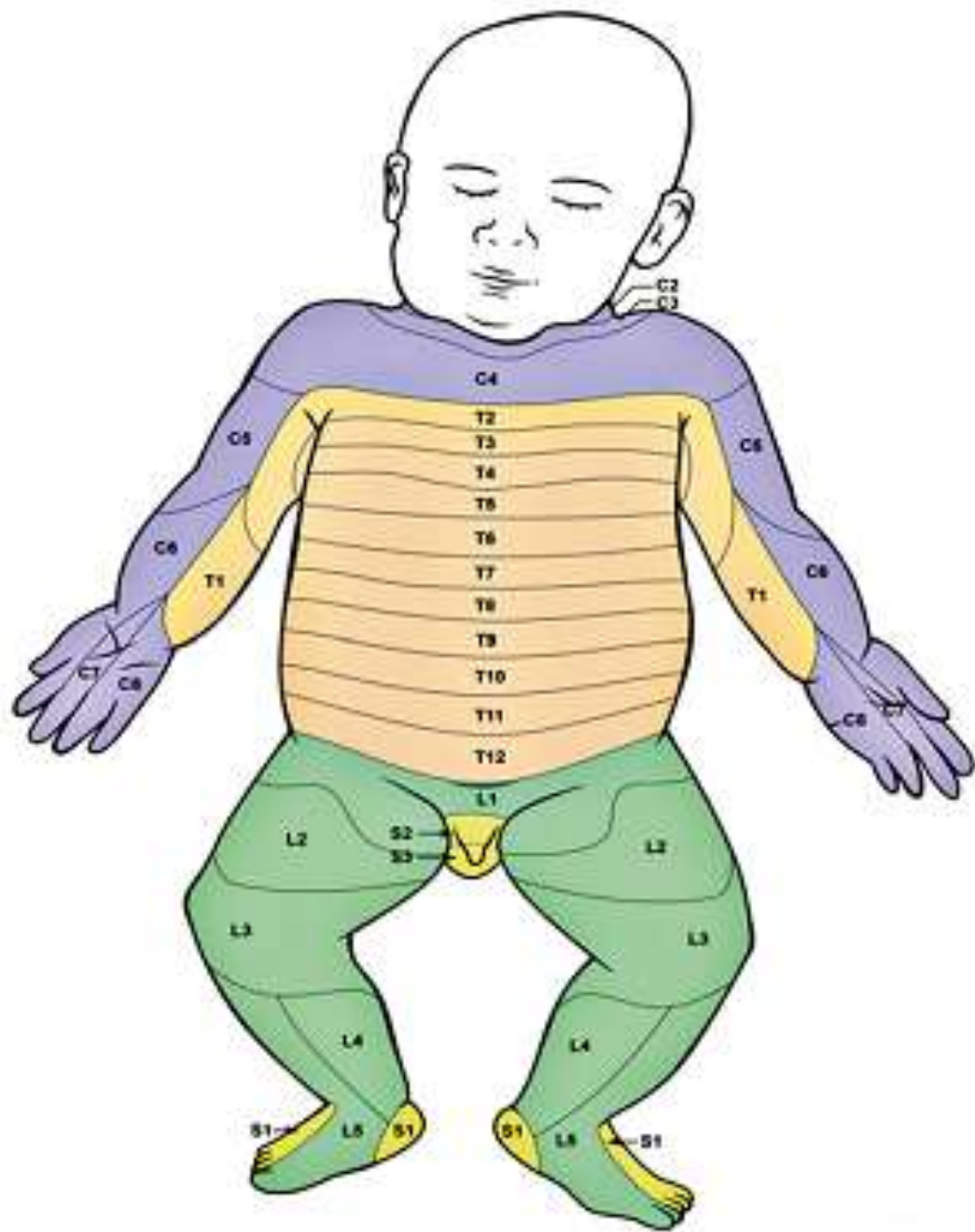
Cephalad

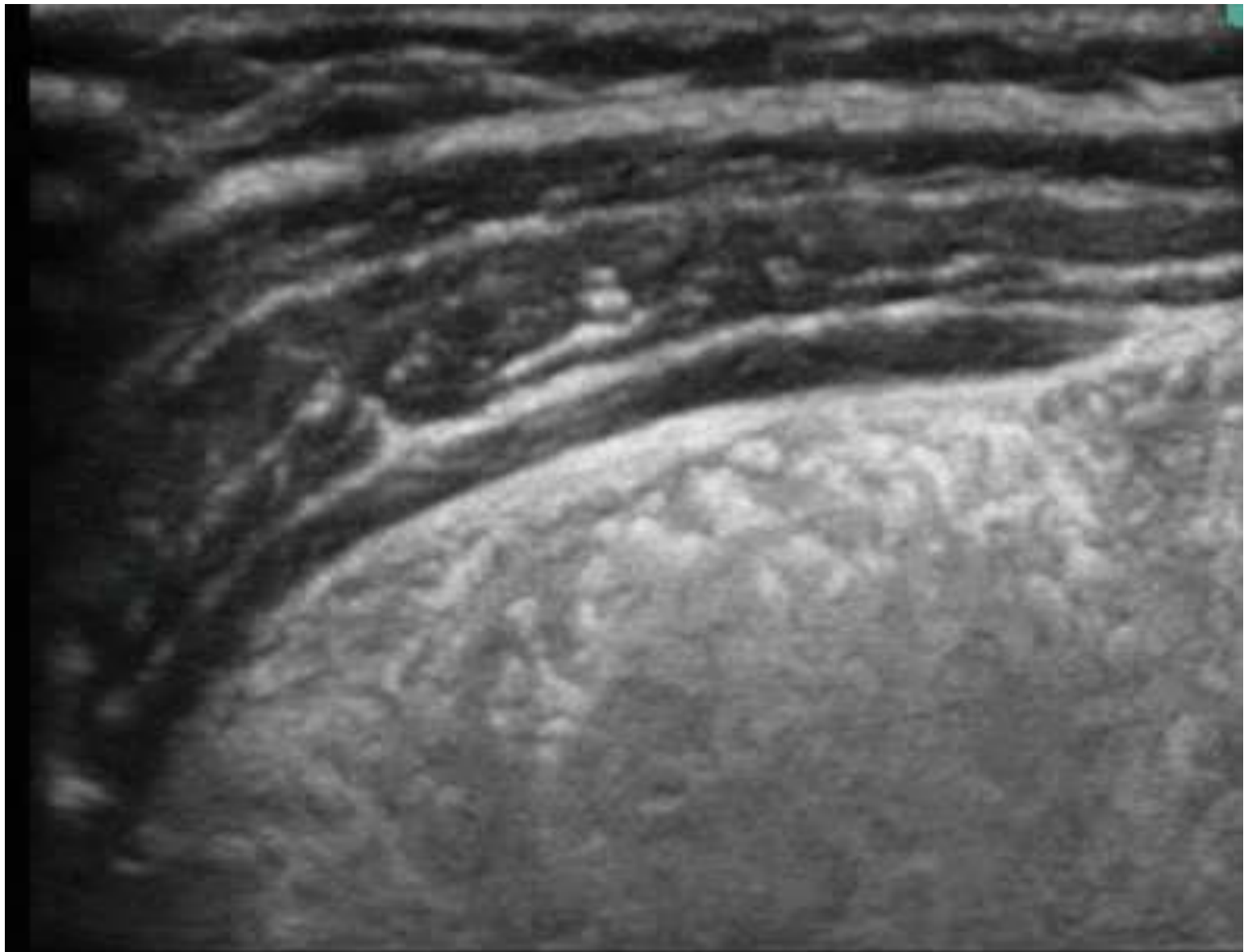


- An 8-year-old male, 34.2 kg,
- left knee anterior cruciate ligament reconstruction
- (10 mL 0.25 % bupivacaine)

TAP block

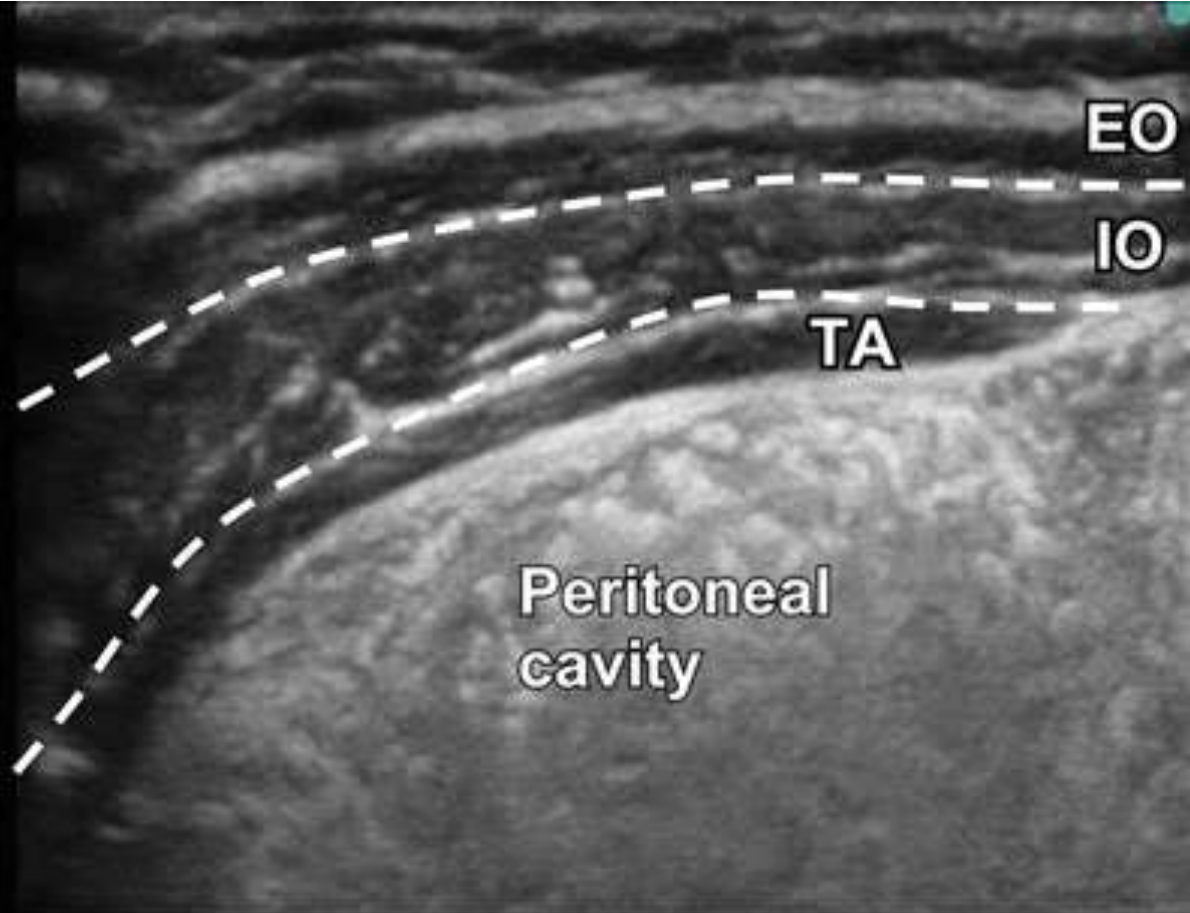
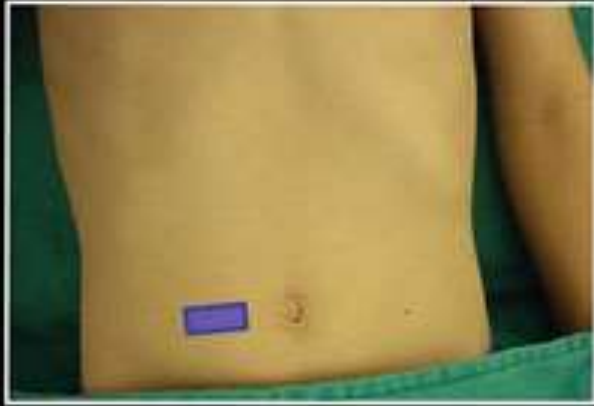- The sensory innervation of the abdominal wall is derived from anterior divisions of the thoracolumbar nerves (T6–L1).





Lateral

Medial



EO = External abdominal oblique m.

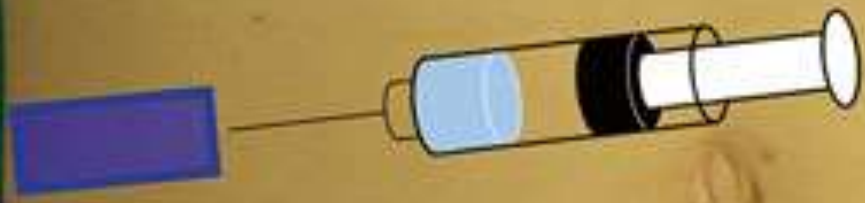IO = Internal abdominal oblique m.

TA = Transversus abdominis m.

Lateral

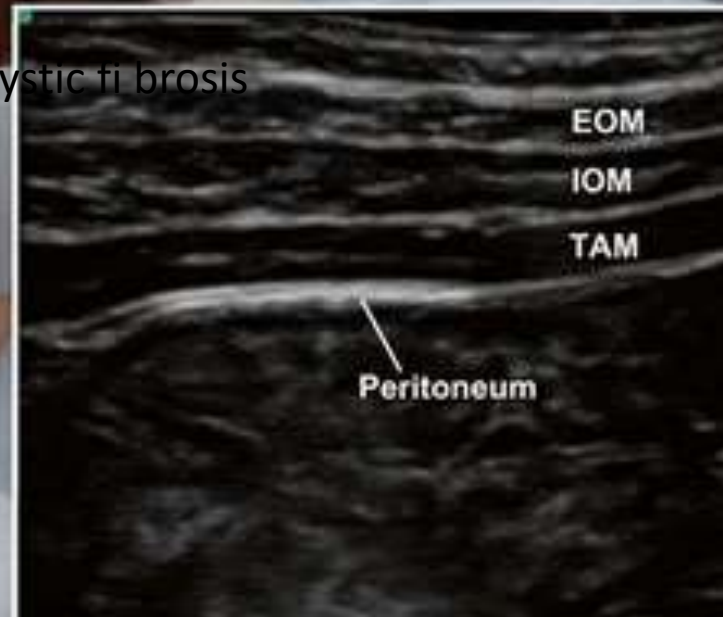
Medial

Cephalad



Cephalad

A male toddler, 35 months old and weighing 13.5 kg, presented for laparoscopic gastrostomy tube insertion. The patient had a history of cystic fibrosis



- A male toddler, 35 months 13.5 kg, for laparoscopic gastrostomy tube
- a history of cystic fibrosis
- a 27G needle with an in-plane approach
- 8 ml 0.25 % bupivacaine
- with 1:200,000 epinephrine.
- Duration of surgery was 1 h, and block duration was 6 h.