The Shoulder Block: Combined Suprascapular And Axillary Nerve Block

Hamid Reza Faiz, MD
Professor of Anesthesiology
IUMS

Shoulder

- The shoulder is the body's *most flexible* joint.
- While this flexibility allows you to move your arm in all different directions, it also makes the shoulder particularly *vulnerable to injury*.
- In 2010, nearly *11.5 million people* visited their doctor for shoulder problems.
- In many cases, nonsurgical treatment options, such as physical therapy, are enough to relieve symptoms, but sometimes surgery is needed.

Interscalene technique

The ***interscalene nerve block*** is the ***most common type*** of nerve block used in shoulder surgeries.

- Pain following shoulder surgery can be severe and has traditionally been controlled using an interscalene nerve block.
- This technique is associated with well-documented adverse effects.

Shoulder Anatomy

- In order to understand your options for pain relief following shoulder surgery, it's important to first understand the anatomy of the shoulder.

- The shoulder contains a number of bones, joints, muscles, and ligaments, which all work together to make the many shoulder movements possible.

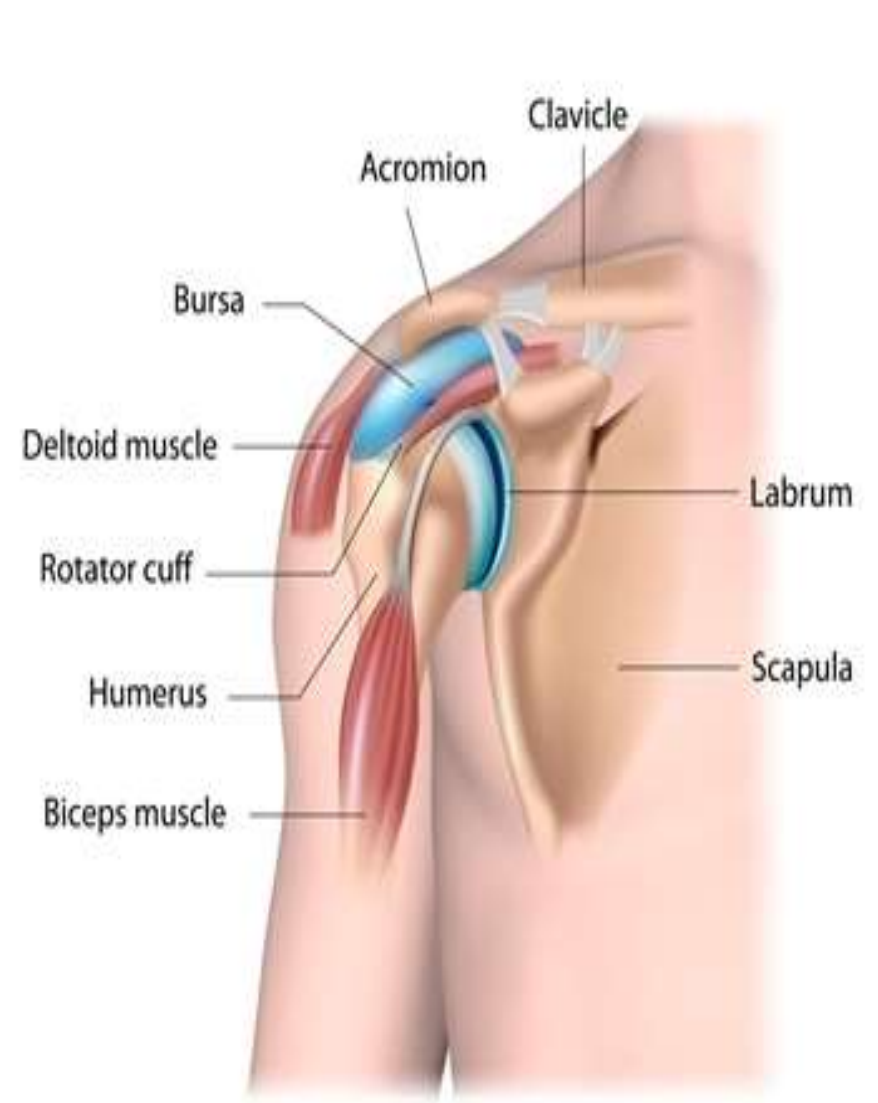

How does shoulder pain occur?

- Shoulder pain is primarily sent to the brain through a group of nerves known as the brachial plexus.

- These nerves start in the spinal cord and travel through the neck and down the arm.

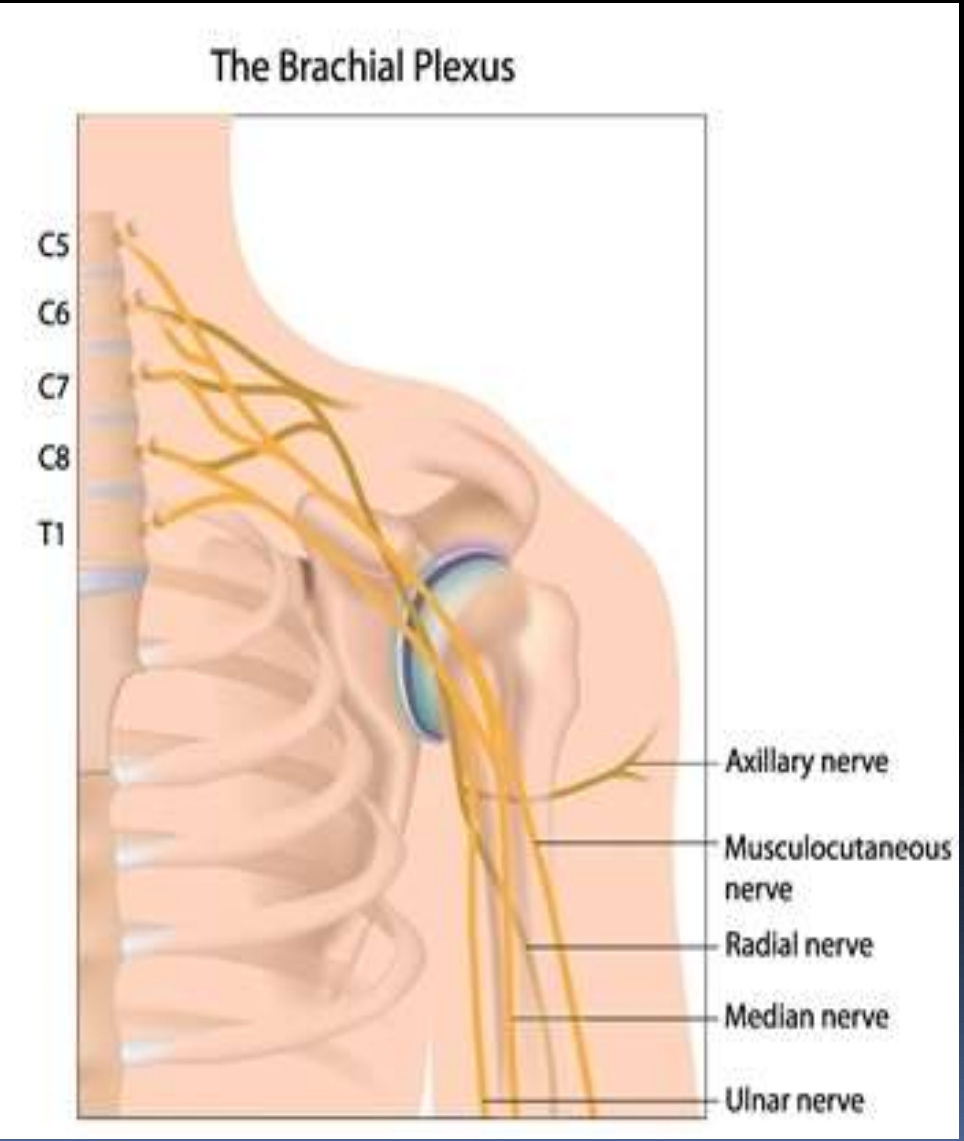

Anatomy Of Bracial Plexus

- The brachial plexus consists of anterior rami of the spinal nerves from **C5 to T1**.

- **C5 and C6** → **superior trunk**
- **C7** → **Middle trunk**
- **C8 and T1** → **Inferior trunk**

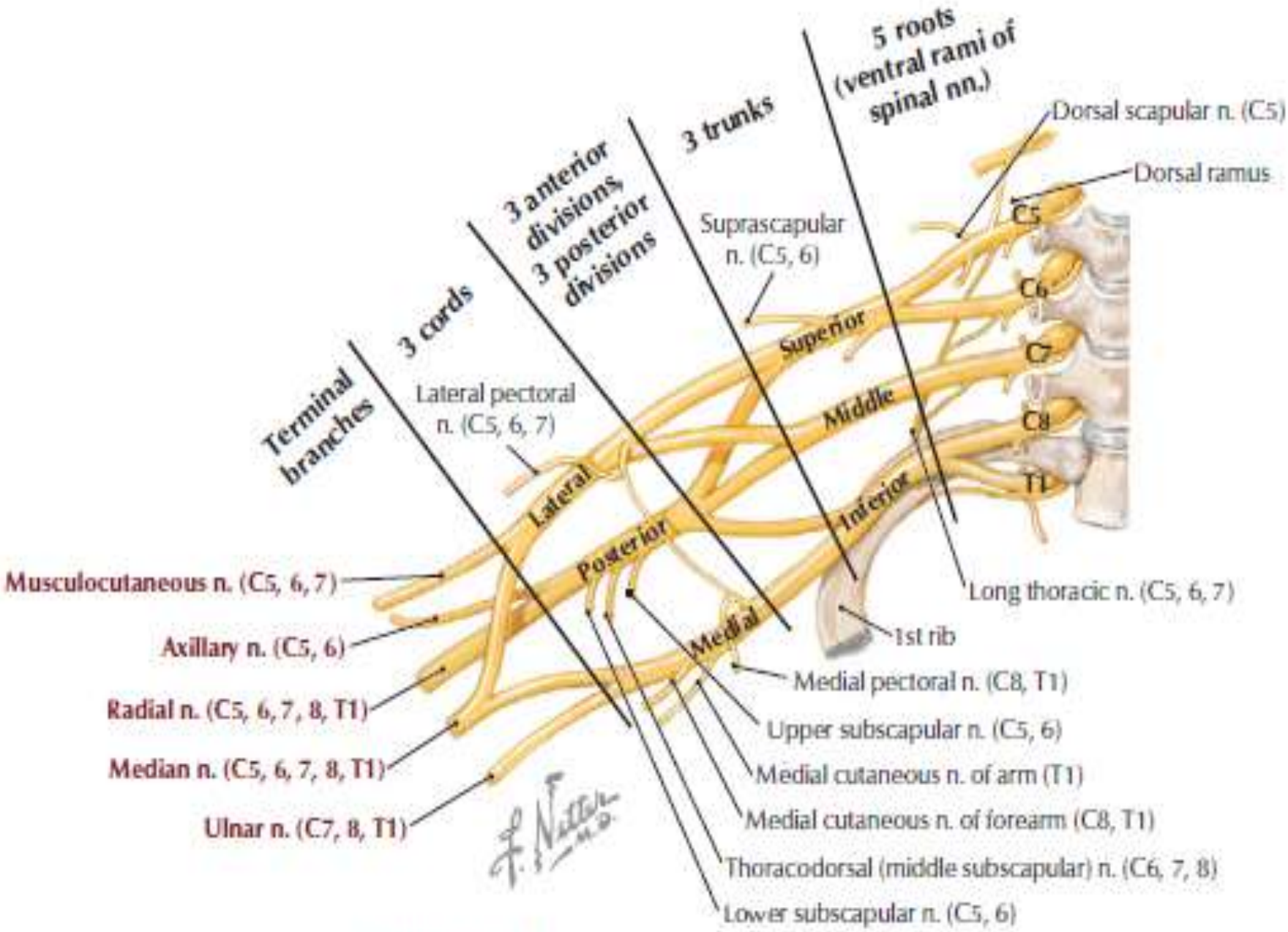

FIGURE 7-10 Schematic of the Brachial Plexus

Interscalene technique

Temporary side effects

Phrenic nerve paralysis
Horner's syndrome
Hoarseness

- *Motor block can be quite extensive.*

Rare but severe complications

injection of LA into the adjacent CSF, epidural space or vertebral artery

Interscalene technique

- **Transient neurological complications**

  14% at 10 days

- **Permanent damage**

  1 in 500 cases

Interscalene Block

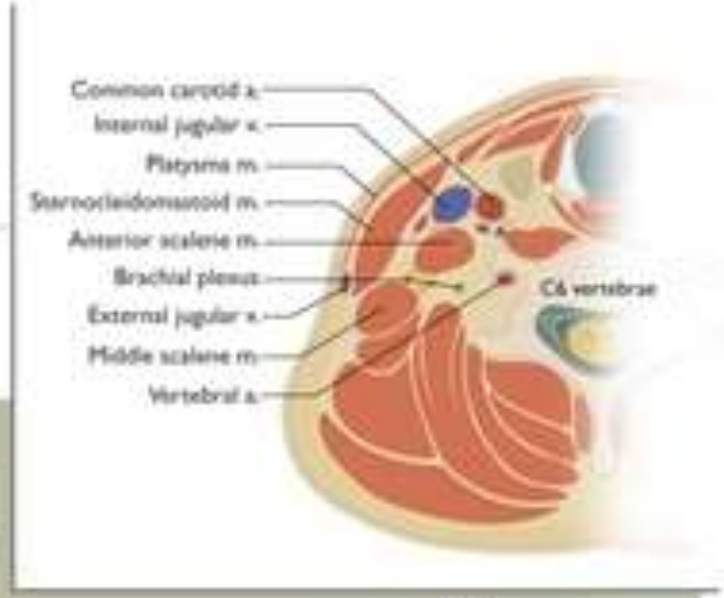

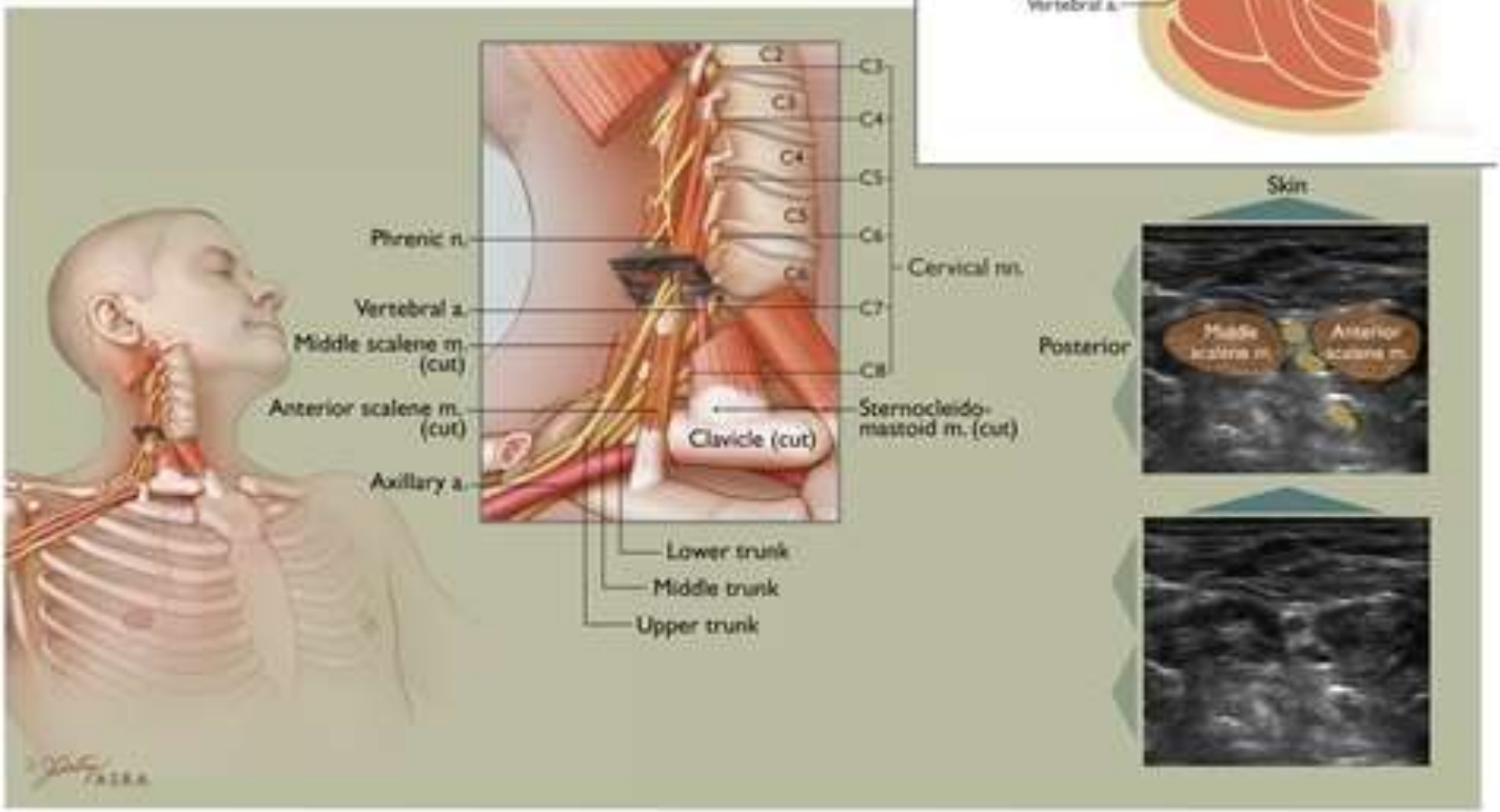

- *In this particular image, the vertebral artery and carotid artery seen.*

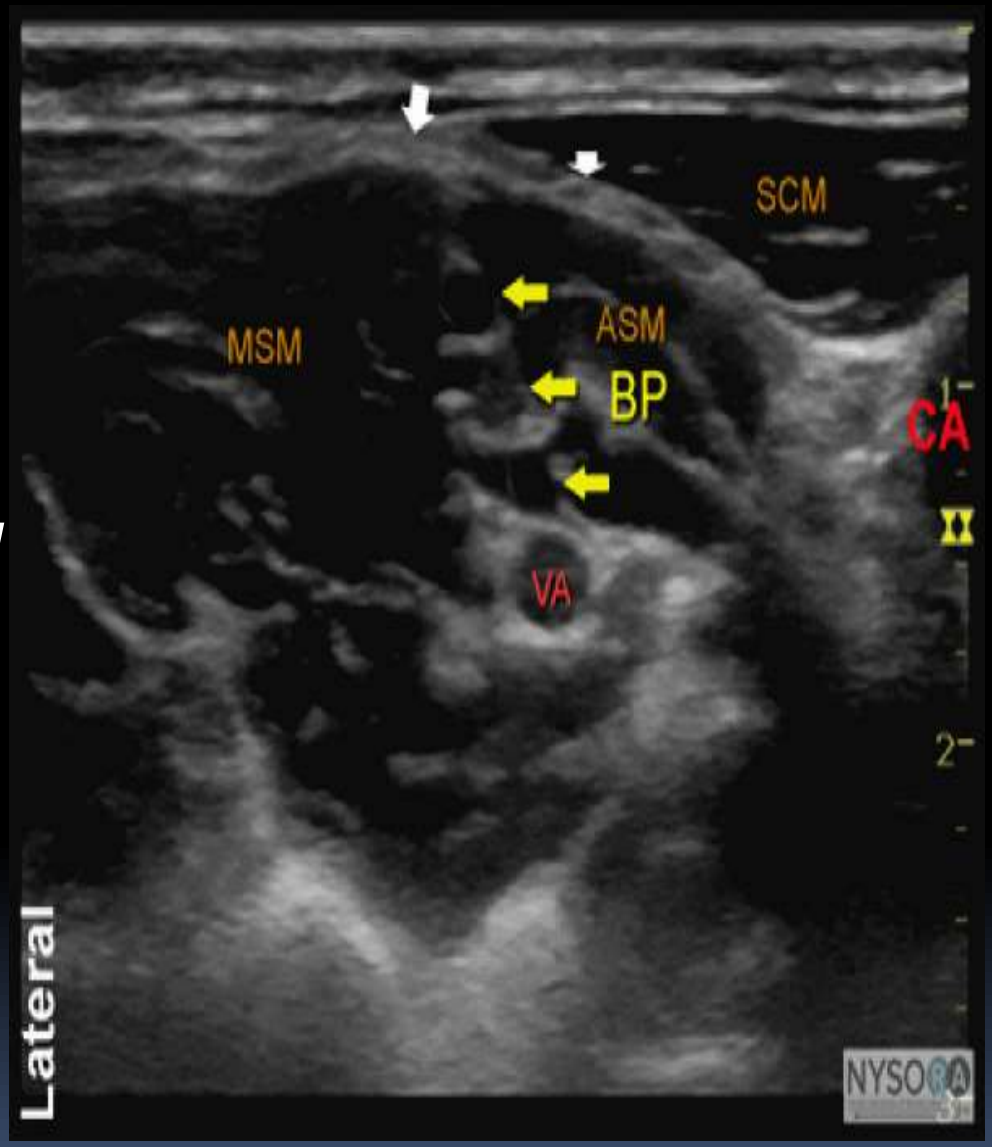

Phrenic Nerve Anatomy

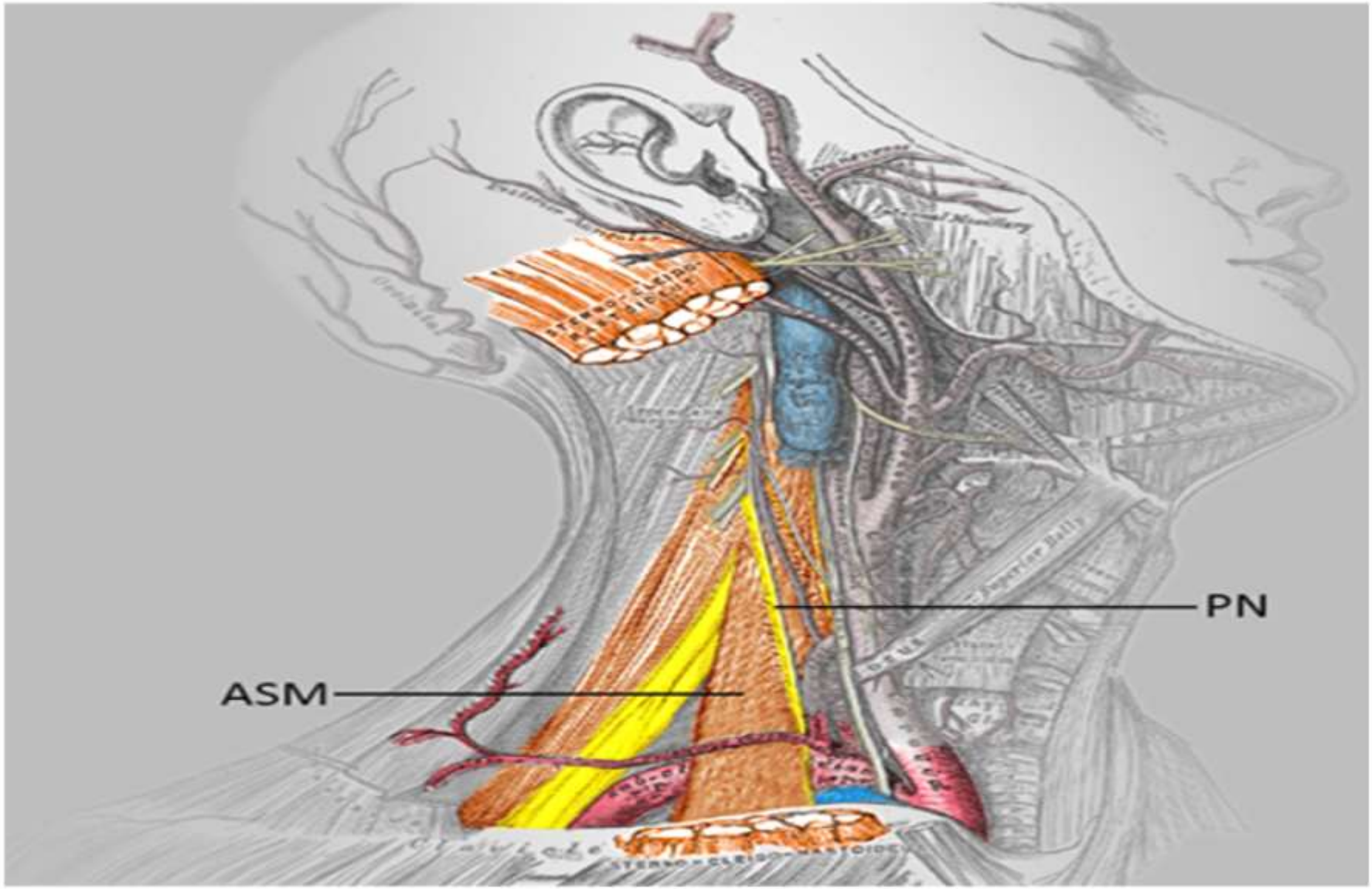

Phrenic Nerve Image

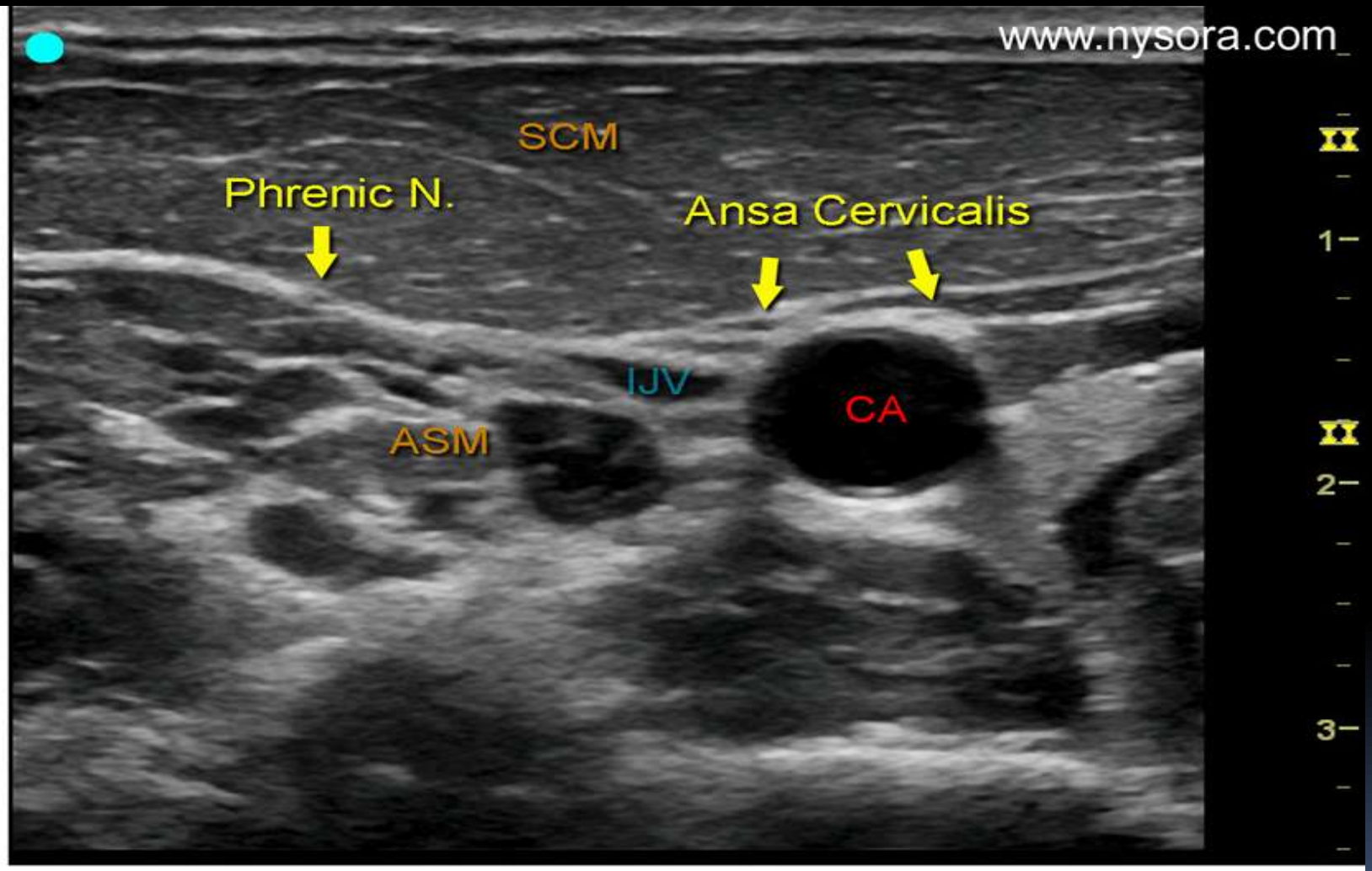

Lateral

Transverse View - Neck C6 Level

Combined suprascapular and axillary nerve block

- It appears to be an effective alternative to ISB for pain relief following shoulder surgery.

- Minimal side effects
- Reduced potential for serious complications
- Less reported pain during block resolution

- **Five nerves innervate the shoulder joint and associated structures.**
- Suprascapular
- Axillary
- Lateral pectoral
- Musculocutaneous
- Subscapular

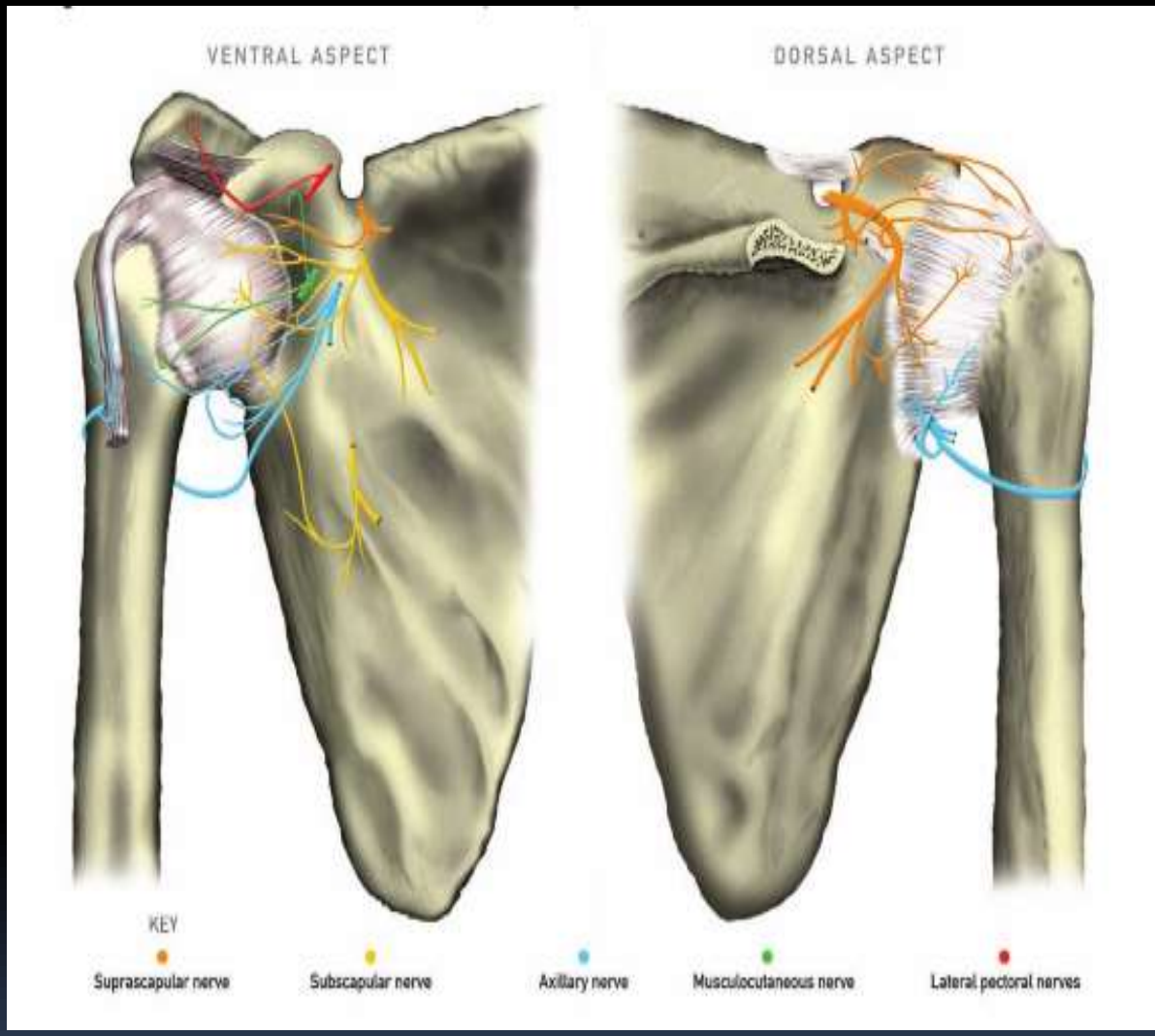

- **The suprascapular nerve carries the most extensive supply.**

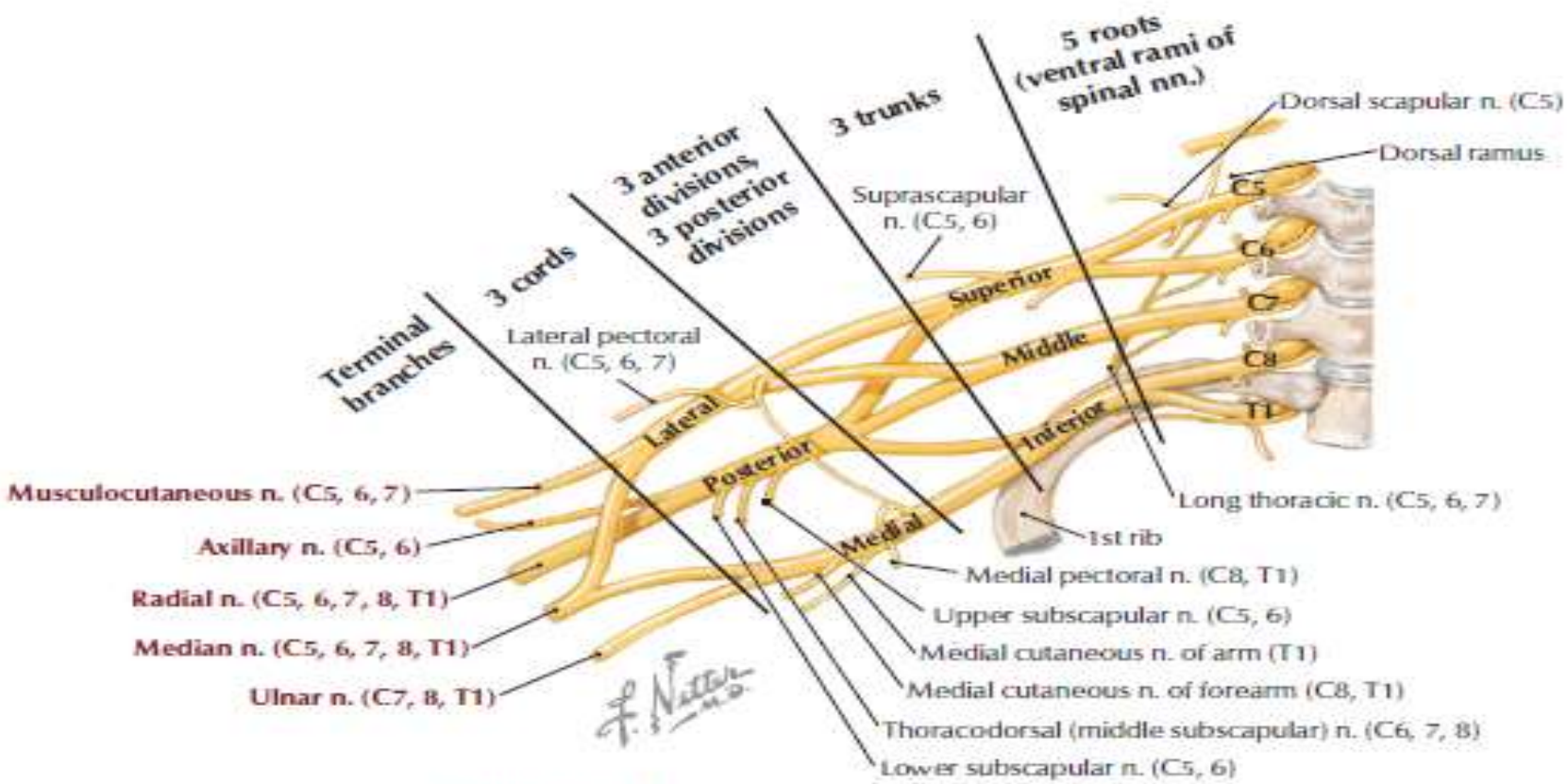

FIGURE 7-10 Schematic of the Brachial Plexus

- The suprascapular nerve is a branch of the **superior trunk**.
- The axillary nerve is formed as a terminal branch of the **posterior cord** .

US Guided Axillary nerve block

- The most reliable approach is to image the posterior surface of the humerus in its long axis.
- This will allow a short axis view of the circumflex artery and the axillary nerve.
- The artery is the most reliable landmark, and LA injected adjacent to this on the posterior surface of the humerus.
- If the artery is not visible, follow the periosteum cephalad until it merges with joint capsule. Injection of LA 1 cm caudal to this should be in the vicinity of the axillary nerve.

US Guided Axillary Nerve Block

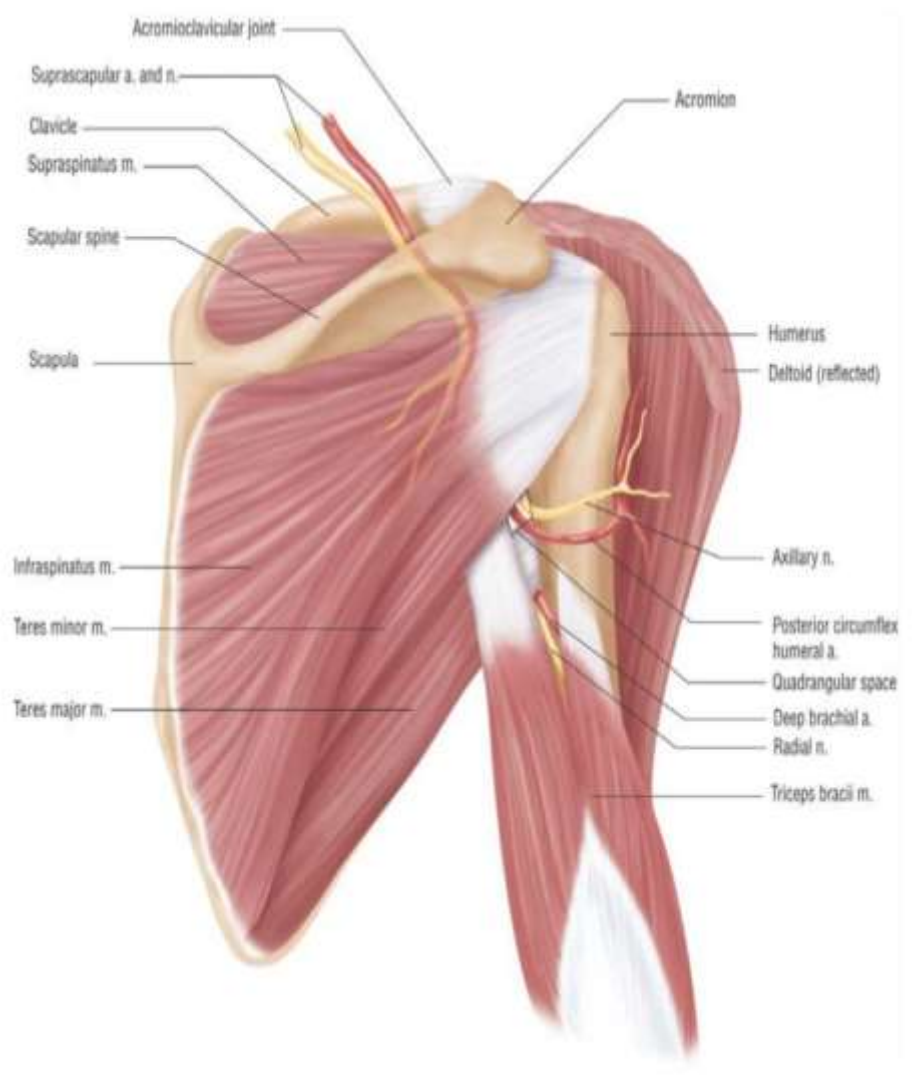

US Guided Axillary nerve block

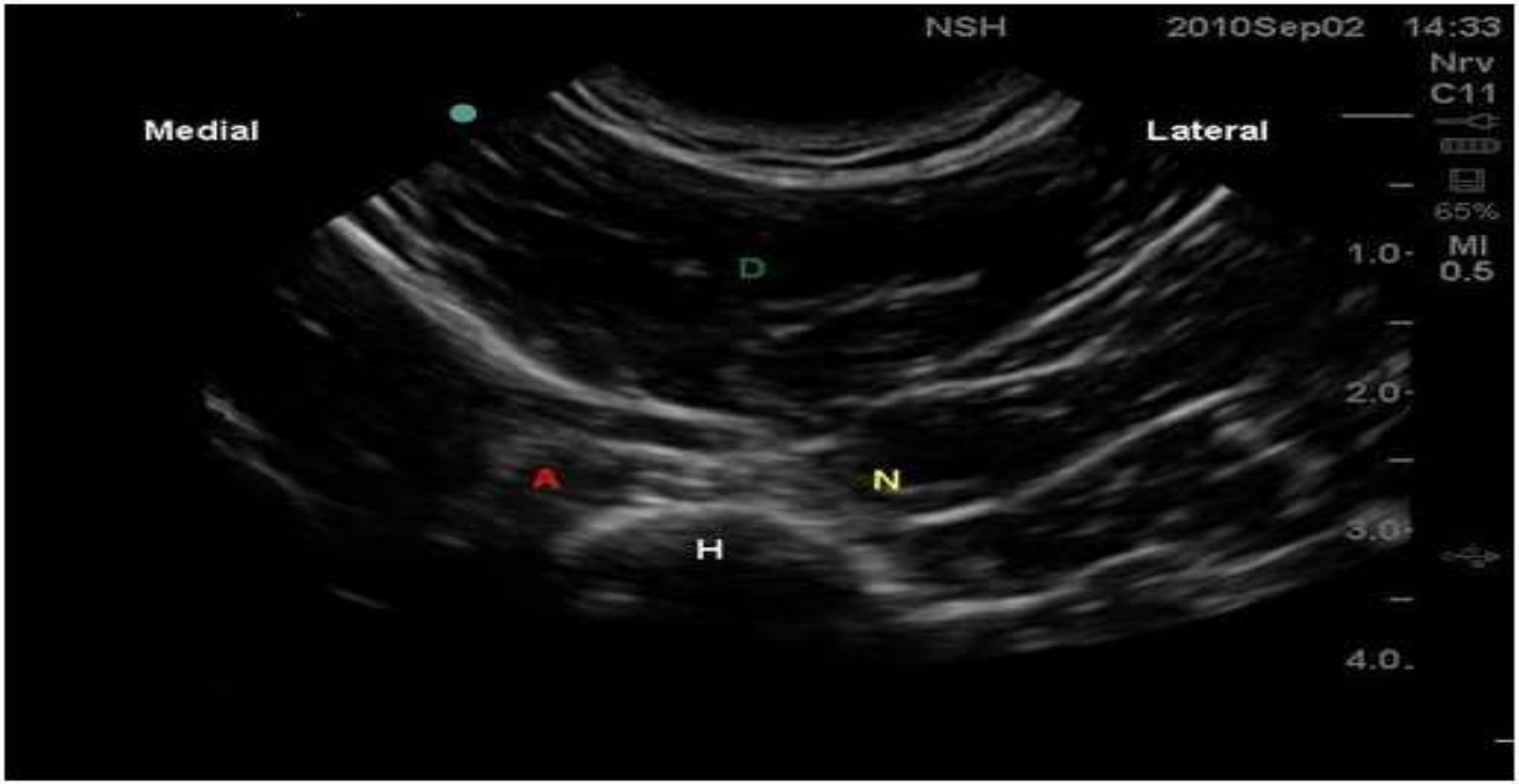

Axillary nerve

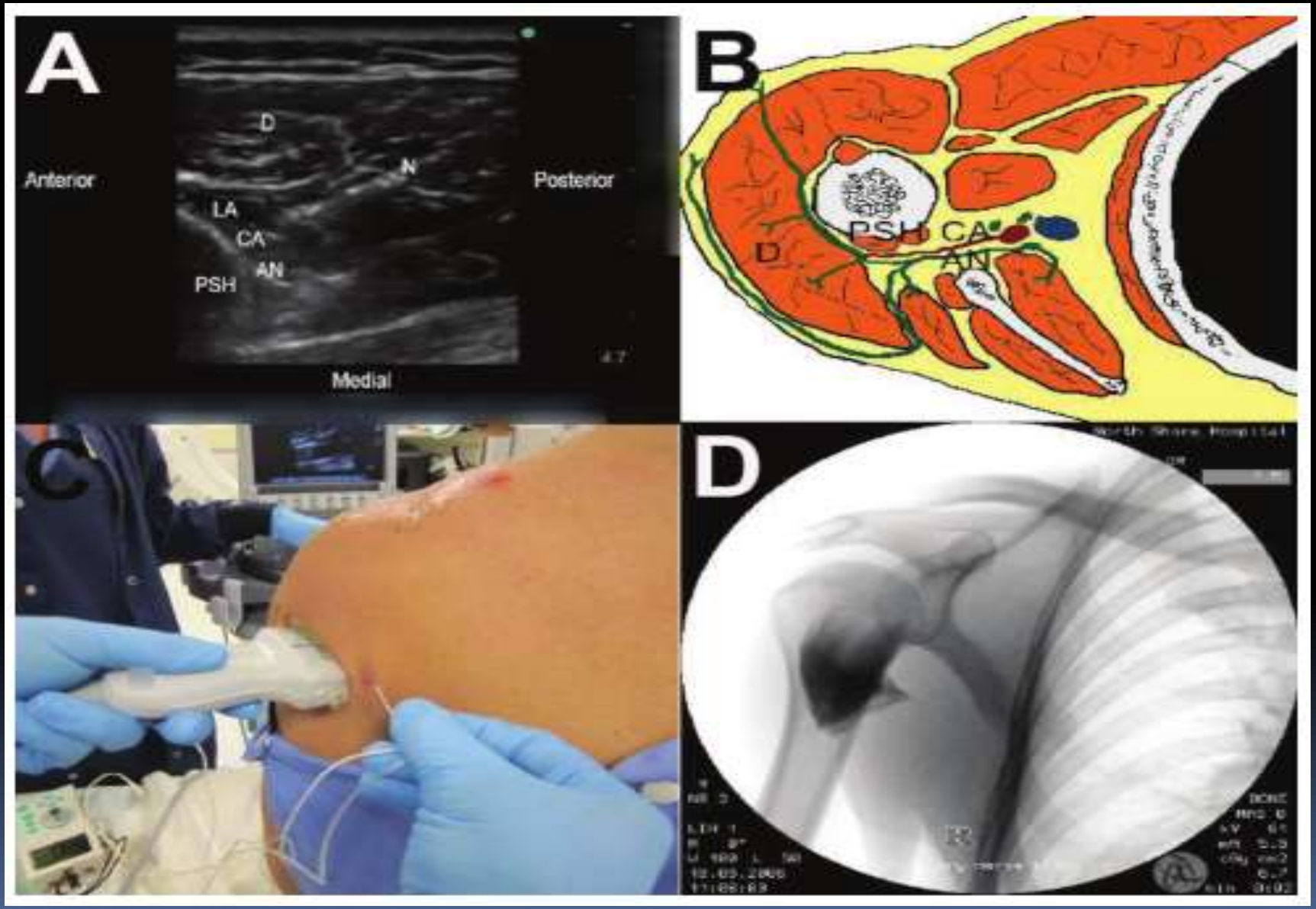
A
D
N
Anterior
Posterior
LA
CA
AN
PSH
Medial
B
PSH
CA
D
AN
C
D

Suprascapular Nerve Anatomy

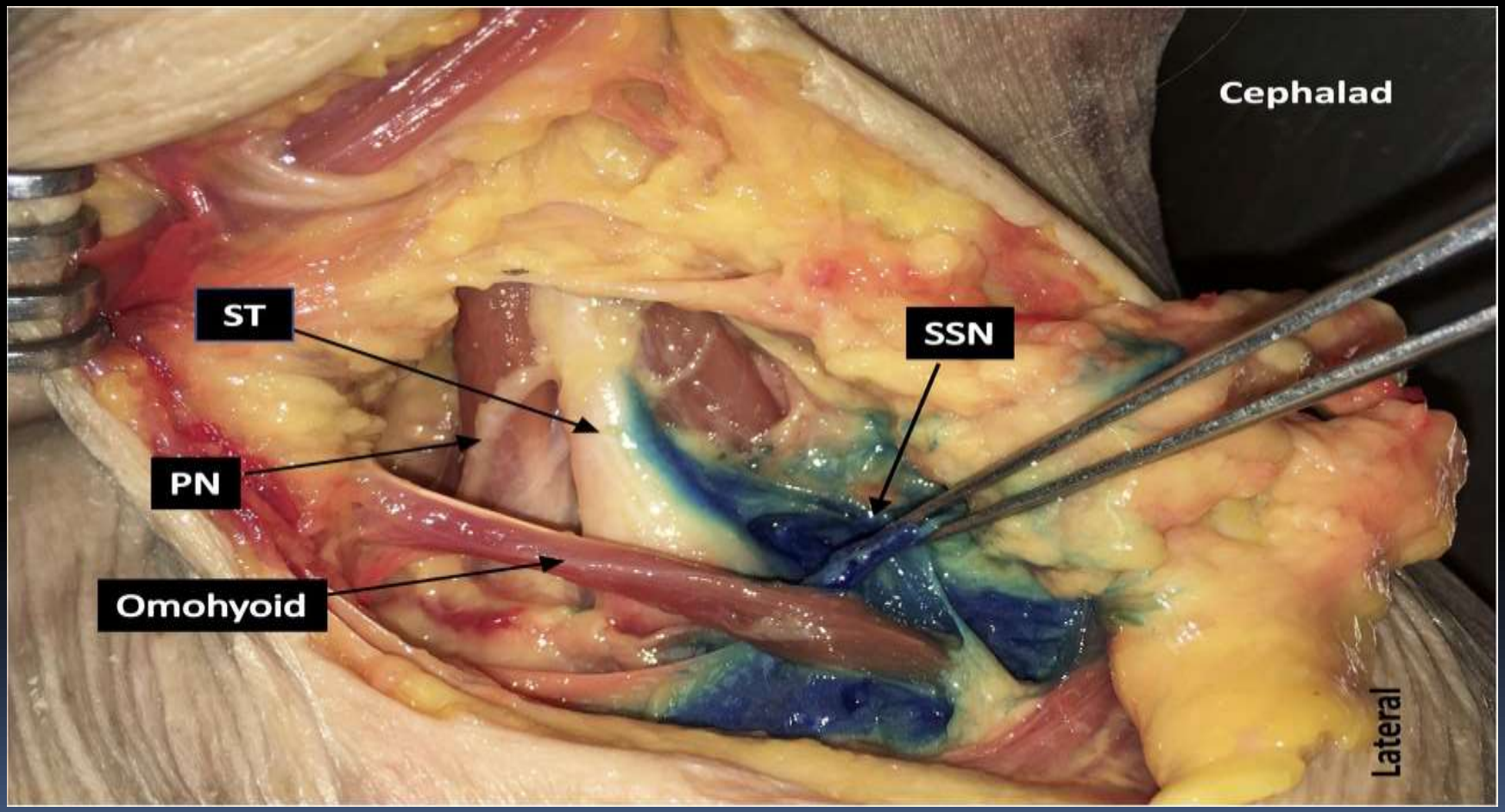

Suprascapular Nerve Sonoanatomy

Suprascapular Nerve Sonoanatomy

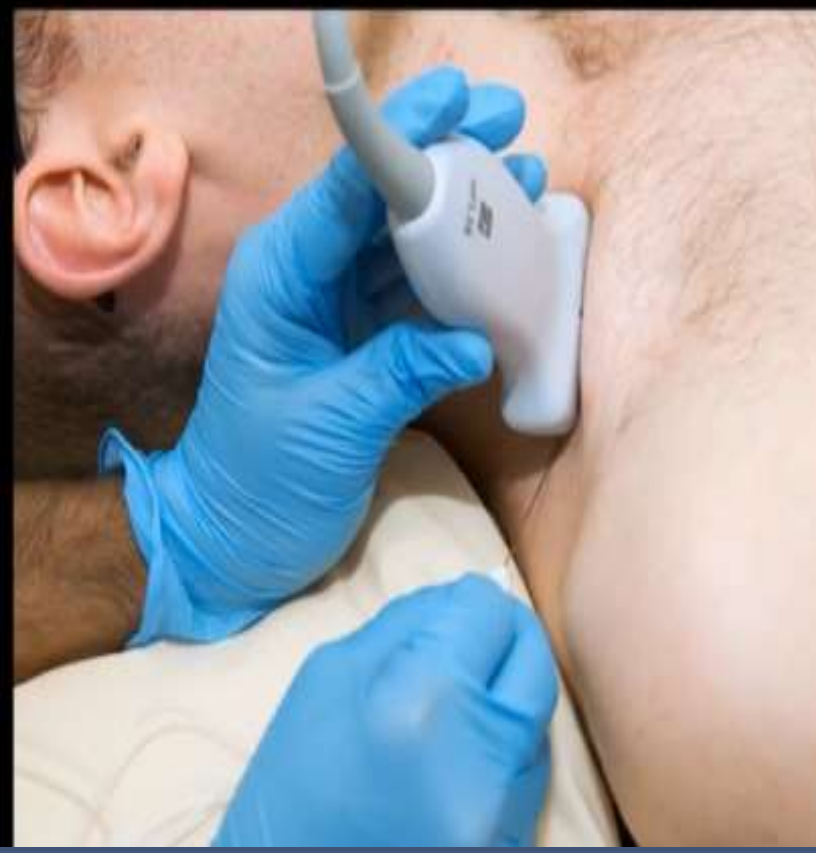

Supplemental analgesia requirement

- Some patients (50%) will have minimal if any pain, while others will need between 5 - 10mg of morphine between theatre and recovery.
- Much of the residual pain is due to the stretching of the shoulder capsule with arthroscopic fluid, which must recede over the initial postoperative period.
- The pain arising from surgery to the shoulder joint structures is well covered by combined suprascapular and axillary nerve blockade.

Practical Tips

- **Indications**: it is limited to providing analgesia, rather than full surgical anesthesia.
- It can be effective for arthroscopic or open shoulder surgery.
- Rotator cuff surgery involving the subscapularis muscle will not be covered by this technique.

Knee Surgery, Sports Traumatology, Arthroscopy
December 2012, Volume 20, Issue 12, pp 2573–2578 | Cite as

Analgesic effectiveness of nerve block in shoulder arthroscopy: comparison between interscalene, suprascapular and axillary nerve blocks

Results

The VAS score of the PCA only-group was highest at the recovery room. The VAS score of the PCA with ISB-group was the lowest, however, with large fluctuations over time. Although the VAS score of the PCA with SSNB + ANB-group was higher than that of the PCA with ISB-group, it was steadily lower than the PCA-only group, without any fluctuations. The degree of satisfaction of the PCA with ISB-group was highest at the recovery room. The number of times the PCA was used at the 8-h postoperative evaluation was largest in the PCA only-group.

Conclusions

The initial 24 h after surgery plays a key role in controlling pain after arthroscopic shoulder surgery. PCA with SSNB + ANB is a better anaesthetic choice than PCA with ISB or PCA only during the initial 24 h of the postoperative period.

Regional Anesthesia and Acute Pain: Original Articles

A Comparison of Combined Suprascapular and Axillary Nerve Blocks to Interscalene Nerve Block for Analgesia in Arthroscopic Shoulder Surgery: *An Equivalence Study*

RESULTS: Combined suprascapular and axillary nerve block provided nonequivalent analgesia when compared with ISB at different time points postoperatively, except on postoperative day 7. Interscalene block had better mean static pain score in the recovery room (ISB 1.80 [95% confidence interval [CI], 1.10-2.50] vs SSAX 5.45 [95% CI, 4.40-6.49; $P < 0.001$]). At 24 hours, SSAX had better mean static pain score (ISB 6.35 [95% CI, 5.16-7.54] vs SSAX 3.92 [95% CI, 2.52-5.31]; $P = 0.01$) with similar satisfaction between the groups.

CONCLUSIONS: Combined suprascapular and axillary nerve block provides nonequivalent analgesia compared with ISB after arthroscopic shoulder surgery. While SSAX provides better quality pain relief at rest and fewer adverse effects at 24 hours, ISB provides better analgesia in the immediate postoperative period. For arthroscopic shoulder surgery, SSAX can be a clinically acceptable analgesic option with different analgesic profile compared with ISB.

Original Article With Video Illustration

Suprascapular Nerve Block Versus Interscalene Block as Analgesia After Arthroscopic Rotator Cuff Repair: A Randomized Controlled Noninferiority Trial

Results

Seventy-four patients were randomized, and 59 met the intraoperative inclusion criteria. Six patients were excluded (1 for pneumothorax after ISB, 1 for unsuccessful SSB, and 4 for incomplete questionnaires). None of the patients were lost to follow-up. There was no significant difference between the SSB and ISB groups in mean pain score for the first 24 hours ($P = .92$) or the first 7 days ($P = .05$). However, there was significantly less pain in the ISB group in the recovery room ($P = .01$). Consumption of analgesics was comparable between the groups, but the SSB group took significantly more morphine in the recovery room.

Conclusions

In this prospective, randomized controlled study, SSB was as effective as ISB for mean pain control within the first 24 hours but ISB was more effective in relieving pain in the recovery room after arthroscopic supraspinatus and/or infraspinatus tendon repair.

Randomized Controlled Trial

Anterior Suprascapular Nerve Block Versus Interscalene Brachial Plexus Block for Shoulder Surgery in the Outpatient Setting: A Randomized Controlled Patient- and Assessor-Blinded Trial

Martin Wiegel et al. Reg Anesth Pain Med. May/Jun 2017.

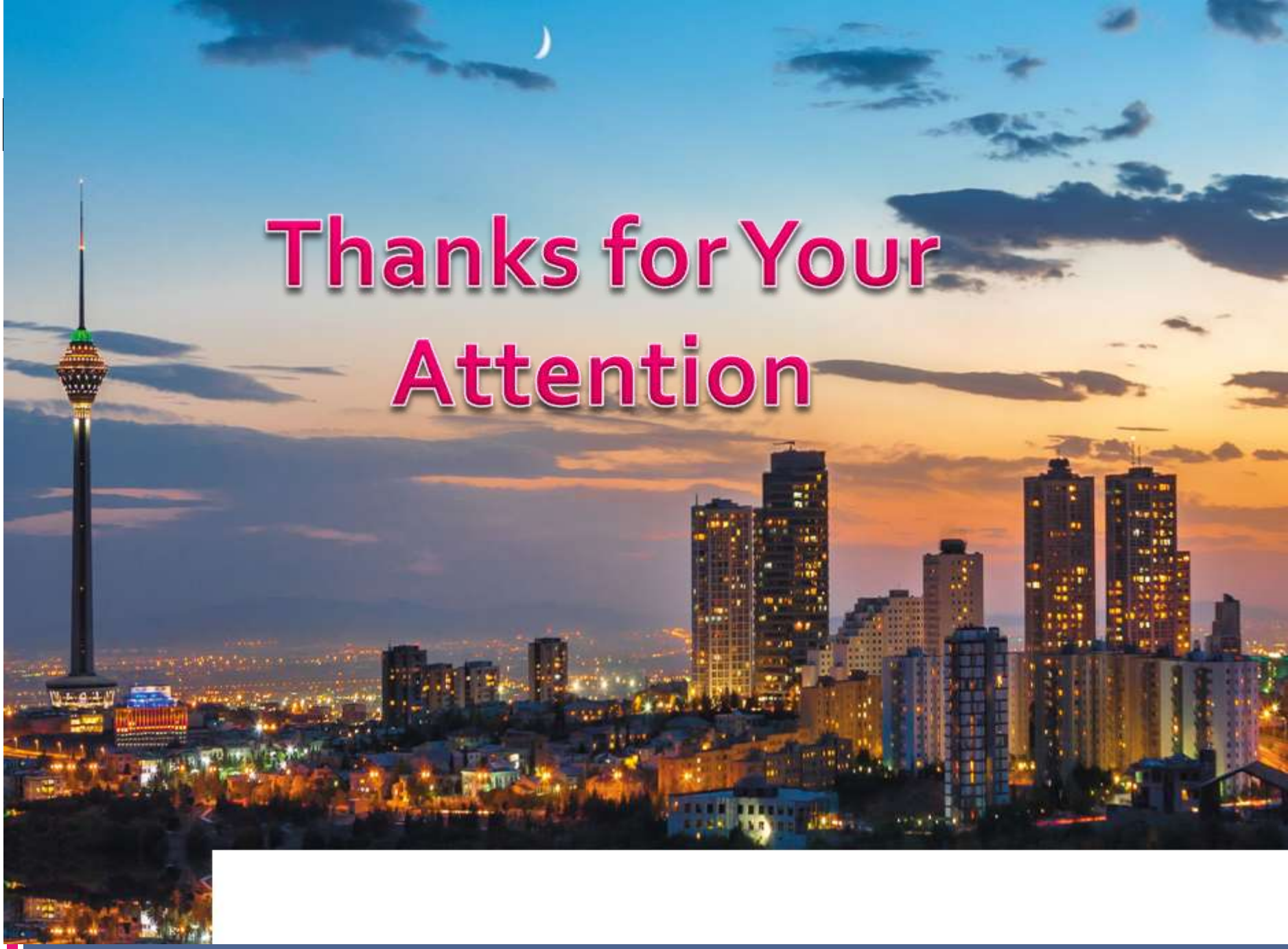
Thanks for Your
Attention